

## Treatment Strategy for Recurrent and Refractory Epithelial Ovarian Cancer: Efficacy of High-Dose Chemotherapy with Hematopoietic Stem Cell Transplantation

Toshinari Muramatsu<sup>1</sup>, Takao Shinozuka<sup>3</sup>, Takeshi Hirasawa<sup>1</sup>, Hitomi Tsukada<sup>1</sup>, Hironobu Maeda<sup>1</sup>, Tsuyoshi Miyamoto<sup>1</sup>, Masaru Murakami<sup>1</sup>, Hiroshi Kajiwara<sup>2</sup>, Masanori Yasuda<sup>2</sup>, R. Yoshiyuki Osamura<sup>2</sup> and Mikio Mikami<sup>1</sup>

<sup>1</sup>Department of Obstetrics and Gynecology and <sup>2</sup>Department of Pathology, Tokai University School of Medicine, Shimokasuya 143, Isehara, Kanagawa 259–1143, Japan, and <sup>3</sup>Department of Gynecology, Ayase Kosei Hospital, Fukaya 3815, Ayase, Kanagawa, Japan

Received May 10, 2005; accepted April 3, 2006; published online May 26, 2006

According to population statistics in Japan, approximately 3,800 women die of ovarian cancer annually, and approximately 6,000 are affected by this disease. Ovarian cancer is referred to as a “silent tumor”, since patients have few subjective symptoms and by the time symptoms are observed, the cancer has progressed to Stage III or IV in about half of the patients. The basic treatment for advanced epithelial ovarian cancer is to remove as much of the tumor as possible, and subsequently to perform anticancer therapy using drugs such as cisplatin, carboplatin and paclitaxel, all of which have been shown to be effective for epithelial ovarian cancer. However, the 5-year survival rate in advanced ovarian cancer patients is still only about 20%, and a treatment that leads to long-term survival has yet to be developed. Here, we review the available treatments for ovarian cancer, and present the results of high-dose chemotherapy (HDC) performed in our hospital for recurrent and refractory ovarian cancer.

**Key words:** recurrent/refractory ovarian cancer, high-dose chemotherapy, hematopoietic stem cell transplantation, treatment

### I. Introduction

Between 1984 and 1995, high-dose chemotherapy (HDC) based mainly on platinum compounds (cisplatin and carboplatin) with autologous bone marrow transplantation or peripheral blood stem cell transplantation were performed with the goal of achieving long-term survival in patients with advanced and refractory epithelial ovarian cancer [27, 28, 37, 38]. This approach was taken based on the results of *in vitro* studies [2, 3], in which a higher dose of platinum compounds was shown to be likely to kill more ovarian cancer cells [15, 20, 30]. However, subsequent studies suggested that the dose of platinum compounds is not necessarily correlated with treatment effects, including a randomized

study performed in 1995 by the Gynecologic Oncology Group (GOG) in the U.S. in patients with ovarian cancer at Stage III and IV. In this study, Group A received 8 courses of 50 mg/m<sup>2</sup> cisplatin (CDDP) and 500 mg/m<sup>2</sup> cyclophosphamide (CPM), and Group B received 4 courses of 100 mg/m<sup>2</sup> CDDP and 1000 mg/m<sup>2</sup> CPM; therefore, the total doses of the two groups were the same. In groups A and B, respectively, the response rates were 60% and 55%, the 4-year survival rates were 20% and 20%, the mean survival times were 19.5 and 21.3 months, and the mean progression-free survival times were 12.1 and 14.3 months. Since there were no significant differences between the patients in the two groups, these results indicate that the dose intensity is not correlated with chemotherapeutic effects [21]. Similar results have been obtained in subsequent randomized studies [8, 14, 16], and it is now generally thought that doubling the recommended dose does not improve chemotherapeutic effects in a multi-drug regimen including platinum compounds.

Correspondence to: Toshinari Muramatsu, M.D., Department of Obstetrics and Gynecology, Tokai University School of Medicine, Shimokasuya 143, Isehara, Kanagawa 259–1143, Japan.  
E-mail: mura-to@is.icc.u-tokai.ac.jp

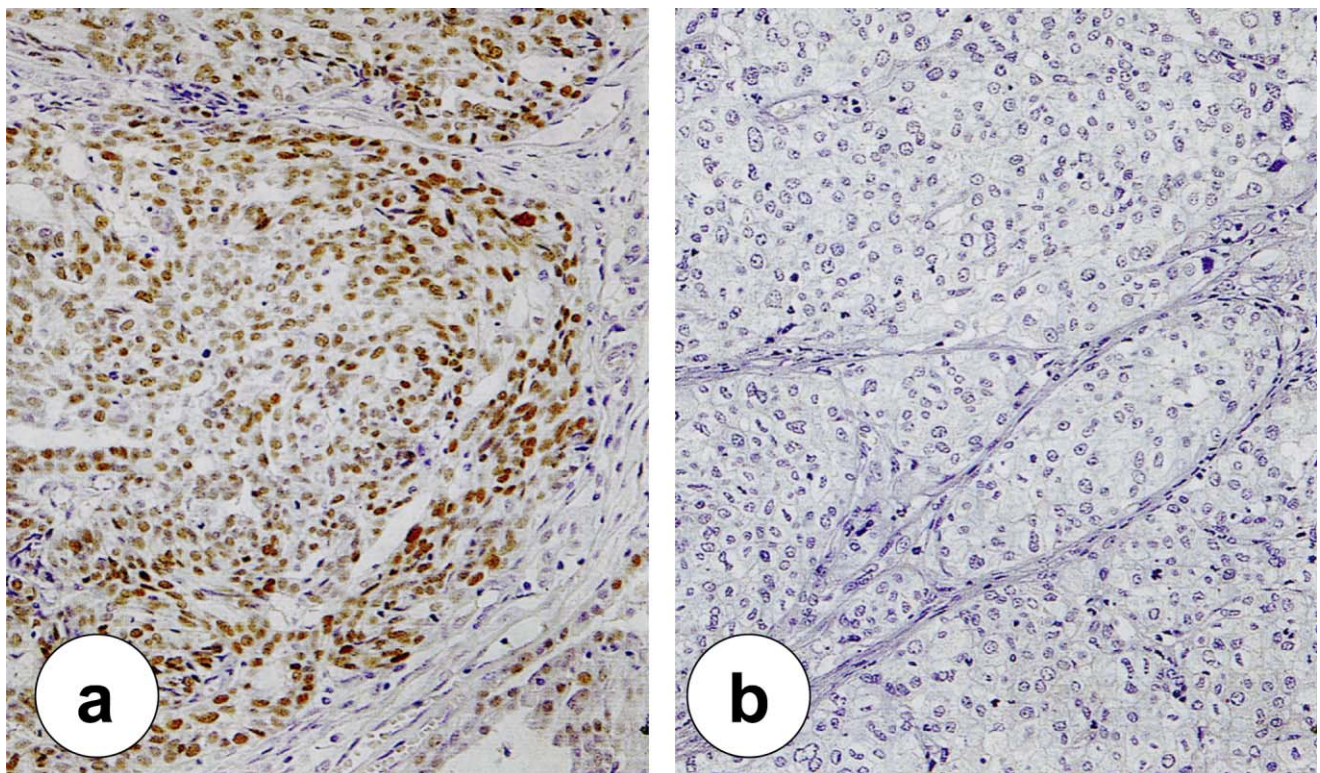
## II. Combination Chemotherapy with Hematopoietic Stem Cell Transplantation for Advanced Epithelial Ovarian Cancer

More than 15 years have passed since the introduction of HDC for advanced epithelial ovarian cancer, and HDC is now performed more safely and effectively due to hematopoietic stem cell support [24]. Therefore, it has become possible to increase the dose intensity in HDC compared with doses used in conventional chemotherapy, leading to expectations of improved progression-free survival (PFS) and overall survival (OS) [5, 12, 19, 25, 26, 39–42]. However, the results of randomized studies comparing HDC with conventional chemotherapy show that the complete remission period is short and the long-term survival rate is only 10–20% in HDC, although an apparent high responsiveness and high response rate are observed at the beginning of treatment [5, 25, 26, 39, 41]. The conventional regimen in HDC is mainly based on platinum compounds: combined treatment of 100–150 mg/m<sup>2</sup> CDDP and 800–1600 mg/m<sup>2</sup> CBDCA (fundamental agents) with CPM, etoposide and thiotepa is generally performed.

We initially performed a pilot study to observe long-term prognosis in 105 patients with advanced and recurrent ovarian cancer, using 1–2 courses of 100–150 mg/m<sup>2</sup> CDDP, 100 mg/m<sup>2</sup> adriamycin (ADM) and 1600–2400 mg/m<sup>2</sup> CPM; or 900–1600 mg/m<sup>2</sup> CBDCA and 1500–3000 mg/m<sup>2</sup> CPM. In this study, the respective 5-year PFS and OS rates were

35.7% and 58.1% in Stage III patients, 22.6% and 33.7% in Stage IV patients, and 31.0% and 37.5% in recurrent patients. Furthermore, among 65 Stage III and IV patients, the respective rates of PFS and OS were 51.5% and 74.3% in patients with a residual tumor diameter of not more than 5 mm, 0% and 30.8% in patients with a diameter of 5 mm to 20 mm, and 16.7% and 22.6% in patients with a tumor diameter of not less than 20 mm [37].

We recently showed that immunohistochemical expression of mutant p53 protein is decreased by HDC in ovarian cancer tissues, and that the level of p53 immuno-expression is related to the chemotherapeutic effect (Figs. 1, 2) [11]. The p53 tumor suppressor gene is closely associated with DNA repair and apoptosis, and mutant p53 accumulates in tumor cells of advanced refractory ovarian cancer, causing the cells to proliferate. In cancer cells sensitive to platinum-based chemotherapy, wild-type p53 induces apoptosis and repair of damaged DNA, whereas chemotherapy-resistant cancer cells include a mutant p53 that cannot induce apoptosis of cancer cells and does not inhibit cancer cell growth [36]. In advanced refractory ovarian cancer treated with platinum-based HDC, most p53 protein-positive tumor cells underwent apoptosis, and p53 expression was suppressed in one tumor that recurred after HDC and was removed in a second reduction surgery [36]. In contrast, p53 protein-positive tumor cell growth was not suppressed in conventional chemotherapy (CONV) using a normal dose of cisplatin, and high p53 expression was found in a tumor that recurred after



**Fig. 1.** HDC in a case of ovarian endometrioid adenocarcinoma. Mutant p53 immuno-expression was observed before HDC (a) but not after HDC (b) (×50).



CONV and was removed in a second reduction surgery [36].

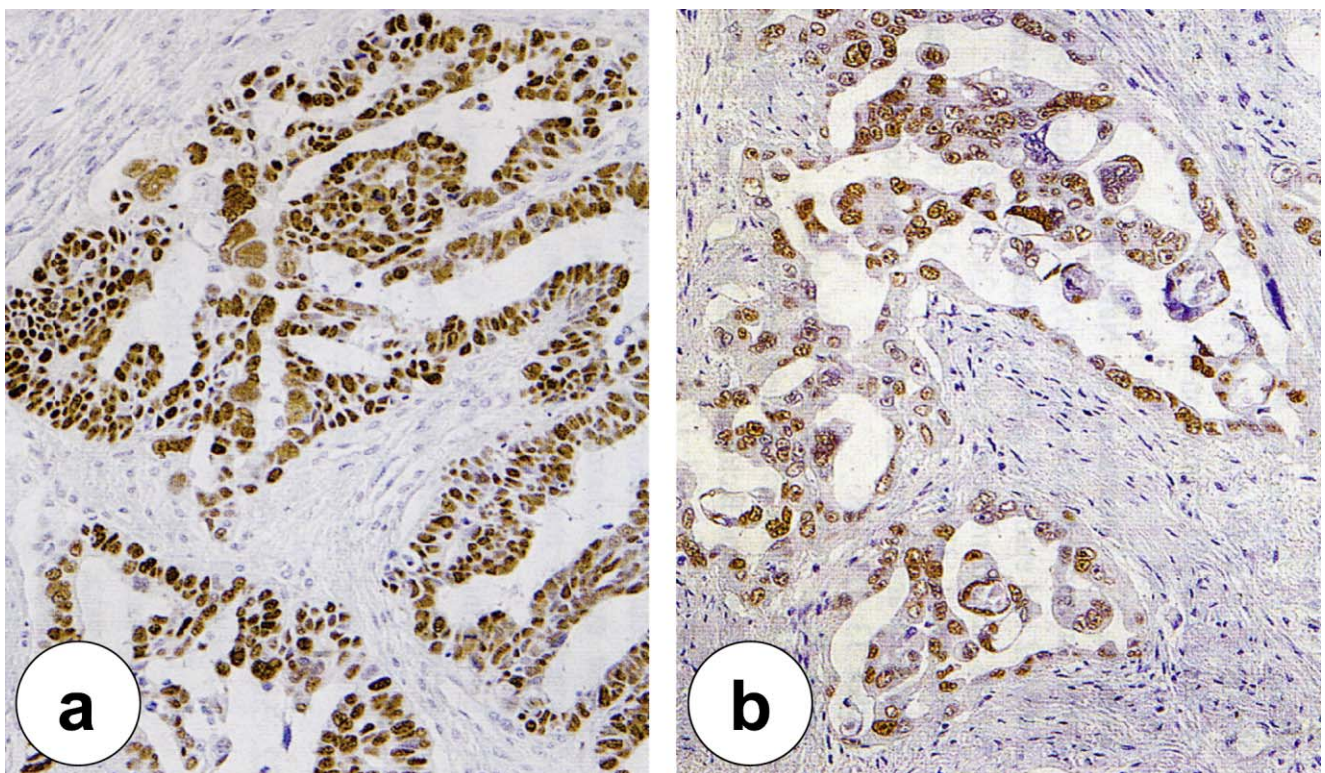
Legros *et al.* performed a pilot HDC study using melphalan ( $140 \text{ mg/m}^2$ ), or CBDCA ( $400 \text{ mg/m}^2$  on Days 1–4) and CPM ( $1600 \text{ mg/m}^2$  on Days 1–4) in 53 Stage III and IV patients, and found 5-year PFC and OS rates of 23.6% and 59.9%, respectively [19]. Of particular importance, a complete pathological response was confirmed in a second-look operation in 19 of 24 survivors. Furthermore, Ledermann *et al.* (in the European group study) reported that the median OS is 59 months in Stage III patients and 40 months in Stage IV after HDC [18]. All these results indicate a favorable long-term prognosis following use of HDC, compared with conventional chemotherapy.

### III. Use of HDC for Recurrent and Refractory Ovarian Cancer at Tokai University Hospital

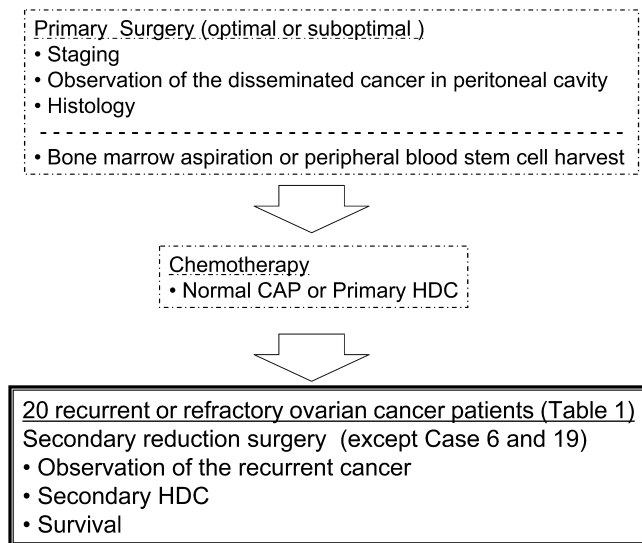
HDC combined with autologous stem cell transplantation has been performed for advanced epithelial ovarian cancer at our hospital since 1984 [27, 28, 37, 38]. Here, we present a retrospective study of the long-term effects of HDC in patients with recurrent and refractory ovarian cancer who were treated until 1996. The subjects were 20 epithelial ovarian cancer patients in whom the lesion disappeared and remission was attained at initial treatment but recurrence was then observed, in whom a poor response occurred and tumor markers did not become negative after initial treatment, who showed positive laparoscopic findings after ini-

tial treatment, or who had no response to initial treatment and are refractory to HDC. In 18 of these 20 patients, we performed a second-look operation before HDC to observe the level of recurrence in the abdominal cavity, and conducted tumor reduction surgery (Fig. 3, Table 1). Six of the 20 patients have survived and 14 have died; the Kaplan-Meier survival curve is shown in Figure 4. In 9 patients, tumor reduction surgery resulted in the remaining tumor having a diameter of not more than 5 mm before HDC, and 5 of these 9 patients showed long-term survival. In contrast, in 6 patients the residual tumor diameter was 20 mm or greater, and all of these patients died from 4 to 32 months after HDC treatment (mean survival period: 16 months). These data were partly the basis of the significant difference ( $p < 0.05$ ) in the survival curves of patients with a residual tumor diameter of 5 mm or greater ( $n = 11$ ) and those with a residual diameter of less than 5 mm ( $n = 9$ ) (Fig. 4).

A significant difference ( $p = 0.0238$ ) was found in the platinum-free interval (PFI) (duration from previous HDC to second HDC) between the 6 surviving patients (range: 26–44 months, mean: 35.5 months) and the 14 patients who died (range: 4–48 months, mean: 20.1 months) (Fig. 5). Also, the 13 recurrent patients who initially showed remission had a higher survival rate (a 5-year survival rate of 53.8%) compared to the 7 refractory cases (a 3-year survival rate of 14.3%) (Table 2). Concerning the histology of the ovarian cancer, 6 of the 7 refractory cases had clear cell carcinoma or mucinous adenocarcinoma.



**Fig. 2.** Conventional chemotherapy (CONV) in a case of ovarian serous adenocarcinoma. No significant mutant p53 expression was observed before CONV (a) and after CONV (b) ( $\times 50$ ).



**Fig. 3.** Normal and/or high dose chemotherapy in patients with advanced ovarian cancer.

After administration of a HDC regimen of 2400 mg/m<sup>2</sup> CPM, 100 mg/m<sup>2</sup> ADM and 150 mg/m<sup>2</sup> CDDP, autologous bone marrow transplantation was performed. In our supportive care protocol, patients with hemoglobin <8.0 g/dl or platelet levels <2.0×10<sup>4</sup>/μl were indicated for transfusions of 15Gy-irradiated red blood cells or platelets, respectively. If the patients became febrile, broad-spectrum antibiotics were administered. Intravenous administration of G-CSF continued until confirmation of bone marrow recovery to 1.0×10<sup>4</sup>/μl white blood cells. Peripheral leukocyte count was continuously less than 100/μl for 4 days, and 17 days were required for neutrophils to recover to at least 1500/μl and 13 days for platelets to reach at least 50,000/μl (Table 3). Fever (not less than 38°C) accompanied by leucopenia was observed for a mean period of 2.5 days. Overall, the results indicated that removal of as much as possible of the tumor is favorable (if possible, the residual tumor diameter should be less than 5 mm) for attainment of high treatment efficacy in HDC for recurrent and refractory ovarian cancer as a second-line chemotherapy. In addition, a long PFI from the previous treatment may be beneficial.

**Table 1.** Characteristics of 20 recurrent and refractory epithelial ovarian cancer patients with HDC who were treated at Tokai University Hospital

Case	Age	Primary surgery		Secondary surgery	2nd HDC-regimen	No. of courses	Survival time [months]
		stage	histology	residual tumor (mm)			
1.	56	IV	S	Micro	CAP	1	57
2.	45	IIIb	S	Micro	CAP	2	140
3.	29	Ia	M	>20	CAP	2	4 <sup>†</sup>
4.	47	IIIc	S	≤20	CAP	2	21 <sup>†</sup>
5.	48	IIIc	S	>20	CAP	2	32 <sup>†</sup>
6.	56	IIIc	M	—	CAP	2	156 <sup>†</sup>
7.	49	IIIc	S	>20	CAP	2	17 <sup>†</sup>
8.	45	Ic	C	>20	CAP+VP16	2	12 <sup>†</sup>
9.	52	IIIc	E	Micro	CBDCA+CPM*	1	60
10.	46	IIIb	E	Micro	CBDCA+CPM*	1	79
11.	43	IIIb	S	≤20	CBDCA+CPM*	1	79
12.	63	IIIb	S	Micro	CBDCA+CPM*	1	102
13.	52	IIIb	S	Micro	CBDCA+CPM*	1	34 <sup>†</sup>
14.	53	IIIc	S	Micro	CBDCA+CPM*	1	89 <sup>†</sup>
15.	37	IIc	C	≤20	CBDCA+CPM*	2	22 <sup>†</sup>
16.	38	Ia	M	5	CBDCA+CPM*	2	12 <sup>†</sup>
17.	50	IIIc	S	5	CBDCA#+VP16	1	17 <sup>†</sup>
18.	63	IV	S	>20	CBDCA#+VP16	1	25 <sup>†</sup>
19.	42	Ic	C	—	CBDCA#+VP16	2	27 <sup>†</sup>
20.	41	Ic	S	>20	CBDCA+VP16+Tes	1	6 <sup>†</sup>

S: serous, M: mucinous, C: clear cell, E: endometrioid.

CAP: cyclophosphamide (CPM) 500–2400 mg/m<sup>2</sup>+adriamycin 50–100 mg/m<sup>2</sup>+cisplatin 100–150 mg/m<sup>2</sup>. VP16: 600–900 mg/m<sup>2</sup>, carboplatin (CBDCA): 750–1500 mg/m<sup>2</sup>, CPM\*: 1500–3000 mg/m<sup>2</sup>, CBDCA#: 600–750 mg/m<sup>2</sup>, Tes: tespamin 600 mg/m<sup>2</sup>, †: dead patients, —: non secondary surgery.

**Table 2.** Survival after HDC in recurrent and refractory ovarian cancer patients

	No. of survivors (survival %) after HDC			
	1	3	5	7 (year)
Recurrent patients (n=13)	13 (100)	10 (76.9)	7 (53.8)	7 (53.8)
Refractory patients (n=7)	3 (42.9)	1 (14.3)	1 (14.3)	1 (14.3)

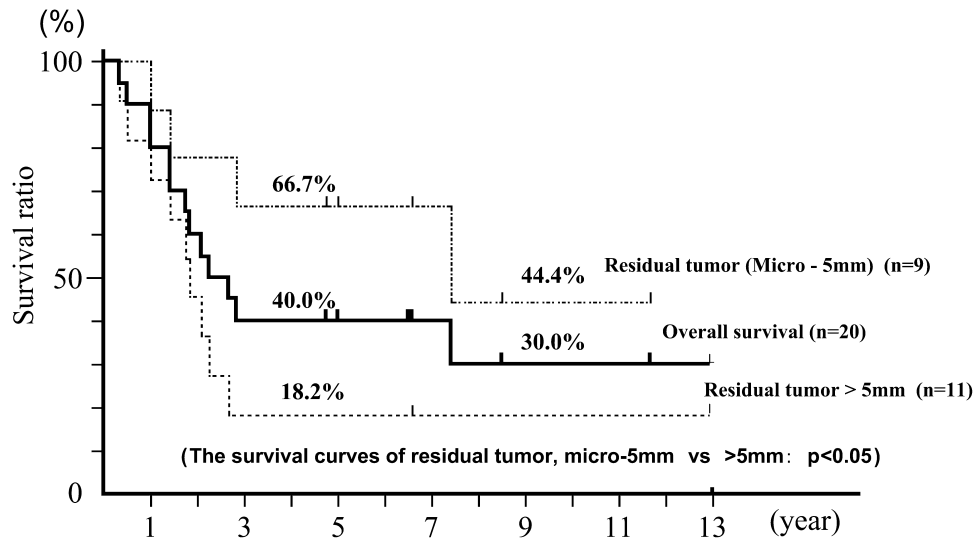


Fig. 4. Correlation between survival and residual tumor size.

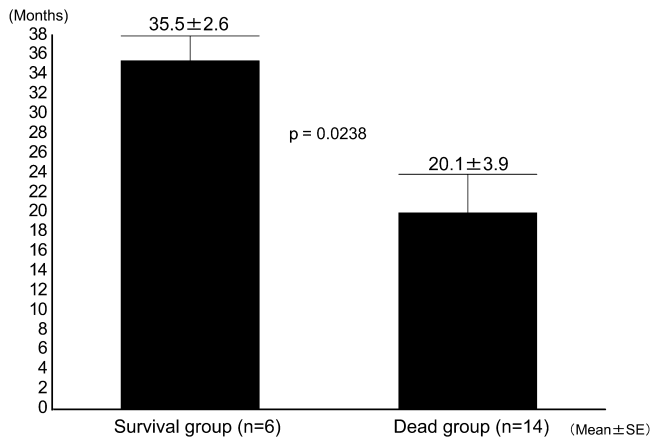


Fig. 5. Correlation between survival and platinum-free interval.

#### IV. New Treatment Strategy

The history of chemotherapy for ovarian cancer includes the introduction of a platinum compound (cisplatin, CDDP) in 1970, and since then treatment based mainly on this compound has been thought to be most effective [13, 17]. However, nephrotoxicity and peripheral nerve disorder are dose-limiting factors in cisplatin therapy, and severe visual disturbance may also occur [29], thereby requiring careful attention to side effects with use of cisplatin. Carboplatin (CBDCA), a second-generation platinum compound, was subsequently developed; the anti-tumor effect of CBDCA is almost equal to that of CDDP [1, 7], and the potency of CBDCA is 4 times lower than that of CDDP [32]. Furthermore, unlike CDDP, CBDCA induces only very mild nephrotoxicity and peripheral nerve disorder, and its limiting side effect of bone marrow suppression can be alleviated by reducing the dose according to the degree of renal dysfunction in individual patients [6].

In the late 1980s, drug tolerance toward platinum com-

Table 3. Days required for recovery of peripheral blood count after HDC<sup>a</sup> in 20 recurrent and refractory ovarian cancer patients

	Median days (range)
Leukocyte count under 100/ $\mu$ l	4 (0–9)
Neutrophil count over 500/ $\mu$ l	13.5 <sup>b</sup> (10–19)
Neutrophil count over 1,500/ $\mu$ l	17 <sup>b</sup> (11–46)
Platelet count over 50,000/ $\mu$ l	13 <sup>b</sup> (0–21)
Neutropenic fever up over 38°C	2.5 (0–7)

<sup>a</sup> HDC regimen: cyclophosphamide 2400 mg/m<sup>2</sup>+adriamycin 100 mg/m<sup>2</sup>+cisplatin 150 mg/m<sup>2</sup>.

<sup>b</sup> Days after autologous bone marrow transplantation.

pounds was identified as a significant prognostic factor, and expectations were placed on discovery of new anticancer agents. Among these, paclitaxel (PTX) was shown to have no cross-tolerance with platinum compounds, suggesting that it could be a new agent for treatment of ovarian cancer. PTX was approved in the US and Europe in 1992, and the optimal dose of PTX has subsequently been investigated [4, 10, 23]. Many clinical studies based mainly on PTX have been conducted [22, 33–35], and combination chemotherapy of PTX and CBDCA is now common as the “gold standard” for epithelial ovarian cancer treatment. In Japan, the decision to allow coverage of PTX in the health insurance system from December 1997 has allowed the drug to be used for general treatment of ovarian cancer patients.

In 2004, Japan Society of Gynecologic Oncology issued Ovarian Cancer Treatment Guidelines [31]. The main purposes of these guidelines are to define appropriate treatments for ovarian cancer, to reduce the differences in treatments levels among facilities, and to establish safer and more effective treatments. Combination therapy of PTX and CBDCA may be the optimal regimen for chemotherapy based on the results of many previous studies [9, 22, 33–35];

however, when administration of 175–180 mg/m<sup>2</sup> PTX and AUC5-6 CBDCA was started (every 21–28 days, 6–9 courses) in our facility, approximately 30% of the patients showed strong bone marrow suppression. The decreases of leukocytes and platelets by 2–3 grades sometimes persisted, requiring reduction of the doses of PTX and carboplatin, and consequently decreasing treatment efficacy and quality in some cases. In this context, it is important to note that most data cited in the guidelines [31] were obtained in European and American patients. In particular, optimal doses for Japanese women have not been determined and no recommended treatment has been established for recurrent refractory ovarian cancer, although anticancer agents for salvage chemotherapy are listed in the guidelines. Therefore, we suggest that further randomized studies of treatment for recurrent ovarian cancer be conducted.

## V. References

1. Aabo, K., Adams, M., Adnitt, P., Alberts, D. S., Athanazziou, A., Barley, V., Bell, D. R., Bianchi, U., Bolis, G., Brady, M. F., Brodovsky, H. S., Bruckner, H., Buyse, M., Canetta, R., Chylak, V., Cohen, C. J., Colombo, N., Conte, P. F., Crowther, D., Edmonson, J. H., Gennatas, C., Gilbey, E., Gore, M., Guthrie, D., Kaye, S. B., Laing, A. H., Landoni, F., Leonard, R. C., Lewis, C., Liu, P. Y., Mngangioni, C., Marsoni, S., Meerpohl, H., Omura, G. A., Parmar, M. K. B., Pater, J., Pecorelli, S., Presti, M., Sauerbrei, W., Skarlos, D. V., Smalley, R. V., Solomon, H. J., Stewart, L. A., Sturgeon, J. F. G., Tattersall, M. H. N., Wharton, J. T., ten Bokkel Huinink, W. W., Tomirotti, M., Torri, W., Trope, C., Tubow, M. M., Vermorken, J. B., Webb, M. J., Wilbur, D. W., Williams, C. J., Wiltshaw, E. and Yeap, B. Y. (1998) Chemotherapy in advanced ovarian cancer: four systematic meta-analyses of individual patient data from 37 randomized trials. Advanced Ovarian Cancer Trialists' Group. *Br. J. Cancer* 78; 1479–1487.
2. Alberts, D. S., Young, L., Mason, N. and Salmon, S. E. (1985) In vitro evaluation of anticancer drugs against ovarian cancer at concentrations achievable by intraperitoneal administration. *Semin. Oncol.* 12; 38–42.
3. Andrews, P. A., Velury, S., Mann, S. C. and Howell, S. B. (1988) cis-Diamminedichloroplatinum (II) accumulation in sensitive and resistant ovarian carcinoma cells. *Cancer Res.* 48; 68–73.
4. Balat, O., Kudelka, A. P., Tunca, J. C., Edwards, C. L., Verschraegen, C. and Kavanagh, J. J. (1996) Prolonged stabilization of progressive platinum-refractory ovarian cancer with paclitaxel: brief report. *Eur. J. Gynaecol. Oncol.* 17; 264–266.
5. Broun, E. R., Belinson, J. L., Berek, J. S., Berek, J. S., McIntosh, D., Hurd, D., Ball, H. and Williams, S. (1994) Salvage therapy for recurrent or refractory ovarian cancer with high-dose chemotherapy and autologous bone marrow support: a Gynecologic Oncology Group pilot study. *Gynecol. Oncol.* 54; 142–146.
6. Calvert, A. H., Newell, D. R., Gumbrell, L. A., O'Reilly, S., Burnell, M., Boxall, F. E., Siddik, Z. H., Judson, I. R., Gore, M. E. and Wiltshaw, E. (1989) Carboplatin dosage: prospective evaluation of a simple formula based on renal function. *J. Clin. Oncol.* 7; 1748–1756.
7. Conte, P. F., Bruzzone, M., Carnino, F., Chiara, S., Donadio, M., Facchini, V., Fioretti, P., Foglia, G., Gadducci, A., Gallo, L., Giaccone, G., Guercio, E., Iskra, L., Janssen, N., Maresi, M. P., Parodi, G., Ragni, N., Rosso, R., Rubagotti, A., Rugiati, S., Storace, A., Venturini, S. and Pescetto, G. (1991) Carboplatin, doxorubicin, and cyclophosphamide versus cisplatin, doxorubicin, and cyclophosphamide: a randomized trial in stage III-IV epithelial ovarian carcinoma. *J. Clin. Oncol.* 9; 658–663.
8. Conte, P. F., Bruzzone, M., Carnino, F., Gadducci, A., Algeri, R., Bellini, A., Boccardo, F., Brunetti, I., Catsafados, E., Chiara, S., Folia, G., Gallo, L., Iskra, L., Mammoliti, S., Parodi, G., Ragni, N., Rosso, R., Rugiati, S. and Rubagotti, A. (1996) High-dose vs low-dose cisplatin in combination with cyclophosphamide and epidoxorubicin in suboptimal ovarian cancer: a randomized study of Gruppo Oncologico Nord-Ovest. *J. Clin. Oncol.* 14; 351–356.
9. du Bois, A., Luck, H. J., Meier, W., Adams, H. P., Mobus, V., Costa, S., Bauknecht, T., Richter, B., Warm, M., Schroder, W., Olbricht, S., Nitz, U., Jackisch, C., Emons, G., Wagner, U., Kuhn, W. and Pfisterer, J.: Arbeitsgemeinschaft Gynakologische Onkologie Ovarian Cancer Study Group (2003) A randomized clinical trial of cisplatin/paclitaxel versus carboplatin/paclitaxel as first-line treatment of ovarian cancer. *J. Natl. Cancer Inst.* 95; 1320–1329.
10. Einzig, A. I., Wiernik, P. H., Sasloff, J., Runowicz, C. D. and Goldberg, G. L. (1992) Phase II study and long-term follow-up of patients treated with taxol for advanced ovarian carcinoma. *J. Clin. Oncol.* 10; 1748–1753.
11. Hirasawa, T., Yasuda, M., Maeda, H., Muramatsu, T., Miyamoto, T., Murakami, M., Shinozuka, T., Takekoshi, S., Osamura, R. Y. and Makino, T. (2004) Modification of p53 immunoexpression associated with chemotherapy regimens in advanced and refractory ovarian cancers. *Acta Histochem. Cytochem.* 37; 15–20.
12. Holmberg, L. A., Demire, T., Rowley, S., Buckner, C. D., Goodman, G., Maziarz, R., Klamet, J., Zuckerman, N., Harrer, G., McCloskey, R., Gersh, R., Goldberg, R., Nichols, W., Jacobs, A., Weiden, P., Montgomery, P., Rivkin, S., Appelbaum, F. R. and Bensinger, W. I. (1998) High-dose busulfan, melphalan and thiopeta followed by autologous peripheral blood stem cell (PBSC) rescue in patients with advanced stage III/IV ovarian cancer. *Bone Marrow Transplant.* 22; 651–659.
13. Hunter, R. E., Griffin, T. W., Stevens, S., Roman, L. D., Bokhari, F., Reale, F. R., Tak, W. K., Fitzgerald, T. J., Dillon, M. B. and Rose, P. G. (1991) High-dose, short-duration cisplatin/doxorubicin combination chemotherapy for advanced ovarian epithelial cancer. *Cancer* 68; 1890–1894.
14. Jakobsen, A., Bertelsen, K., Andersen, J. E., Havsteen, H., Jakobsen, P., Moeller, K. A., Nielsen, K., Sandberg, E. and Stroejer, I. (1997) Dose-effect study of carboplatin in ovarian cancer: a Danish Ovarian Cancer Group study. *J. Clin. Oncol.* 15; 193–198.
15. Kaye, S. B., Lewis, C. R., Paul, J., Duncan, I. D., Gordon, H. K., Kitchener, H. C., Cruickshank, D. J., Atkinson, R. J., Soukop, M., Rankin, E. M., Cassidy, J., Davis, J. A., Reed, N. S., Crawford, S. M., MacLean, A., Swapp, G. A., Sarkar, T. K. and Kennedy, J. H. (1992) Randomized study of two doses of cisplatin with cyclophosphamide in epithelial ovarian cancer. *Lancet* 340; 329–333.
16. Kaye, S. B., Paul, J., Cassidy, J., Lewis, C. R., Duncan, I. D., Gordon, H. K., Kitchener, H. C., Cruickshank, D. J., Atkinson, R. J., Soukop, M., Rankin, E. M., Davis, J. A., Reed, N. S., Crawford, S. M., MacLean, A., Parkin, D., Sarkar, T. K., Kennedy, J. and Symonds, R. P. (1996) Mature results of randomized trial of two doses of cisplatin for the treatment of ovarian cancer. *J. Clin. Oncol.* 14; 2113–2119.
17. Kehoe, S., Redman, C., Varma, R., Buxton, J., Luesly, D., Blackledge, G. and Stanley, A. (1992) Single agent high-dose cisplatin (200 mg m<sup>-2</sup>) treatment in ovarian carcinoma. *Br. J. Cancer* 66; 717–719.
18. Ledermann, J. A., Herd, R., Maraninchi, D., Viens, P., Buclon, M., Philip, T., Cure, H., Lotz, J. P., Chauvin, F., Ferrante, P. and Rosti, G. (2001) High-dose chemotherapy for ovarian carcinoma: long-term results from the Solid Tumour Registry of the European Group for Blood and Marrow Transplantation (EBMT). *Ann. Oncol.* 12; 693–699.
19. Legros, M., Dauplat, J., Fleury, J., Cure, H., Suzanne, F.,

- Chassagne, J., Bay, J. O., Sol, C., Canis, M., Condat, P., Choufi, B., Tavernier, F., Glenot, C., Chollet, P. and Plagne, R. (1997) High-dose chemotherapy with hematopoietic rescue in patients with stage III to IV ovarian cancer: long-term results. *J. Clin. Oncol.* 15; 1302–1308.
20. Lewin, L., Simon, R. and Hryniuk, W. (1993) Importance of multiagent chemotherapy regimens in ovarian carcinoma: dose-intensity analysis. *J. Natl. Cancer Inst.* 85; 1732–1742.
  21. McGuire, W. P., Hoskins, W. J., Brady, M. F., Homesley, H. D., Creasman, W. T., Berman, M. L., Ball, H., Berek, J. S. and Woodward, J. (1995) Assessment of dose-intensive therapy in suboptimally debulked ovarian cancer: a Gynecologic Oncology Group study. *J. Clin. Oncol.* 13; 1589–1599.
  22. McGuire, W. P., Hoskins, W. J., Brady, M. F., Kucera, P. R., Partridge, E. E., Look, K. Y., Clarke-Pearson, D. L. and Davidson, M. (1996) Cyclophosphamide and cisplatin compared with paclitaxel and cisplatin in patients with stage III and stage IV ovarian cancer. *N. Engl. J. Med.* 334; 1–6.
  23. McGuire, W. P., Hoskins, W. J., Brady, M. F., Kucera, P. R., Partridge, E. E., Look, K. Y., Clarke-Pearson, D. L. and Davidson, M. (1997) Comparison of combination therapy with paclitaxel and cisplatin versus cyclophosphamide and cisplatin in patients with suboptimal stage III and stage IV ovarian cancer: a Gynecologic Oncology Group study. *Semin. Oncol.* 24; s2-13–s2-16.
  24. Miyamoto, T., Shinozuka, T., Maeda, H., Hirasawa, T., Muramatsu, T., Murakami, M., Makino, T., Itagaki, H. and Nakamura, Y. (2004) Effect of peripheral blood progenitor cell dose on hematopoietic recovery: identification of minimal progenitor cell requirements for rapid engraftment. *Bone Marrow Transplant.* 33; 589–595.
  25. Mulder, P. O., Sleijfer, D. T., Willemse, P. H., de Vries, E. G., Uges, D. R. and Mulder, N. H. (1989) High-dose cyclophosphamide or melphalan with escalating doses of mitoxantrone and autologous bone marrow transplantation for refractory solid tumors. *Cancer Res.* 49; 4654–4658.
  26. Mulder, P. O., Willemse, P. H., Aalders, J. G., de Vries, E. G., Sleijfer, D. T., Sibinga, C. T. and Mulder, N. H. (1989) High-dose chemotherapy with autologous bone marrow transplantation in patients with refractory ovarian cancer. *Eur. J. Cancer Clin. Oncol.* 25; 645–649.
  27. Murakami, M., Shinozuka, T., Miyamoto, T., Fujii, A. and Tokuda, Y. (1993) The impact of autologous bone marrow transplantation on hematopoietic recovery after high-dose cyclophosphamide, doxorubicin, and cisplatin chemotherapy for patients with gynecological malignancies. *Asia Oceania J. Obstet. Gynaecol.* 19; 85–93.
  28. Murakami, M., Shinozuka, T., Kuroshima, Y., Tokuda, Y. and Tajima, T. (1994) High-dose chemotherapy with autologous bone marrow transplantation for the treatment of malignant ovarian tumors. *Semin. Oncol.* 21; 29–32.
  29. Muramatsu, T., Shinozuka, T., Hirasawa, T., Maeda, H., Miyamoto, T., Kuroshima, Y., Makino, T. and Tanaka, Y. (1997) A case of recurrent cervical cancer with cortical blindness after chemotherapy with Cis-platinum. *Acta Obst. Gynec. Jpn.* 49; 195–198.
  30. Murphy, D., Crowther, D., Renninson, J., Prendiville, J., Ranson, M., Lind, M., Patel, U., Dougal, M., Buckley, C. H. and Tindall, V. R. (1993) A randomized dose intensity study in ovarian carcinoma comparing chemotherapy given at 4-week intervals for 6 cycles with half dose chemotherapy given for 12 cycles. *Ann. Oncol.* 4; 377–383.
  31. Ovarian Cancer Treatment Guidelines (Version 1) (2004) Japan Society of Gynecological Oncology, Kanehara-Shuppan.
  32. Ozols, R. F. (1992) Chemotherapy for advanced epithelial ovarian cancer. *Hematol. Oncol. Clin. North Am.* 6; 879–894.
  33. Ozols, R. F., Bundy, B. N., Greer, B. E., Fowley, J. M., Clarke-Pearson, D., Burger, R. A., Mannel, R. S., DeGeest, K., Hartenbach, E. M. and Baergen, R. (2003) Phase III trial of carboplatin and paclitaxel compared with cisplatin and paclitaxel in patients with optimally resected stage III ovarian cancer: A Gynecologic Oncology Group Study. *J. Clin. Oncol.* 21; 3194–3200.
  34. Ozols, R. F. (2004) Update on Gynecologic Oncology Group (GOG) trials in ovarian cancer. *Cancer Invest.* 22(Suppl 2); 11–20.
  35. Piccart, M. J., Bertelsen, K., James, K., Cassidy, J., Mangioni, C., Simonsen, E., Stuart, G., Kaye, S., Vergote, I., Blom, R., Grimshaw, R., Atkinson, R. J., Swenerton, K. D., Trope, C., Nardi, M., Kaern, J., Tumolo, S., Timmers, P., Roy, J. A., Lhoas, F., Lindvall, B., Bacon, M., Birt, A., Andersen, J. E., Zee, B., Paul, J., Baron, B. and Pecorelli, S. (2000) Randomized intergroup trial of cisplatin-paclitaxel versus cisplatin-cyclophosphamide in women with advanced epithelial ovarian cancer: three-year results. *J. Natl. Cancer Inst.* 92; 699–708.
  36. Shelling, A. N. (1997) Role of p53 in drug resistance in ovarian cancer. *Lancet* 349; 744–745.
  37. Shinozuka, T., Miyamoto, T., Muramatsu, T., Hirasawa, T., Murakami, M., Makino, T. and Tanaka, Y. (1999) High dose chemotherapy with autologous stem cell support in the treatment of patients with ovarian carcinoma. *Cancer* 85; 1555–1564.
  38. Shinozuka, T., Muramatsu, T., Miyamoto, T., Hirasawa, T., Murakami, M., Makino, T., Sadahiro, S., Tanaka, Y. and Yasuda, M. (1999) Long-term results and prognostic analysis in advanced and recurrent/refractory epithelial ovarian cancer treated by high-dose cyclophosphamide, adriamycin, and cisplatin with autologous bone marrow transplantation. *Int. J. Clin. Oncol.* 4; 273–279.
  39. Shpall, E. J., Clarke-Pearson, D., Soper, J. T., Berchuck, A., Jones, R. B., Bast, R. C., Ross, J. M., Lidor, Y., Vanacker, K., Tyler, T. and Peters, W. P. (1990) High dose alkylating agent chemotherapy with autologous bone marrow support in patients with stage III/IV epithelial ovarian cancer. *Gynecol. Oncol.* 38; 386–391.
  40. Stiff, P., Bayer, R., Camarda, M., Tan, S., Dolan, J., Potkul, R., Loutfi, S., Kinch, L., Sosman, J., Peace, D., Rad, N. and McKenzie, R. S. (1995) A phase II trial of high-dose mitoxantrone, carboplatin, and cyclophosphamide with autologous bone marrow rescue for recurrent epithelial ovarian carcinoma: analysis of risk factors for clinical outcome. *Gynecol. Oncol.* 57; 278–285.
  41. Stiff, P. J., McKenzie, R. S., Alberts, D. S., Sosman, J. A., Dolan, J. R., Rad, N. and McCloskey, T. (1994) Phase I clinical and pharmacokinetic study of high dose mitoxantrone combined with carboplatin, cyclophosphamide and autologous bone marrow rescue: high response rate for refractory ovarian carcinoma. *J. Clin. Oncol.* 12; 176–183.
  42. Stiff, P. J., Bayer, R., Kerger, C., Patkul, R. K., Malhotra, D., Peace, D. J., Smith, D. and Fisher, S. G. (1997) High-dose chemotherapy with autologous transplantation for persistent/relapsed ovarian cancer: a multivariate analysis of survival for 100 consecutively treated patients. *J. Clin. Oncol.* 15; 1309–1317.