

**Case
Report**

Distal Aortic Arch Aneurysm Associated with Persistent Fifth Aortic Arch

Takahiro Inoue, MD, Kiyozo Morita, MD, Kei Tanaka, MD, Michio Yoshitake, MD, Hitomi Naruse, MD, Mitsutaka Nakao, MD, and Kazuhiro Hashimoto, MD

Persistent fifth aortic arch (PFAA) associated with interruption of the fourth aortic arch is a rare malformation, usually requiring surgical intervention in childhood. A 51-year-old woman developed a distal aortic arch aneurysm associated with PFAA after patch aortoplasty for coarctation of the aorta at the age of 18. To our knowledge, this is the first reported case of a distal aortic arch aneurysm associated with PFAA. Residual tissues of the ductus and PFAA, which is not a definitive aortic arch, and the implanted synthetic patch may have been related to the development of the aneurysm. Graft interposition between the proximal border of PFAA and the descending aorta was performed because severe adhesions impeded the application of the fourth aortic arch as a proximal anastomotic site of the graft. Accurate diagnosis and sufficient understanding of PFAA allow an appropriate surgical treatment in childhood with a good result over the long term.

Keywords: persistent fifth aortic arch, distal aortic arch aneurysm, coarctation of the aorta

Introduction

It is well known that aneurysms of the distal aortic arch are relatively common due to its anatomical feature. However, a distal aortic arch aneurysm associated with congenital malformation of the aortic arch is rare. We report a 51-year-old woman with a distal aortic arch aneurysm complicated by persistent fifth aortic arch (PFAA), interruption of the fourth aortic arch, coarctation of the aorta. PFAA is a little-known anomaly. In this patient, misdiagnosis of PFAA led to the performance of an unfavorable surgical procedure in childhood.

Department of Cardiac Surgery, The Jikei University, Minato-ku, Tokyo, Japan

Received: February 25, 2013; Accepted: May 8, 2013
Corresponding author: Takahiro Inoue, MD. Department of Cardiac Surgery, The Jikei University, 3-25-8 Nishishinbashi, Minato-ku, Tokyo 105-8461, Japan
Email: yokosuka-inoten@jikei.ac.jp
©2014 The Editorial Committee of *Annals of Thoracic and Cardiovascular Surgery*. All rights reserved.

Case Report

A 51-year-old woman had a history of patch aortoplasty for coarctation of the aorta at our hospital at the age of 18. According to the past operative record, the ductus ligamentum originated from the proximal part of long-segment coarctation, and a 20 × 35 mm spindle-shaped woven Dacron patch was used to enlarge the narrow segment. After the repair, her general condition was stable. Oral medication to treat hypertension had been initiated at the age of 17. When a health check was done at the age of 50, a distal aortic arch aneurysm was detected on her chest X-ray film and confirmed by computed tomography (CT). At presentation, the patient was asymptomatic. The blood pressure was 135/64 mmHg in the right arm and 83/56 mmHg in the right leg. Preoperative three-dimensional CT (3D-CT) confirmed the diagnosis of a distal aortic arch aneurysm associated with PFAA (the fifth aortic arch normally regresses completely in early embryonic life), interruption of the fourth aortic arch (type A according to the Celoria-Patton

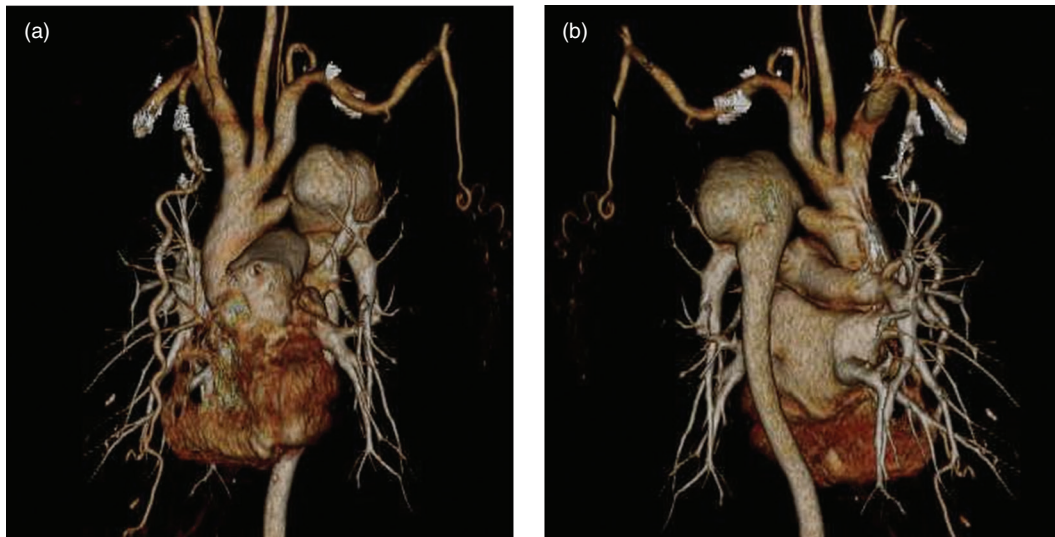


Fig. 1 (a) Anterior preoperative three-dimensional computed tomography (3D-CT). The cervical vessels and the fifth aortic arch branch separately from the ascending aorta. The stenotic lesion in the fifth part of the aortic arch is located just proximal to the aneurysm. (b) Posterior preoperative 3D-CT. The saccular aneurysm of distal aortic arch reaches 55 mm in greatest diameter.

classification), and coarctation of the aorta (**Fig. 1a** and **1b**). The proximal portion of PFAA was relatively narrow. An aneurysm that was 55 mm in diameter arose in the vicinity of the old aortic patch. No intracardiac lesion was detected by echocardiography.

Surgical repair was performed via left posterolateral thoracotomy in the fourth intercostal space. Cardiopulmonary bypass was established by cannulation of the right brachial artery and the left femoral artery with drainage from the right atrium. A venting tube was inserted from the main pulmonary artery and the patient was cooled at 20°C. After clamping the descending aorta and discontinuing flow from the right brachial artery, the aneurysm was dissected. The patch was found to be included in the aneurysm. The ductus ligamentum gave rise to the proximal part of the aneurysm, so it was divided. The fragile tissue of the proximal fifth part of the aortic arch was removed as completely as possible. A 16-mm knitted Dacron graft was interposed between the proximal border of PFAA and the descending aorta.

Her postoperative course was uneventful without cerebral complications. Postoperative 3D-CT demonstrated good reconstruction of the aortic arch with mild stenosis of the proximal anastomosis (**Fig. 2**). Blood pressure was 122/67 mmHg in the right arm and 128/70 mmHg in the right leg. Histological examination of the aneurysm showed severe hyperplastic intima, thinning of the media, and

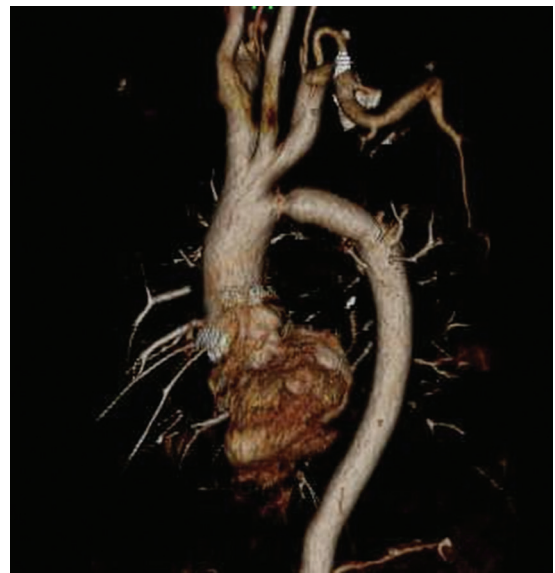


Fig. 2 Postoperative three-dimensional computed tomography (3D-CT). The graft is anastomosed to proximal border of the fifth aortic arch, which is not a definitive arch. Although proximal site of the graft anastomosis is slightly stenotic, there is no significant difference in blood pressure between the upper and lower extremities.

adherence of the adventitia to the pleura and the lung with partial disruption of these three layers of the aortic wall.

Discussion

PFAA, that was first reported by Van Praagh in 1969,¹⁾ is an unusual arch malformation and its association with interruption of the fourth aortic arch and coarctation of the fifth aortic arch has occasionally been described. PFAA is usually associated with other congenital cardiac anomalies, such as ventricular septal defect, aortic arch atresia, coarctation of the aorta, pulmonary atresia, or tricuspid atresia. Thus, it usually requires surgical intervention in childhood. There are only two reported cases of PFAA with no symptom before adulthood,^{2,3)} and to our knowledge, this is the first reported adult case of PFAA with a distal aortic arch aneurysm. In this patient, it is extremely unusual that no surgical intervention was required until the age of 18 although she had coarctation of the aorta, while a definitive diagnosis of PFAA was not made until after detection of the distal aortic arch aneurysm at the age of 51.

PFAA is classified into three types⁴⁾: Type A is “double-lumen aortic arch with both lumina patent”, Type B is “atresia or interruption of the superior arch with a patent inferior arch”, and Type C is “systemic-to-pulmonary arterial connection atresia and absent arterial duct”. The timing of the clinical presentation and diagnosis of PFAA are strongly affected by associated cardiac anomalies. Type C is often detected in childhood due to severe defects of the right ventricular outflow tract or pulmonary artery.^{5,6)} On the other hand, types A and B are hemodynamically stable or occasionally asymptomatic because of relatively few significant cardiac anomalies.^{2,3)} This patient had type B PFAA and did not require surgical intervention until she was 18 years old because her coarctation was mild.

There have been some reports of surgical treatment in which the fifth aortic arch is employed as the final arch. In the present case, however, residual tissues of the ductus at the site of coarctation repair and persistence of the fifth aortic arch, which is not a definitive aortic arch, and patch material at the primary repair are considered to be related to the development of a distal aortic arch aneurysm.⁷⁾ Synthetic patch angioplasty for repair of coarctation of the aorta can produce compliance mismatch between patch material and the native aortic wall tissue, leading to turbulent flow in the area of patch angioplasty.⁸⁾ In this patient, the aneurysm arose from the aorta adjacent to the implanted synthetic patch and ultimately involved it. Appropriate surgical treatment for PFAA in childhood may be complete excision of the ductal tissue

and incorporation of the fourth aortic arch, which forms a definitive arch, without using the synthetic material. We had scheduled graft interposition between the fourth aortic arch and the descending aorta or between the ascending and descending aorta. However, we abandoned these options due to severe adhesions between the aneurysm and the surrounding structures as well as concern about the effect of a prolonged circulatory arrest on the brain. Careful long-term follow-up is mandatory due to the possibility of stenotic or aneurysmal change in the residual tissue when the fifth aortic arch is used as the proximal site for graft anastomosis. At the present time, although mild stenosis of the proximal anastomosis is found on 3D-CT, there is no significant difference in blood pressure between the upper and lower extremities.

Gerlis, et al. demonstrated that the rate of incidence of PFAA was 0.3% in specimens.⁹⁾ However, PFAA is a little-known malformation, so its misdiagnosis is frequent, and the actual incidence is unclear. Although a difference in blood pressure between the upper and lower extremities is most commonly due to peripheral arterial disease, the existence of coarctation of the aorta should be considered. PFAA should also be considered in younger persons and those who have few factors predisposing to atherosclerosis, and detailed investigation of the aortic arch is needed.

Conclusion

We report a case of distal aortic arch aneurysm associated with PFAA. To our knowledge, this is the first such case to be reported. Familiarity with PFAA and correct early diagnosis can lead to adoption of an appropriate surgical strategy in childhood with a favorable result over the long term.

Disclosure Statement

The authors declare that they have no conflicts of interest in the manuscript.

References

- 1) Van Praagh R, Van Praagh S. Persistent fifth arterial arch in man. Congenital double-lumen aortic arch. *Am J Cardiol* 1969; **24**: 279-82.
- 2) Geva T, Ray RA, Santini F, et al. Asymptomatic persistent fifth aortic arch (congenital double-lumen aortic arch) in an adult. *Am J Cardiol* 1990; **65**: 1406-7.
- 3) Isomatsu Y, Takanashi Y, Terada M, et al. Persistent

- fifth aortic arch and fourth arch interruption in a 28-year-old woman. *Pediatr Cardiol* 2004; **25**: 696-8.
- 4) Zhao YH, Su ZK, Liu JF, et al. Surgical treatment of persistent fifth aortic arch associated with interrupted aortic arch. *Ann Thorac Surg* 2007; **84**: 1016-9.
 - 5) Yoshii S, Matsukawa T, Hosaka S, et al. Repair of coarctation with persistent fifth arterial arch and atresia of the fourth aortic arch. *J Cardiovasc Surg (Torino)* 1990; **31**: 812-4.
 - 6) Donti A, Soavi N, Sabbatani P, et al. Persistent left fifth aortic arch associated with tetralogy of Fallot. *Pediatr Cardiol* 1997; **18**: 229-31.
 - 7) Atsumi N, Moriki N, Sakakibara Y, et al. Persistent fifth aortic arch associated with type A aortic arch interruption. Histological study and morphogenesis. *Jpn J Thorac Cardiovasc Surg* 2001; **49**: 509-12.
 - 8) del Nido PJ, Williams WG, Wilson GJ, et al. Synthetic patch angioplasty for repair of coarctation of the aorta: experience with aneurysm formation. *Circulation* 1986; **74**(3 Pt 2): I32-6.
 - 9) Gerlis LM, Ho SY, Anderson RH, et al. Persistent 5th aortic arch—a great pretender: three new covert cases. *Int J Cardiol* 1989; **23**: 239-47.