

➤ **Case Report** ➤

Mediastinal Perigraft Seroma after Repair of Type A Dissection with a Polyester Graft

Takashi Yamauchi, MD, PhD,¹ Suguru Kubota, MD, PhD,¹
Kosei Hagawa, MD,¹ and Akira Suzuki, MD, PhD²

Perigraft seromas are uncommon after surgical repair of the thoracic aorta with woven polyester grafts. A 50-year-old woman required redo sternotomy for the treatment of a perigraft seroma 6 months after total arch replacement for acute type A dissection. After removal of a jelly-like mass, a prosthetic graft was covered with fibrin glue, and the bilateral pleurae beside the graft were opened widely for drainage of effusion into the bilateral pleural cavities. Bacterial culture and laboratory and histological examination of the content confirmed the final diagnosis of perigraft seroma. No evidence of recurrence was observed 4 months after drainage.

Keywords: perigraft seroma, mediastinum, Dacron graft

Introduction

A perigraft seroma (PGS) is a persistent, sterile collection of fluid that develops after a variety of vascular procedures. However, the development of PGS requiring redo sternotomy after thoracic aortic surgery with a polyester graft is extremely rare. We present a case of a PGS that developed after total arch replacement for acute type A dissecting aneurysm with a polyester graft.

Case Report

A 50-year-old woman with a history of hypertension was referred to our hospital for evaluation of chest and back pain. Computed tomography (CT) revealed a Stanford type A dissecting aneurysm. She underwent

emergency total arch replacement with left subclavian artery bypass using a four-branch polyester woven graft (22 mm × 9 × 9 × 11 mm J-graft, Japan Lifeline, Tokyo, Japan) and a straight-tube polyester woven graft (7 mm J-graft, Japan Lifeline) with a frozen elephant trunk (21 × 90 mm open-stent J-graft, Japan Lifeline). CT performed on postoperative day 5 showed marginal effusion around the prosthetic graft and heart, which was non-specific, similar to that in the early postoperative period. Her postoperative course was uneventful, and she was discharged on postoperative day 14. She was not administered anticoagulant or antiplatelet drugs. The patient was followed up in the outpatient clinic and remained in good condition. However, CT at 4 months after operation showed a large low-density area within a 80 × 60 mm diameter around the mediastinal graft (Fig. 1a). There was no evidence of the prosthetic graft being compressed severely by the large mass. The average radiodensity of the mass was 20 HU, suggesting a seroma rather than a blood clot. CT with atrial contrast showed no evidence of a pseudoaneurysm. The patient did not complain of any symptoms, such as dyspnea or chest discomfort. Therefore, she was carefully observed; however, she complained of a new subcutaneous mass formation at the sternal notch 1 month later. CT revealed an increase in effusion, which was continuous with the subcutaneous mass (Fig. 1b). Needle aspiration of the subcutaneous mass failed to provide an adequate specimen. The color of skin changed due to compression of the subcutaneous mass and self-destruction of the mass was imminent, which might result in deep sternal infection. Therefore, redo sternotomy was performed. A massive amount of almost lucent, jelly-like content with some fluid was removed. We found no bleeding site. Fibrin glue was applied to the surface of the graft to prevent serum leakage from the graft, and the bilateral pleurae beside the graft were opened wide for drainage of effusion into the pleural cavity.

Bacterial culture of the content was negative. Laboratory test results of the fluid component and blood were as follows: hemoglobin, 1.4 and 11.4 g/dl; total protein, 6.6 and 8.1 g/dl; albumin, 2.8 and 3.9 g/dl; creatinine, 0.53 and 0.81 mg/dl; lactate dehydrogenase, 8706 and

¹ Department of Cardiovascular Surgery, KKR Sapporo Medical Center, Sapporo, Hokkaido, Japan

² Department of Pathology, KKR Sapporo Medical Center, Sapporo, Hokkaido, Japan

Received: October 27, 2016; Accepted: November 28, 2016
Corresponding author: Takashi Yamauchi, MD, PhD. Department of Cardiovascular Surgery, KKR Sapporo Medical Center, 6-3-40 Ichijo Hiragishi, Toyohira, Sapporo, Hokkaido 062-0931, Japan

Tel: +81-11-822-1811, Fax: +81-11-841-4572

E-mail: yamataka@surg1.med.osaka-u.ac.jp



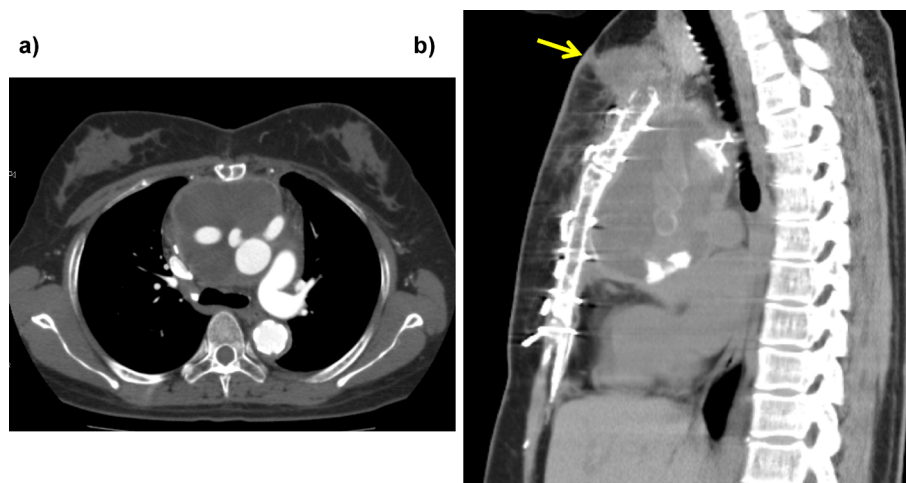


Fig. 1 (a) Computed tomography showed a large low-density area around the prosthetic graft (80×60 mm) 4 months postoperatively. (b) The mediastinal mass gradually expanded and was continuous with the newly developed subcutaneous mass 5 months postoperatively (arrow).

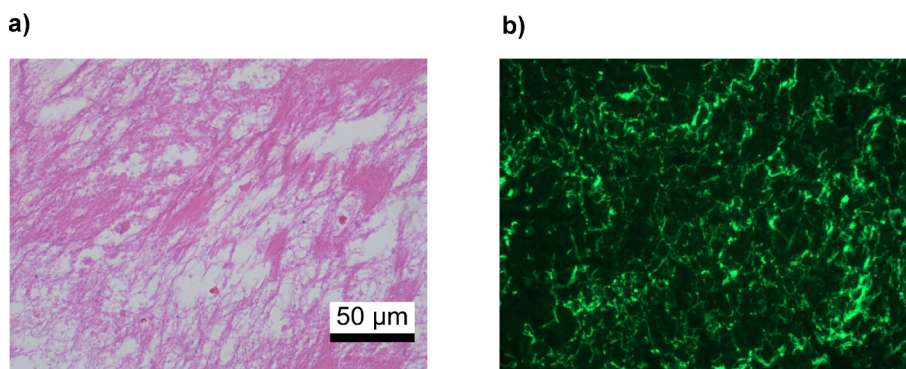


Fig. 2 (a) Hematoxylin and eosin staining showed fibrin network together with platelets and a few red blood cells. (b) Immunofluorescence for FITC conjugated antihuman fibrinogen showed mesh-patterned positive staining.

218 U/l; and triglycerides, 16 and 63 mg/dl, respectively. Histological examination of the jelly-like content revealed a multilayered fibrin network with platelets, but only scarce red and white blood cells (Fig. 2a). Mesh-like materials were confirmed as fibrin by immunofluorescence for anti-human fibrinogen (Fig. 2b). Based on these examination findings, a final diagnosis of perigraft seroma was confirmed.

The postoperative course was uneventful. No evidence of recurrence was observed 4 months after the operation.

Discussion

Development of a PGS has been reported after surgical repair of superficial axillofemoral and femorofemoral bypass,¹⁾ open surgical repair of abdominal aortic aneurysms (AAAs),²⁾ performance of modified Blalock–Taussig shunts,³⁾ and thoracic aortic surgery.⁴⁾ However, to our knowledge a mediastinal PGS, as in the present case, has

not been previously reported.

The symptoms of PGS vary depending on the site of formation. An asymptomatic mass,²⁾ pain, acute limb ischemia secondary to graft limb compression,⁵⁾ and respiratory distress³⁾ have been reported. Identification of a PGS in the clinical setting is difficult, and the condition remains a diagnosis of exclusion. The differential diagnoses include infection, false aneurysm, postoperative hematoma, and lymphatic fluid collection. Kadakol et al.⁵⁾ defined PGS as a perigraft fluid collection present for >3 months postoperatively with a diameter of ≥ 3.0 cm and radiodensity of ≤ 25 HU. The present case met all three of these criteria.

The mechanism of PGS formation remains unclear. However, several theories have been proposed, including an immunologic response,⁶⁾ low-grade infection,¹⁾ and discharge of fluid through the graft.⁷⁾ Whether the graft serves as a predisposing factor for PGS formation is controversial. Blumenberg et al.¹⁾ reported that knitted Dacron grafts were most frequently used, followed

by polytetrafluoroethylene (PTFE) grafts and autogenous vein grafts. Other authors have reported that all cases of PGS were associated with PTFE grafts.^{5,7)} Kadakol et al.⁵⁾ reported that diabetes, smoking, anticoagulation, bifurcated graft reconstruction, and the left flank retroperitoneal approach were independent risk factors for the development of a PGS after open repair of an AAA.

The previously reported treatment for PGS has varied. Kondo et al.²⁾ reported two cases of successful treatment by discontinuation of antiplatelet therapy after open surgical repair of AAA with a knitted polyester graft. Although the success rate of surgical intervention is unclear due to the rarity of PGS, some cases of successful surgical intervention have been reported. Ohtake et al.⁴⁾ reported successful endovascular therapy for a PGS after graft replacement of the descending aorta with a PTFE graft. Demircin et al.³⁾ reported success in wrapping Surgicell around the graft. Kadakol et al.⁵⁾ also reported that 4 of 20 patients (20%) with a PGS required intervention after open repair of AAA, and graft replacement with another type of graft was performed in 2 patients.

In the present case, the diagnosis was confirmed by a combination of radiodensity on preoperative CT, bacterial culture, and laboratory and histological examinations. The cause of a gradually expanding PGS after repair of the thoracic aorta remains unknown, and the efficacy of fibrin glue application to the surface of the graft is uncertain. However, we believe that opening the bilateral pleurae may effectively prevent recurrence of fluid collection around the prosthetic graft.

Conclusion

Physicians should be aware that chronic expanding mediastinal seroma with Dacron graft is one of the rare postoperative complications after thoracic aortic surgery. Opening the bilateral pleurae and applying fibrin glue to

the surface of graft may effectively prevent recurrence of fluid collection around the prosthetic graft.

Disclosure Statement

All authors have no conflict of interest.

Author Contributions

Writing: TY

Critical review and revision: all authors

Final approval of the article: all authors

Accountability for all aspects of the work: all authors

References

- 1) Blumenberg RM, Gelfand ML, Dale WA. Perigraft seromas complicating arterial grafts. *Surgery* 1985; **97**: 194-204.
- 2) Kondo Y, Muto A, Dardik A, et al. Perigraft seroma after surgical aortoiliac aneurysm repair with knitted polyester grafts: report of two cases. *Ann Vasc Dis* 2009; **2**: 44-6.
- 3) Demircin M, Dogan R, Ozkan M, et al. Perigraft seroma complicating the modified Blalock-Taussig shunts: two consecutive instances with review of literature. *Turk J Pediatr* 2004; **46**: 275-8.
- 4) Ohtake H, Kimura K, Soga S, et al. Stent-graft deployment to treat a perigraft seroma formed after descending thoracic aortic surgery. *J Endovasc Ther* 2007; **14**: 813-5.
- 5) Kadakol AK, Nypaver TJ, Lin JC, et al. Frequency, risk factors, and management of perigraft seroma after open abdominal aortic aneurysm repair. *J Vasc Surg* 2011; **54**: 637-43.
- 6) Ahn SS, Machleder HI, Gupta R, et al. Perigraft seroma: clinical, histologic, and serologic correlates. *Am J Surg* 1987; **154**: 173-8.
- 7) Williams GM. The management of massive ultrafiltration distending the aneurysm sac after abdominal aortic aneurysm repair with a polytetrafluoroethylene aortobiiliac graft. *J Vasc Surg* 1998; **28**: 551-5.