Circulation Journal
Official Journal of the Japanese Circulation Society
http://www.j-circ.or.jp

REVIEW

Human Heterotaxy Syndrome

– From Molecular Genetics to Clinical Features, Management, and Prognosis –

Isao Shiraishi, MD, PhD; Hajime Ichikawa, MD, PhD

Human heterotaxy syndrome is characterized by a wide variety of cardiac and extracardiac congenital malformations that are primarily induced by disorders of the left-right axis determination during early embryonic development. The cellular and molecular mechanisms of the left-right asymmetry have been extensively investigated in the past decade and the developmental mechanisms of the syndrome have been considerably elucidated. Medical and surgical management and treatment of heterotaxy syndrome have advanced as well. However, prognosis of the disease still remains unsatisfactory because the syndrome is often associated with a combination of complicated congenital heart diseases. Management of heterotaxy patients, particularly those who have undergone the Fontan procedure, is now one of the most important issues in pediatric and adult congenital heart disease clinics. In this review, we focus on the recent advances in knowledge of the genetic and molecular pathogenesis of heterotaxy syndrome, as well as its clinical features, management, and prognosis. (*Circ J* 2012; **76:** 2066–2075)

Key Words: Congenital heart disease; Genetics; Molecular biology; Surgery

Congenital heart diseases (CHD) affect approximately 0.75–0.9% of newborns and are the leading cause of death in neonates and infants.[1,2] The clinical issues of CHD were once limited to pediatric cardiologists and pediatric cardiac surgeons, because the survival rate of patients was, in general, low. Because medical and surgical treatments of CHD have become extremely advanced, over 90% of CHD patients survive until adulthood.[3,4] Consequently, the total number of adult patients with CHD currently exceeds that of children[4,5] and CHD is now becoming an essential part of healthcare not only for pediatric but also for adult cardiologists.

Among the various kinds of CHD, heterotaxy syndrome is one of the most serious. This syndrome occurs in approximately 1 to 5,000–7,000 of live births with CHD.[6,7] Heterotaxy syndrome is primarily induced by disorders of left-right axis determination during early embryonic development. Recently, the molecular mechanisms of the left-right axis determination have been extensively investigated in animal models including genetic engineering of mice.[8–11] Briefly, an initial break in symmetry occurs at the primitive node as a leftward "nodal flow", which is created by unidirectional rotation of nodal cell cilia. This flow provokes asymmetry signals that are transmitted toward the left lateral plate mesoderm (LPM), where downstream left-side specific growth and transcription factors, Nodal, Lefty2, and Pitx2c, are activated. As a result, Pitx2c and other undetermined factors regulate genetic programs in the left side of the body and create asymmetric organ morphogenesis. Human genetics have also revealed several genes that are responsible for left-right laterality and heterotaxy syndrome, including ZIC3, NODAL, LEFTY2.[11,12]

In the clinical field, precise diagnosis and surgical treatment of patients with heterotaxy syndrome have recently advanced as well. However, outcomes and the survival rate of patients are not satisfactory because this syndrome is often associated with combinations of serious CHDs.[13,14] The mid- to long-term prognosis of heterotaxy patients who undergo the Fontan procedure for single ventricular physiology is now an important issue in pediatric and adult CHD clinics.[15–18]

Morphological Characteristics of Heterotaxy Syndrome

Patients with heterotaxy syndrome are subdivided into "bilateral right-sided" (right isomerism) or "bilateral left-sided" (left isomerism) according to the characteristic morphology of the atrial appendages of the heart.[13,14] However, there is a wide spectrum of pathology, with considerable overlap of the anatomical features. The morphological characteristics of heterotaxy syndrome are summarized in **Table**.

Molecular and Cellular Mechanisms of Left-Right Determination

To elucidate the etiology of heterotaxy syndrome, it is neces-

Received July 22, 2012; accepted July 23, 2012; released online August 3, 2012
Department of Pediatric Cardiology (I.S.), Department of Pediatric Cardiac Surgery (H.I.), National Cerebral and Cardiovascular Center, Suita, Japan
Mailing address: Isao Shiraishi, MD, PhD, Department of Pediatric Cardiology, National Cerebral and Cardiovascular Center, 5-7-1 Fujishirodai, Suita 565-8565, Japan. E-mail: isao@hsp.ncvc.go.jp
ISSN-1346-9843 doi:10.1253/circj.CJ-12-0957
All rights are reserved to the Japanese Circulation Society. For permissions, please e-mail: cj@j-circ.or.jp

Table. Morphological Characteristics of Heterotaxy Syndrome

Right isomerism	Left isomerism
Cardiovascular malformations	**Cardiovascular malformations**
Common atrium with bilateral right atrial appendages	Bilateral left atrial appendages
Mesocardia/dextrocardia	Complete/incomplete AV septal defect
Atrioventricular discordance	Unbalanced ventricles
Single right ventricle	Persistent left superior vena cava sometimes draining into the left atrium
AV septal defect	Interrupted hepatic portion of the inferior vena cava
Common AV connection associated with AV valve regurgitation	Partial anomalous pulmonary venous drainage
Double-outlet right ventricle	Hypoplastic sinus node (sick sinus syndrome)
Malposition of the great arteries	Single/paired AV nodes
Pulmonary stenosis or atresia	Interruption between AV node and His bundles (congenital AV block)
Total anomalous pulmonary venous drainage (with/without PVO)	**Extracardiac malformations**
Right aortic arch	Bilateral left-sided lungs and bronchi
Bilateral superior vena cava	Bilateral hyparterial bronchi
Bilateral sinus node	Polysplenia
Paired (anterior/posterior) AV nodes with sling formation	Midline liver
	Extrahepatic biliary atresia/hypoplasia
Extracardiac malformations/dysfunctions	
Bilateral right-sided lungs and bronchi	Extrahepatic portal vein atresia
Asplenia (susceptibility to *Streptococcus pneumoniae*)	
Symmetrical liver	
Right-sided stomach	
Malrotation of the intestine	
Bronchial cilia dysfunction	

AV, atrioventricular; PVO, pulmonary venous obstruction.

sary to understand the underlying molecular and cellular mechanisms of determination of the left-right body axis during early embryogenesis.[8–12] This process initiates in the primitive node at E7.5 in mice and develops through the following pathways:[19,20] (1) breaking of symmetry as a result of the leftward nodal flow generated by rotational movement of primary cilia in the node; (2) transmission of asymmetric signals to the LPM; (3) asymmetric expression of Nodal and Lefty2, which encodes a feedback inhibitor of Nodal signaling, in the LPM; and (4) situs-specific morphogenesis mediated by asymmetric expression of Pitx2, which encodes a transcription factor and is regulated by Nodal signaling.

Node Cell Monocilia Create Leftward "Nodal Flow" and Activate Asymmetry Signaling Around the Node

The determination of left-right asymmetry starts as leftward nodal flow generated by rotational movement of monocilia in the primitive node[21,22] (**Figures 1A–D**). Monocilia consist of 2 different, highly sensitive subtypes: motile and immotile monocilia (**Figure 1A**).[23–27] Motile cilia are predominantly located in the central region of the node and contain left-right dynein (*lrd)* in mice,[28] and the gene responsible for Kartagener's syndrome, *DNAH5*, in human[29] as a motor protein on microtubules (**Figure 1B**). In contrast, the immotile mechanosensory cilia expressing the calcium ion channel polycystin-2 (Pkd2) are located in the peripheral region of the node.[23,30] Clockwise rotation of the motile cilia creates a unidirectional leftward flow at the surface of the node because the rotational axes of the cilia tilt in the caudal direction of the embryo (**Figure 1C**).[31,32]

Although the nodal flow is the initial break in body symmetry, the precise mechanism of how this flow is perceived by nodal and perinodal cells remains uncertain. One hypothesis (chemosensory model) is that the nodal flow produces a gradient of left determinant particles (node vesicular parcels, NVPs) containing hedgehog proteins and retinoic acid secreted by node pit cells (**Figure 1D**).[27,33] The secretion of NVPs is regulated by fibroblast growth factor 8.[33] These morphogens, in association with Nodal secreted in the node, activate downstream signaling of Nodal in the left-side perinodal cells. For instance, a transcription enhancer, ANE and Smad2/3, is activated by Nodal signaling and exhibits left dominant asymmetric expression in perinodal cells.[20] Consequently, the left-side dominant active Nodal in the node is translated into asymmetry in the left LPM.

An alternative hypothesis (mechanosensory model) is that the leftward nodal flow provokes an asymmetrical increase influx of Ca^{2+} ion in the sensory cilia cells through *PKD2*, a causative gene for human polycystic kidney disease.[23,32] This Ca^{2+} influx is linked to the activation of Nodal in the left-side perinodal cells, which is consequently transferred to the left LPM (**Figure 1D**).

Experimental creation of the reverse nodal flow results in a reverse pattern of asymmetric gene expression.[34] Mutations in the left-right dynein (Dnahc11)[35] or kinesin (KIF13),[36,37] which are the motor proteins of microtubules, give rise to randomization of the left-right asymmetry. Mutations in dynein assembly factor, DNAAF3, induce primary cilia dyskinesia and disturbance of left-right asymmetry in mice.[38] In embryos with mutations of Noto, a transcription factor regulating cilia formation, left-right asymmetry of internal organs and expression of laterality markers is randomized.[39] The Notch ligand Dll1-

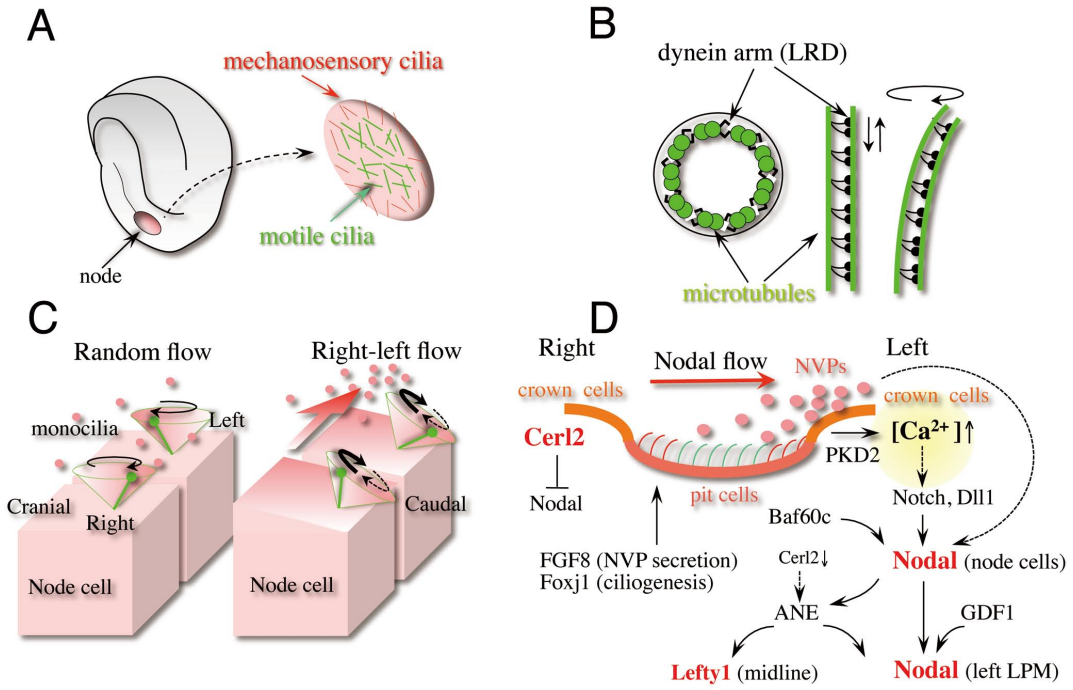

Figure 1. Breaking of symmetry as a result of the leftward nodal flow generated by rotational movement of primary cilia in the node. Nodal cell cilia comprise motile and mechanosensory ones (**A**). Cilia consist of microtubules and dynein arms, which express left-right dynein (LRD) in mice (**B**). The rotational axes of the cilia tilt caudally in embryos, which creates unidirectional leftward "nodal flow" (**C**). Signaling mechanism of Nodal and related molecules in the nodal pit cells and surrounding node crown cells (**D**). NVP, nodal vesicular parcels.

mediated Notch signaling pathway plays a primary role in the establishment of left-right asymmetry by directly regulating expression of *Nodal* around the node.[40] A t-box transcription factor, Tbx6, is also involved in left-right determination through Notch-mediated Nodal signaling and formation of node cell monocilia.[41] A member of the GLI superfamily zinc finger transcription factor, Zic3, is also involved in left-right patterning.[42,43] The precise mechanism of the laterality defect remains unknown, but Zic3 deficiency is associated with decreased expression of cardiac-specific genes, including *Nkx2.5*, *Tbx5* and *ANF*.[44] Epigenetic regulation with a chromatin modifier, Baf60c, has also been shown to control left-right asymmetry via Notch-mediated induction of Nodal.[45] In addition to activation of Nodal in the left side of the node, an endogenous nodal antagonist, Cerl2, is expressed around the right side of the node and is responsible for downregulation of Nodal in the right side of the embryo.[20,46,47]

An experimental perturbation of the left-right determination process induced by maternal administration of retinoic acid at E6.5 to E7.0 is shown in **Figure 2**. **Figures 2A–D** and **Figures 2E–I** demonstrate dissected late fetal mice with right and left atrial isomerism, respectively. Nodal mRNA expression is limited in the left-side in a control mouse embryo (**Figure 2J**), and Nodal expression is randomly distributed in a RA-treated one (**Figure 2K**).

Asymmetry Signaling Transmits to the Left LPM and Upregulates Left Determinants Such as Nodal, Lefty2, and Pitx2

Transmission of Nodal to the left LPM followed by Pitx2 activation and the consequent heart morphogenesis in normal subjects is summarized in **Figure 3A**. Possible mechanisms of right/left isomerism and situs inversus from the viewpoint of nodal flow and the distribution of left determinants are shown in **Figures 3B,C**.

Activated Nodal in the left side of the primary node is transmitted toward the left LPM and midline. A member of the transforming growth factor (TGF)-β superfamily growth/differentiation factor 1 (GDF1) plays a role in the transportation of Nodal.[48,49] Nodal activates other members of the TGF-β superfamily: lefty1 in the left LPM and lefty2 in the midline.[50] Lefty1 and lefty2 compete and antagonize nodal activity to restrict the extent and duration of nodal signaling.[51] Bone morphogenic protein (BMP) also plays a role in negatively regulating Nodal expression. Chordin and noggin, which are BMP signaling antagonists, promote Nodal signaling around the node, while BMP signaling represses Nodal expression in the left LPM.[52,53] The Nodal signaling pathway is mediated by an activin receptor complex composed of a dimmer of the type I activin receptor, ActRIB, and a dimeric type II receptor, ActRII or ActRIIB.[54] Different from conventional Activin signaling, the Nodal pathway requires activities of membrane-bound EGF-CFC co-receptors, Cripto and Cryptic.[55] Loss-of-function mutations in the EGF-CFC genes are associated with left-right laterality defects.[56]

Consequently, Nodal in the left LPM upregulates a transcription factor, Pitx2. *Pitx2* is a major laterality gene and plays a direct and pivotal role in asymmetric organogenesis of the heart and other visceral organs.[57] *Pitx2c*, a left-right asymmetric isoform, is expressed in the left LPM, outflow tract myocar-

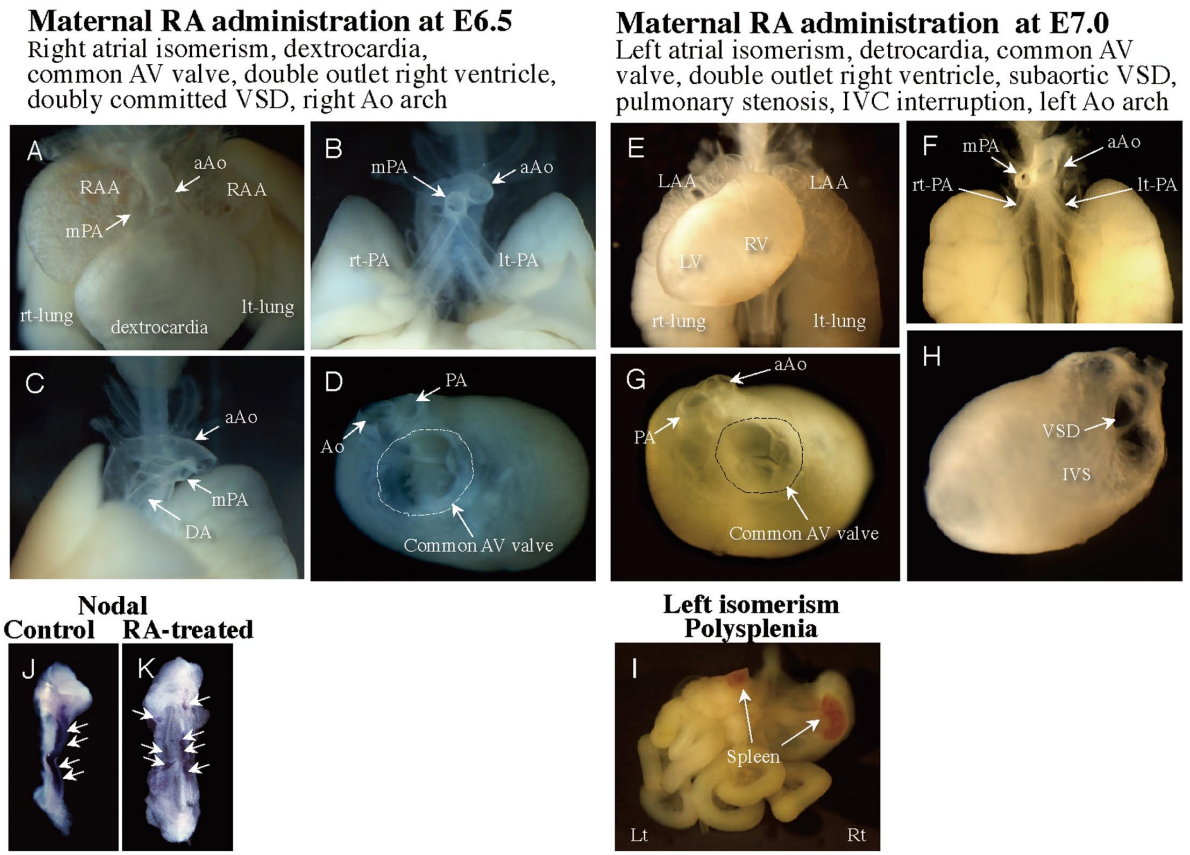

Figure 2. Experimental perturbation of the left-right determination process induced by maternal administration of retinoic acid at E6.5 to E7.0. A late fetal mouse treated with retinoic acid at E6.5 shows right atrial isomerism (**A**–**D**). A late fetal mouse treated with retinoic acid at E7.0 shows left atrial isomerism with multiple spleen (**E**–**I**). Nodal mRNA expression is limited in the left side of a control mouse embryo (**J**), while Nodal is randomly distributed in a RA-treated one (**K**).

dium, left side of the brachial arch, artery, and the left atrium.[58,59] The loss-of-function of Pitx2c induces severe cardiac malformations including right isomeric heart.[59] Recently, *Pitx2* was identified as a suspect for human atrial electric and structural remodeling arrhythmias, because, for example, PITX2C is significantly decreased in human patients with sustained atrial fibrillation.[60] *Cited2*, a transcriptional co-activator and is a negative regulator of HIF-1α, is also involved in left-right patterning.[61,62] In association with AP2, *Cited2* activates *Nodal*-mediated gene transcription such as *Nodal*, *Lefty2*, and *Pitx2* in the LPM.[61,63]

Genes Associated With Human Heterotaxy Syndrome

Recent human and animal model studies have provided insights into the genetic and developmental etiology of the heterotaxy syndrome. In humans, genes that are associated with heterotaxy syndrome are *ZIC3*, *NODAL*, *CFC1*, *ACVR2B*, *LEFTY2*, *CITED2*, and *GDF1*.[44,56,64–67]

Clinical Manifestation of the Heterotaxy Syndrome

Because the overall short- to mid-term prognosis of heterotaxy patients is not satisfactory, treatment is determined by the nature and severity of the cardiac and extracardiac abnormalities.[68,69] Factors that deteriorate the prognosis of heterotaxy patients have been described as complications with pulmonary venous obstruction, pulmonary arterial distortion, regurgitation of the atrioventricular valve, elevated pulmonary vascular resistance, and impaired ventricular function.[70]

Right Isomerism

Neonates with right isomerism typically show a single atrium, single right ventricle, and a univentricular atrioventricular connection often associated with atrioventricular valve regurgitation. First stage palliation of such patients is control of pulmonary blood flow. If the pulmonary artery is atresic or severely stenotic, intravenous administration of prostaglandin E1 is necessary to open the left ductus, followed by the surgical operation of systemic pulmonary shunt (modified Blalock-Taussig shunt). If the pulmonary artery is not stenotic, pulmonary artery banding is necessary to protect the pulmonary vasculature until the Glenn and Fontan procedures can be performed. Both surgical interventions are generally performed approximately 2–4 weeks after birth, depending on the patient's body weight and complications. Pulmonary venous obstruction because of total anomalous pulmonary venous drainage should be precisely diagnosed and immediately repaired by surgical operation. However, the complication of pulmonary venous obstruction in patients with right isomerism is prob-

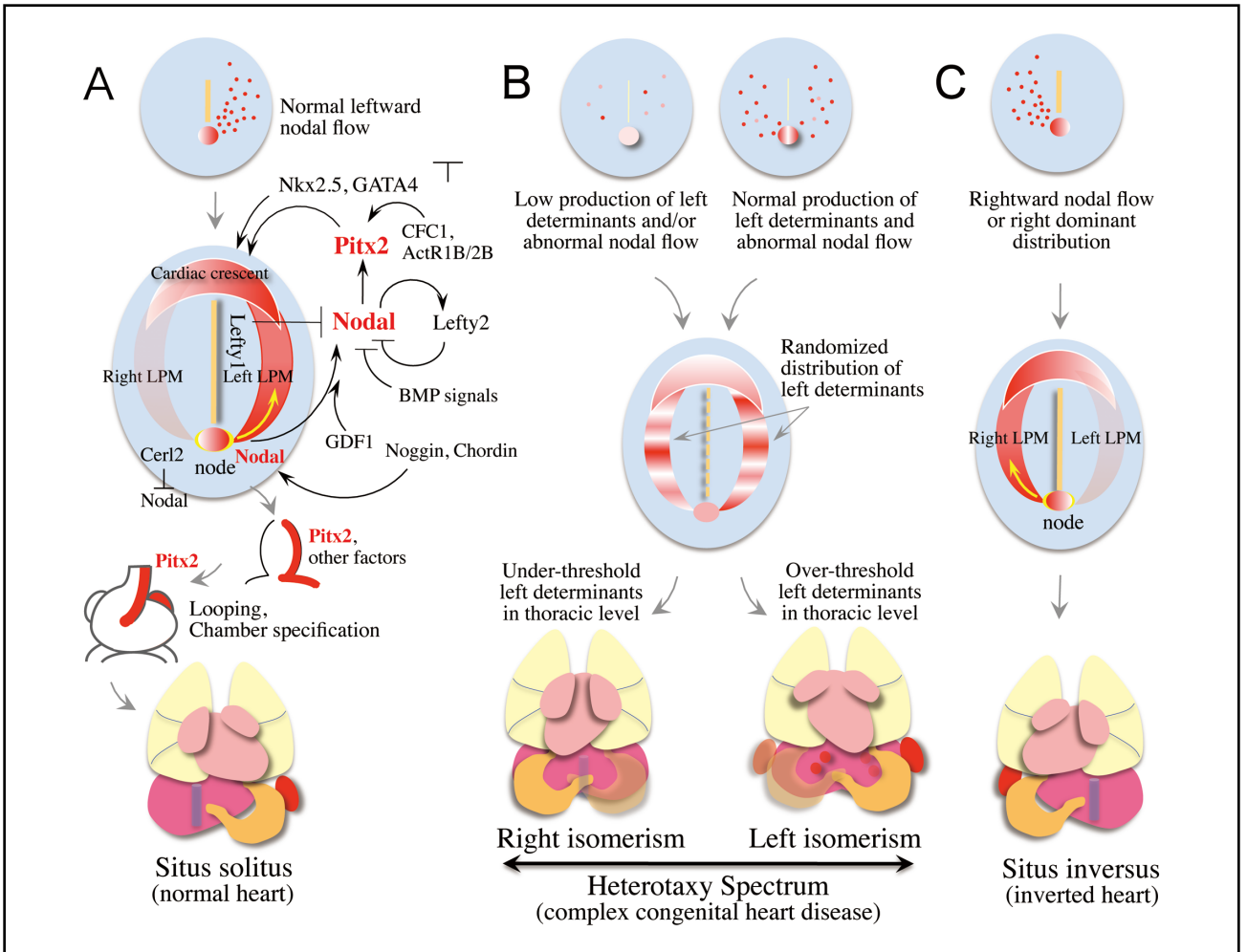

Figure 3. Signal transmission of Nodal to the left lateral plate mesoderm followed by Pitx2 activation and consequent heart morphogenesis in normal embryos (**A**). Possible mechanisms of right/left isomerism and situs inversus from the viewpoint of nodal flow and distribution of left determinants (**B**,**C**). Right isomerism is a condition where production of left determinants is low and/or nodal flow is abnormal. As a result, the left signal is not activated in both sides. Left isomerism is a condition where production of left determinants is normal but nodal flow is abnormal. As a result, the left signal is activated in the both sides. Normal production of left determinants and inverse nodal flow results in situs inversus.

lematic because recurrent obstruction often occurs despite surgical repair, including sutureless techniques.[71] At 3–6 months after the first palliation, cardiac catheterization is performed to ensure that pulmonary arterial pressure and resistance are appropriate for the next procedure. In some patients with right isomerism, the normal 6th pharyngeal arch-derived pulmonary arteries are underdeveloped and pulmonary blood flow is supplied by major aortopulmonary collateral arteries (MAPCAs). In these cases, unifocalization of the MAPCAs in combination with a systemic pulmonary shunt is necessary in infancy if applicable.

Second-stage palliation is a bidirectional Glenn shunt, whereby the right and/or left superior vena cava is isolated and connected to the pulmonary artery. This operation is, in general, performed around 6 months after birth. If the atrioventricular valve regurgitation is hemodynamically significant, simultaneously repair or replacement of the common atrioventricular valve is necessary. At 4–6 months after bidirectional Glenn shunt, cardiac catheterization is again necessary to evaluate whether the hemodynamic conditions are satisfactory for the final palliation of a Fontan-type procedure, which nowadays means total cavopulmonary connection (TCPC).[72] The criteria for successful Glenn shunt and TCPC include pulmonary arterial pressure <15 mmHg, pulmonary arterial resistance <2.5 U/m^2, atrioventricular valve regurgitation <mild, single ventricular ejection fraction >50%, and no significant distortion or stenosis of the pulmonary branch arteries.[73–75] Significant stenotic lesions of the pulmonary arteries should be treated using percutaneous transluminal balloon angioplasty. In patients with severe hypoxia, aortopulmonary collateral arteries develop and supply blood to the pulmonary circulation. These collateral vessels seemingly improve cyanosis, but the retrograde blood flow interferes with normal antegrade pulmonary arterial flow and consequently raises the central venous pressure after TCPC completion.[76] These collateral vessels should be occluded with catheter-based coil embolization before the Fontan procedure.

The third-stage palliation for right isomerism patients is to connect the inferior vena cava and hepatic veins to the pulmonary artery. Recently, a modification using an extracardiac artificial conduit type TCPC is most often used, because the

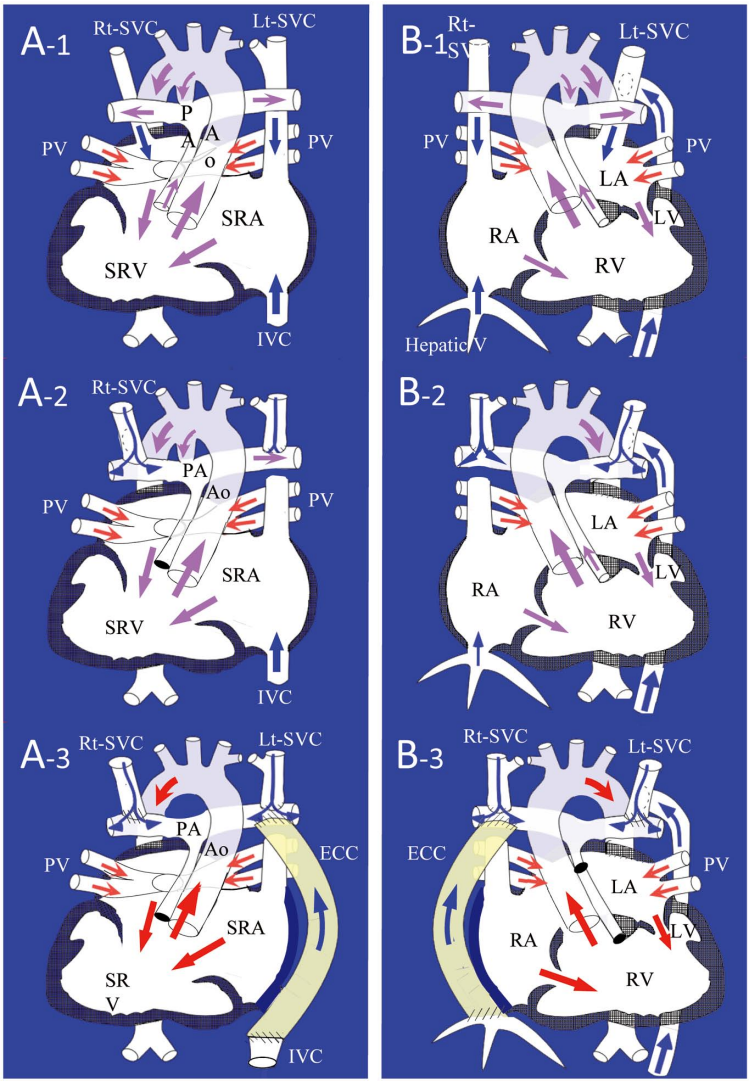

Figure 4. Surgical procedures of right isomerism (**A-1**–**A-3**) and left isomerism (**B-1**–**B-3**). Representative right atrial isomerism (**A-1**) after bilateral bidirectional Glenn shunt (**A-2**), and completion of the Fontan procedure (total cavopulmonary connection, TCPC) (**A-3**). Representative left atrial isomerism (**B-1**) after bilateral bidirectional Glenn anastomosis (total cavopulmonary shunt, TCPS) (**B-2**), and completion of the Fontan procedure (TCPC) (**B-3**).

long-term prognosis of the conventional procedure (atriopulmonary connection, APC) has proved to be unsatisfactory, characterized by enlargement of the atrium, intractable atrial tachyarrhythmias, and thromboembolism.

After successful completion of the TCPC, cyanosis disappears and the general condition of the patient improves. However, the number of right isomerism patients who have undergone successful Fontan procedure is approximately 50%, because right isomerism is often accompanied by a combination of severe and complicated CHDs.[77] Biventricular repair can be achievedin only a few patients with right isomerism.[78] The surgical procedures for right isomerism are illustrated in **Figure 4A**.

Left Isomerism

In contrast to right isomerism, the combination of the cardiac malformations in left isomerism is not so complicated. Left isomerism is typically associated with atrioventricular septal defect (AVSD), persistent left superior vena cava, interrupted hepatic portion of the inferior vena cava, and atrioventricular conduction disturbance.[13] Patients with the complete type of AVSD may undergo pulmonary artery banding in the neonatal period to protect the pulmonary vasculature. In left isomerism, the sinus node and atrioventricular node are usually hypoplastic and sinus bradycardia or complete atrioventricular block is a frequently accompaniment. In patients with severe bradycardia because of complete atrioventricular block from the fetal period, implantation of a pacemaker should be considered immediately after birth. Several months after pulmonary arterial banding, cardiac catheterization should be performed to ensure decreased pulmonary arterial pressure and resistance. Biventricular repair with a 2-patch method is usually performed for the complete type of AVSD with balanced ventricles.[79]

AVSD with unbalanced ventricles is sometimes seen in patients with left isomerism, where either of the ventricles and the inflow tract is significantly hypoplastic, for instance in less than 30%.[80] In these cases, biventricular repair is not feasible. Bidirectional Glenn anastomosis followed by extracardiac shunt between the hepatic veins and pulmonary artery should be considered according to the criteria of the operation. If the patient's systemic outflow tract exhibits signs of potential stenosis, the double-barrel Damus-Kaye-Stansel operation is also

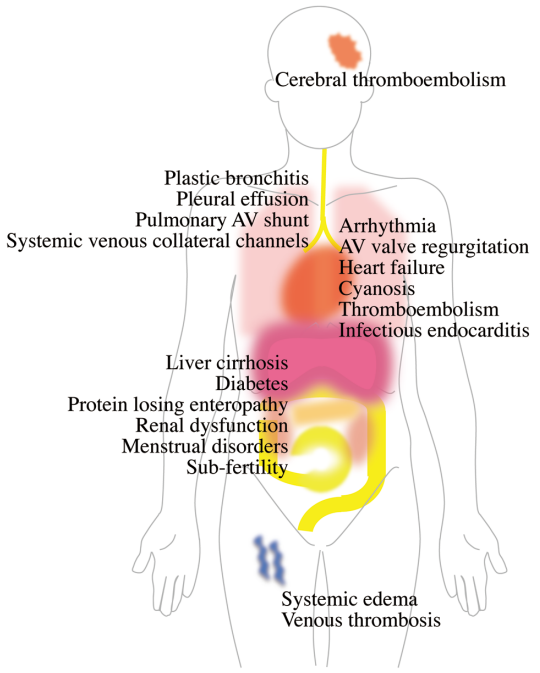

Figure 5. Possible mid- to long-term complications after completion of the Fontan procedure for heterotaxy patients.

performed in order to prevent ventricular outflow obstruction after the bidirectional Glenn shunt.

In either case of right or left isomerism, a hepatic to pulmonary connection is mandatory to avoid the development of pulmonary atriovenous fistula.[81] Congenital absence of the portal vein is a rare but noteworthy complication of left isomerism.[82] Pulmonary arterial hypertension may develop because of massive portosystemic shunt via the ductus venosus or other venous collaterals. Surgical procedures for left isomerism are illustrated in **Figure 4B**.

Long-Term Prognosis of Heterotaxy Patients

Although the medical and surgical treatments of heterotaxy syndrome are remarkably advanced, the long-term prognosis of the patients remains unsatisfactory. Right isomerism has been recognized as one of the worst forms of CHD, with the overall 5-year survival ranging from 30% to 74%. The results are better for left isomerism, with 5-year survival rates ranging between 65% and 84%, which is still considerably lower than survival for most other forms of CHD.[83] The main reason is that the nature of the Fontan single ventricle physiology is fundamentally imperfect and the Fontan circulation is likely to fail earlier than the normal biventricular counterpart. Management of the complications of the Fontan circulation and improvement of the long-term prognosis are becoming important issues in the field of pediatric and adult CHD.[17,18] Cardiac complications include intractable atrial or ventricular arrhythmia, atrioventricular valve regurgitation, progressive heart failure, thromboembolism, pericardial effusion, and infectious endocarditis.[70,84–86] Extracardiac complications include pleural effusion, plastic bronchitis, progressive cyanosis because of pulmonary arteriovenous shunts or systemic venous shunt to the left heart, liver dysfunction, liver cirrhosis, hepatocellular carcinoma,[87] glucose intolerance and diabetes,[88] renal dysfunction, protein-losing enteropathy (PLE),[85,86] ascites, menstrual disorders and subfertility in female patients,[89] systemic edema, and systemic thromboembolism including cerebral infarction.[70,84,85] High risks of pregnancy and delivery, including deterioration of arrhythmias, progression of heart failure, coagulopathy, and miscarriage, have also been reported in women with Fontan circulation.[90] Representative long-term complications of the Fontan operation are illustrated in **Figure 5**.

PLE

PLE, one of the most severe manifestation of the failing Fontan circulation, occurs in 5–10% of the total postoperative cases.[70,85,86,91] Chronic loss of serum proteins into the gastrointestinal tract results in systemic edema, ascites, pleural effusion, diarrhea, gastrointestinal bleeding, susceptibility to infections, and ultimately cachexia. The underlying mechanism of PLE remains uncertain. Elevated concentrations of inflammatory factors, such as tumor necrosis factor (TNF)-α or IFN-α, dilatation of intestinal lymphatic vessels, and widening of gap junctions between intestinal epithelial cells may be involved in the protein and fluid losses.[92] Liver cirrhosis is often associated with the postoperative state of the Fontan circuits, in which elevated portal resistance and mesenteric pressure may be involved in the pathogenesis of PLE. Steroids, high-molecular-weight heparin,[93] sildenafil,[94] surgical interventions (eg, creation of a systemic-to-pulmonary venous atrial-level communication (fenestration)[95] or conversion of the Fontan circuit)[86] have been described as effective. Recently, the efficacy of oral controlled-released steroid, budesonide, for PLE has been reported.[96,97] To date, however, cardiac transplantation is considered to be the only and complete resolution of PLE pathophysiology.[98,99]

Arrhythmias

Reentrant atrial tachyarrhythmias are the most common in patients after the Fontan operation and are often associated with deterioration of hemodynamics, either causally or as a result.[70] Hemodynamic abnormalities such as valve regurgitation or outflow obstruction, if present, should be aggressively treated by surgery. Catheter ablation is generally challenging because the anatomical structure of the patient is complex and catheter approach is difficult after TCPC, even with the development of the contemporary 3-dimensional mapping system.[100,101] The Maze procedure may be considered, particularly where conversion of the circuit is necessary.[102]

Heart Failure

The initial feature of heart failure long after the Fontan procedure is generally worsening of ventricular relaxation and compliance.[70,103,104] These abnormalities may be caused by exposure to hypoxia and volume/pressure overload preceding the Fontan procedure, repetitive surgical operations, and the hemodynamic disadvantages of the Fontan circuit. These changes are primarily progressive, potentially reducing ventricular filling volume, elevating pulmonary arterial pressure, and consequently leading to failure of the Fontan circuit. Late after the Fontan procedure, systolic dysfunction becomes apparent in a group of patients. Administration of angiotensin-converting enzyme inhibitors or β-blockade may be beneficial for particular patients, although the clinical evidence and cellular mechanisms remain to be elucidated.[105,106]

Hepatic Dysfunction

Hepatic dysfunction, liver fibrosis, and cirrhosis are common

complications in patients long after the Fontan operation.[70,107,108] Sinusoidal dilatation and sinusoidal fibrosis are marked in Fontan patients.[107,108] The cause of the hepatic changes may be chronic elevation of central venous and portal venous pressures.[87] Significant portal fibrosis had occurred in most of those who died soon after the Fontan procedure, suggesting that hepatic fibrosis begins before the Fontan operation.[109] Recently, cases of hepatocellular carcinoma after the Fontan operation have been reported.[110] Careful observation is necessary to detect the hepatic changes long after the Fontan operation.

Management of the Failing Fontan Patient

The patients who undergo APC or the lateral tunnel procedure are likely to be complicated with thromboembolism or intractable arrhythmias because of enlargement of the right atrium.[70,86] Surgical intervention with conversion to TCPC is required before such complications become irreversible.[102,111] A right atrial Maze procedure is simultaneously considered in patients with intractable atrial tachyarrhythmia.[102,112]

Cardiac transplantation may be the only option for patients with severe heart failure, intractable arrhythmias, or recurrent PLE.[98,99,113]

Future Directions

In the basic science field, embryonic development of left-right asymmetry has been uncovered by means of genetic engineering of mice. In addition, advanced human genetics has uncovered many of the genes responsible for human heterotaxy syndrome. By means of innovative technologies, such as next-generation sequencer or patient-based human inducible pluripotent stem cells, novel genes will be clarified and analyzed. In the clinical field, anatomical and physiological diagnosis from the fetal period, better clinical management after birth, tailor-made surgical operations, and systematic follow-up of the patients will improve their prognosis. Cell or tissue-based regeneration therapies could recover cardiac function of the failing Fontan patients. Multiple approaches including basic and clinical science are necessary to improve the prognosis and quality of life of heterotaxy patients.

Acknowledgments

The authors gratefully acknowledge Dr Masae Morishima for her excellent dissection, precise diagnosis, and in situ hybridization of the retinoic acid-treated mouse fetus. The authors also acknowledge members of pediatric cardiology and pediatric cardiac surgery at the National Cerebral and Cardiovascular Center for their clinical management and treatment of patients.

Disclosures

None.

References

1. Van der Linde D, Konings EE, Slager MA, Witsenburg M, Helbing WA, Takkenberg JJ, et al. Birth prevalence of congenital heart disease worldwide: A systematic review and meta-analysis. *J Am Coll Cardiol* 2011; **58:** 2241–2247.
2. Hoffman JI, Kaplan S. The incidence of congenital heart disease. *J Am Coll Cardiol* 2002; **39:** 1890–1900.
3. Khairy P, Ionescu-Ittu R, Mackie AS, Abrahamowicz M, Pilote L, Marelli AJ. Changing mortality in congenital heart disease. *J Am Coll Cardiol* 2010; **56:** 1149–1157.
4. Marelli AJ, Mackie AS, Ionescu-Ittu R, Rahme E, Pilote L. Congenital heart disease in the general population: Changing prevalence and age distribution. *Circulation* 2007; **115:** 163–172.
5. Shiina Y, Toyoda T, Kawasoe Y, Tateno S, Shirai T, Wakisaka Y, et al. Prevalence of adult patients with congenital heart disease in Japan. *Int J Cardiol* 2011; **146:** 13–16.
6. Reller MD, Strickland MJ, Riehle-Colarusso T, Mahle WT, Correa A. Prevalence of congenital heart defects in metropolitan Atlanta, 1998–2005. *J Pediatr* 2008; **153:** 807–813.
7. Lin AE, Ticho BS, Houde K, Westgate MN, Holmes LB. Heterotaxy: Associated conditions and hospital-based prevalence in newborns. *Genet Med* 2000; **2:** 157–172.
8. Chen CM, Norris D, Bhattacharya S. Transcriptional control of left-right patterning in cardiac development. *Pediatr Cardiol* 2010; **31:** 371–377.
9. Levin M. The embryonic origins of left-right asymmetry. *Crit Rev Oral Biol Med* 2004; **15:** 197–206.
10. Shiratori H, Hamada H. The left-right axis in the mouse: From origin to morphology. *Development* 2006; **133:** 2095–2104.
11. Belmont JW, Mohapatra B, Towbin JA, Ware SM. Molecular genetics of heterotaxy syndromes. *Curr Opin Cardiol* 2004; **19:** 216–220.
12. Zhu L, Belmont JW, Ware SM. Genetics of human heterotaxias. *Eur J Hum Genet* 2006; **14:** 17–25.
13. Jacobs JP, Anderson RH, Weinberg PM, Walters HL 3rd, Tchervenkov CI, Del Duca D, et al. The nomenclature, definition and classification of cardiac structures in the setting of heterotaxy. *Cardiol Young* 2007; **17**(Suppl 2)**:** 1–28.
14. Cohen MS, Anderson RH, Cohen MI, Atz AM, Fogel M, Gruber PJ, et al. Controversies, genetics, diagnostic assessment, and outcomes relating to the heterotaxy syndrome. *Cardiol Young* 2007; **17**(Suppl 2)**:** 29–43.
15. Bartz PJ, Driscoll DJ, Dearani JA, Puga FJ, Danielson GK, O'Leary PW, et al. Early and late results of the modified fontan operation for heterotaxy syndrome 30 years of experience in 142 patients. *J Am Coll Cardiol* 2006; **48:** 2301–2305.
16. Serraf A, Bensari N, Houyel L, Capderou A, Roussin R, Lebret E, et al. Surgical management of congenital heart defects associated with heterotaxy syndrome. *Eur J Cardiothorac Surg* 2010; **38:** 721–727.
17. Hoashi T, Ichikawa H, Fukushima N, Ueno T, Kogaki S, Sawa Y. Long-term clinical outcome of atrial isomerism after univentricular repair. *J Card Surg* 2009; **24:** 19–23.
18. Ohuchi H, Kagisaki K, Miyazaki A, Kitano M, Yazaki S, Sakaguchi H, et al. Impact of the evolution of the Fontan operation on early and late mortality: A single-center experience of 405 patients over 3 decades. *Ann Thorac Surg* 2011; **92:** 1457–1466.
19. Hamada H. Molecular mechanisms of left-right development. *In*: Rosenthal N, Harvey RP, editors. Heart development and regeneration. Vol 1. London: Academic Press, 297–306.
20. Kawasumi A, Nakamura T, Iwai N, Yashiro K, Saijoh Y, Belo JA, et al. Left-right asymmetry in the level of active Nodal protein produced in the node is translated into left-right asymmetry in the lateral plate of mouse embryos. *Dev Biol* 2011; **353:** 321–330.
21. Nonaka S, Tanaka Y, Okada Y, Takeda S, Harada A, Kanai Y, et al. Randomization of left-right asymmetry due to loss of nodal cilia generating leftward flow of extraembryonic fluid in mice lacking KIF3B motor protein. *Cell* 1998; **95:** 829–837.
22. Hirokawa N, Tanaka Y, Okada Y. Cilia, KIF3 molecular motor and nodal flow. *Curr Opin Cell Biol* 2012; **24:** 31–39.
23. McGrath J, Somlo S, Makova S, Tian X, Brueckner M. Two populations of node monocilia initiate left-right asymmetry in the mouse. *Cell* 2003; **114:** 61–73.
24. Shinohara K, Kawasumi A, Takamatsu A, Yoshiba S, Botilde Y, Motoyama N, et al. Two rotating cilia in the node cavity are sufficient to break left-right symmetry in the mouse embryo. *Nat Commun* 2012; **3:** 622.
25. Tabin CJ, Vogan KJ. A two-cilia model for vertebrate left-right axis specification. *Genes Dev* 2003; **17:** 1–6.
26. Lee JD, Anderson KV. Morphogenesis of the node and notochord: The cellular basis for the establishment and maintenance of left-right asymmetry in the mouse. *Dev Dyn* 2008; **237:** 3464–3476.
27. Okada Y, Nonaka S, Tanaka Y, Saijoh Y, Hamada H, Hirokawa N. Abnormal nodal flow precedes situs inversus in iv and inv mice. *Mol Cell* 1999; **4:** 459–468.
28. Supp DM, Witte DP, Potter SS, Brueckner M. Mutation of an axonemal dynein affects left-right asymmetry in inversus viscerum mice. *Nature* 1997; **389:** 963–966.
29. Olbrich H, Häffner K, Kispert A, Völkel A, Volz A, Sasmaz G, et al. Mutations in DNAH5 cause primary ciliary dyskinesia and randomization of left-right asymmetry. *Nat Genet* 2002; **30:** 143–144.
30. Pennekamp P, Karcher C, Fischer A, Schweickert A, Skryabin B, Horst J, et al. The ion channel polycystin-2 is required for left-right axis determination in mice. *Curr Biol* 2002; **12:** 938–943.
31. Nonaka S, Yoshiba S, Watanabe D, Ikeuchi S, Goto T, Marshall WF, et al. De novo formation of left-right asymmetry by posterior

tilt of nodal cilia. *PLoS Biol* 2005; **3:** e268.
32. Basu B, Brueckner M. Cilia multifunctional organelles at the center of vertebrate left-right asymmetry. *Curr Top Dev Biol* 2008; **85:** 151–174.
33. Tanaka Y, Okada Y, Hirokawa N. FGF-induced vesicular release of Sonic hedgehog and retinoic acid in leftward nodal flow is critical for left-right determination. *Nature* 2005; **435:** 172–177.
34. Nonaka S, Shiratori H, Saijoh Y, Hamada H. Determination of left-right patterning of the mouse embryo by artificial nodal flow. *Nature* 2002; **418:** 96–99.
35. Essner JJ, Vogan KJ, Wagner MK, Tabin CJ, Yost HJ, Brueckner M. Conserved function for embryonic nodal cilia. *Nature* 2002; **418:** 37–38.
36. Marszalek JR, Ruiz-Lozano P, Roberts E, Chien KR, Goldstein LS. Situs inversus and embryonic ciliary morphogenesis defects in mouse mutants lacking the KIF3A subunit of kinesin-II. *Proc Natl Acad Sci USA* 1999; **96:** 5043–5048.
37. Takeda S, Yonekawa Y, Tanaka Y, Okada Y, Nonaka S, Hirokawa N. Left-right asymmetry and kinesin superfamily protein KIF3A: New insights in determination of laterality and mesoderm induction by kif3A–/– mice analysis. *J Cell Biol* 1999; **145:** 825–836.
38. Mitchison HM, Schmidts M, Loges NT, Freshour J, Dritsoula A, Hirst RA, et al. Mutations in axonemal dynein assembly factor DNAAF3 cause primary ciliary dyskinesia. *Nat Genet* 2012; **44:** 381–389, S1–S2.
39. Alten L, Schuster-Gossler K, Beckers A, Groos S, Ulmer B, Hegermann J, et al. Differential regulation of node formation, nodal ciliogenesis and cilia positioning by Noto and Foxj1. *Development* 2012; **139:** 1276–1284.
40. Krebs LT, Iwai N, Nonaka S, Welsh IC, Lan Y, Jiang R, et al. Notch signaling regulates left-right asymmetry determination by inducing Nodal expression. *Genes Dev* 2003; **17:** 1207–1212.
41. Hadjantonakis AK, Pisano E, Papaioannou VE. Tbx6 regulates left/right patterning in mouse embryos through effects on nodal cilia and perinodal signaling. *PLoS One* 2008; **3:** e2511.
42. Gebbia M, Ferrero GB, Pilia G, Bassi MT, Aylsworth A, Penman-Splitt M, et al. X-linked situs abnormalities result from mutations in ZIC3. *Nat Genet* 1997; **17:** 305–308.
43. Bedard JE, Haaning AM, Ware SM. Identification of a novel ZIC3 isoform and mutation screening in patients with heterotaxy and congenital heart disease. *PLoS One* 2011; **6:** e23755.
44. Zhu L, Harutyunyan KG, Peng JL, Wang J, Schwartz RJ, Belmont JW. Identification of a novel role of ZIC3 in regulating cardiac development. *Hum Mol Genet* 2007; **16:** 1649–1660.
45. Takeuchi JK, Lickert H, Bisgrove BW, Sun X, Yamamoto M, Chawengsaksophak K, et al. Baf60c is a nuclear Notch signaling component required for the establishment of left-right asymmetry. *Proc Natl Acad Sci USA* 2007; **104:** 846–851.
46. Oki S, Kitajima K, Marques S, Belo JA, Yokoyama T, Hamada H, et al. Reversal of left-right asymmetry induced by aberrant Nodal signaling in the node of mouse embryos. *Development* 2009; **136:** 3917–3925.
47. Larkins CE, Bushey Long A, Caspary T. Defective Nodal and Cerl2 expression in the Arl13b (hnn) mutant node underlie its heterotaxia. *Dev Biol* 2012; **367:** 15–24.
48. Rankin CT, Bunton T, Lawler AM, Lee SJ. Regulation of left-right patterning in mice by growth/differentiation factor-1. *Nat Genet* 2000; **24:** 262–265.
49. Tanaka C, Sakuma R, Nakamura T, Hamada H, Saijoh Y. Long-range action of Nodal requires interaction with GDF1. *Genes Dev* 2007; **21:** 3272–3282.
50. Meno C, Saijoh Y, Fujii H, Ikeda M, Yokoyama T, Yokoyama M, et al. Left-right asymmetric expression of the TGF beta-family member lefty in mouse embryos. *Nature* 1996; **381:** 151–155.
51. Meno C, Shimono A, Saijoh Y, Yashiro K, Mochida K, Ohishi S, et al. lefty-1 is required for left-right determination as a regulator of lefty-2 and nodal. *Cell* 1998; **94:** 287–297.
52. Mine N, Anderson RM, Klingensmith J. BMP antagonism is required in both the node and lateral plate mesoderm for mammalian left-right axis establishment. *Development* 2008; **135:** 2425–2434.
53. Furtado MB, Solloway MJ, Jones VJ, Costa MW, Biben C, Wolstein O, et al. BMP/SMAD1 signaling sets a threshold for the left/right pathway in lateral plate mesoderm and limits availability of SMAD4. *Genes Dev* 2008; **22:** 3037–3049.
54. Schier AF. Nodal signaling in vertebrate development. *Annu Rev Cell Dev Biol* 2003; **19:** 589–621.
55. Chen C, Shen MM. Two modes by which Lefty proteins inhibit nodal signaling. *Curr Biol* 2004; **14:** 618–624.
56. Bamford RN, Roessler E, Burdine RD, Saplakoğlu U, dela Cruz J, Splitt M, et al. Loss-of-function mutations in the EGF-CFC gene CFC1 are associated with human left-right laterality defects. *Nat Genet* 2000; **26:** 365–369.
57. Martin JF, Amendt BA, Brown NA. *In*: Rosenthal N, Harvey RP, editors. Heart development and regeneration. Vol 1. London: Academic Press, 307–322.
58. Franco D, Campione M. The role of Pitx2 during cardiac development. Linking left-right signaling and congenital heart diseases. *Trends Cardiovasc Med* 2003; **13:** 157–163.
59. Kitamura K, Miura H, Miyagawa-Tomita S, Yanazawa M, Katoh-Fukui Y, Suzuki R, et al. Mouse Pitx2 deficiency leads to anomalies of the ventral body wall, heart, extra- and periocular mesoderm and right pulmonary isomerism. *Development* 1999; **126:** 5749–5758.
60. Chinchilla A, Daimi H, Lozano-Velasco E, Dominguez JN, Caballero R, Delpón E, et al. PITX2 insufficiency leads to atrial electrical and structural remodeling linked to arrhythmogenesis. *Circ Cardiovasc Genet* 2011; **4:** 269–279.
61. Bamforth SD, Bragança J, Farthing CR, Schneider JE, Broadbent C, Michell AC, et al. Cited2 controls left-right patterning and heart development through a Nodal-Pitx2c pathway. *Nat Genet* 2004; **36:** 1189–1196.
62. Lopes Floro K, Artap ST, Preis JI, Fatkin D, Chapman G, Furtado MB, et al. Loss of Cited2 causes congenital heart disease by perturbing left-right patterning of the body axis. *Hum Mol Genet* 2011; **20:** 1097–1110.
63. Weninger WJ, Lopes Floro K, Bennett MB, Withington SL, Preis JI, Barbera JP, et al. Cited2 is required both for heart morphogenesis and establishment of the left-right axis in mouse development. *Development* 2005; **132:** 1337–1348.
64. Mohapatra B, Casey B, Li H, Ho-Dawson T, Smith L, Fernbach SD, et al. Identification and functional characterization of NODAL rare variants in heterotaxy and isolated cardiovascular malformations. *Am J Hum Genet* 2007; **81:** 987–994.
65. Kaasinen E, Aittomäki K, Eronen M, Vahteristo P, Karhu A, Mecklin JP, et al. Recessively inherited right atrial isomerism caused by mutations in growth/differentiation factor 1 (GDF1). *Hum Mol Genet* 2010; **19:** 2747–2753.
66. Kosaki R, Gebbia M, Kosaki K, Lewin M, Bowers P, Towbin JA, et al. Left-right axis malformations associated with mutations in ACVR2B, the gene for human activin receptor type IIB. *Am J Med Genet* 1999; **82:** 70–76.
67. Kosaki K, Bassi MT, Kosaki R, Lewin M, Belmont J, Schauer G, et al. Characterization and mutation analysis of human LEFTY A and LEFTY B, homologues of murine genes implicated in left-right axis development. *Am J Hum Genet* 1999; **64:** 712–721.
68. Kim SJ. Heterotaxy syndrome. *Korean Circ J* 2011; **41:** 227–231.
69. Freedom RM, Jaeggi ET, Lim JS, Anderson RH. Hearts with isomerism of the right atrial appendages: One of the worst forms of disease in 2005. *Cardiol Young* 2005; **15:** 554–567.
70. Hutter D, Redington AN. The principles of management, and outcomes for patients with functionally univentricular hearts. *In*: Anderson RH, Baker EJ, Penny DJ, Redington AN, Rigby ML, Wernovsky G, editors. Paediatric cardiology, 3rd edn. Philadelphia: Churchill Livingstone, 2009; 687–696.
71. Yanagawa B, Alghamdi AA, Dragulescu A, Viola N, Al-Radi OO, Mertens LL, et al. Primary sutureless repair for "simple" total anomalous pulmonary venous connection: Midterm results in a single institution. *J Thorac Cardiovasc Surg* 2011; **141:** 1346–1354.
72. de Leval MR, Kilner P, Gewillig M, Bull C. Total cavopulmonary connection: A logical alternative to atriopulmonary connection for complex Fontan operations: Experimental studies and early clinical experience. *J Thorac Cardiovasc Surg* 1988; **96:** 682–695.
73. Salvin JW, Scheurer MA, Laussen PC, Mayer JE Jr, Del Nido PJ, Pigula FA, et al. Factors associated with prolonged recovery after the fontan operation. *Circulation* 2008; **118**(Suppl)**:** S171–S176.
74. Hosein RB, Clarke AJ, McGuirk SP, Griselli M, Stumper O, De Giovanni JV, et al. Factors influencing early and late outcome following the Fontan procedure in the current era: The 'Two Commandments'? *Eur J Cardiothorac Surg* 2007; **31:** 344–352.
75. Lee TM, Aiyagari R, Hirsch JC, Ohye RG, Bove EL, Devaney EJ. Risk factor analysis for second-stage palliation of single ventricle anatomy. *Ann Thorac Surg* 2012; **93:** 614–618.
76. Ichikawa H, Yagihara T, Kishimoto H, Isobe F, Yamamoto F, Nishigaki K, et al. Extent of aortopulmonary collateral blood flow as a risk factor for Fontan operations. *Ann Thorac Surg* 1995; **59:** 433–437.
77. Ota N, Fujimoto Y, Murata M, Tosaka Y, Ide Y, Tachi M, et al. Improving outcomes of the surgical management of right atrial isomerism. *Ann Thorac Surg* 2012; **93:** 832–838.
78. Ichikawa H, Sawa Y, Fukushima N, Ishizaka T, Iwai S, Kondo H, et al. Late assessment after biventricular repair for isomerism heart.

Ann Thorac Surg 2005; **80:** 50–55.
79. Eronen MP, Aittomäki KA, Kajantie EO, Sairanen HI. Outcome of left atrial isomerism at a single institution. *Pediatr Cardiol* 2012; **33:** 596–600.
80. Delmo Walter EM, Ewert P, Hetzer R, Hübler M, Alexi-Meskishvili V, Lange P, et al. Biventricular repair in children with complete atrioventricular septal defect and a small left ventricle. *Eur J Cardiothorac Surg* 2008; **33:** 40–47.
81. Uemura H, Yagihara T, Hattori R, Kawahira Y, Tsukano S, Watanabe K. Redirection of hepatic venous drainage after total cavopulmonary shunt in left isomerism. *Ann Thorac Surg* 1999; **68:** 1731–1735.
82. Kobayashi D, Edwards HD, Singh J, Nadkarni MD, Lantz PE, Cook AL. Portopulmonary hypertension secondary to congenital extrahepatic portosystemic shunt with heterotaxy and polysplenia: A cause of sudden death in an infant. *Pediatr Pulmonol* 2011; **46:** 1041–1044.
83. Serraf A, Bensari N, Houyel L, Capderou A, Roussin R, Lebret E, et al. Surgical management of congenital heart defects associated with heterotaxy syndrome. *Eur J Cardiothorac Surg* 2010; **38:** 721–727.
84. Driscoll DJ. Long-term results of the Fontan operation. *Pediatr Cardiol* 2007; **28:** 438–442.
85. Goldberg DJ, Shaddy RE, Ravishankar C, Rychik J. The failing Fontan: Etiology, diagnosis and management. *Expert Rev Cardiovasc Ther* 2011; **9:** 785–793.
86. Khairy P, Fernandes SM, Mayer JE Jr, Triedman JK, Walsh EP, Lock JE, et al. Long-term survival, modes of death, and predictors of mortality in patients with Fontan surgery: Usefulness of heparin therapy in protein-losing enteropathy associated with single ventricle palliation. *Circulation* 2008; **117:** 85–92.
87. Ghaferi AA, Hutchins GM. Progression of liver pathology in patients undergoing the Fontan procedure: Chronic passive congestion, cardiac cirrhosis, hepatic adenoma, and hepatocellular carcinoma. *J Thorac Cardiovasc Surg* 2005; **129:** 1348–1352.
88. Ohuchi H, Miyamoto Y, Yamamoto M, Ishihara H, Takata H, Miyazaki A, et al. High prevalence of abnormal glucose metabolism in young adult patients with complex congenital heart disease. *Am Heart J* 2009; **158:** 30–39.
89. Drenthen W, Pieper PG, Roos-Hesselink JW, van Lottum WA, Voors AA, Mulder BJ, et al; ZAHARA Investigators. Pregnancy and delivery in women after Fontan palliation. *Heart* 2006; **92:** 1290–1294.
90. Canobbio MM, Mair DD, van der Velde M, Koos BJ. Pregnancy outcomes after the Fontan repair. *J Am Coll Cardiol* 1996; **28:** 763–767.
91. Rychik J. Protein-losing enteropathy after Fontan operation. *Congenit Heart Dis* 2007; **2:** 288–300.
92. Ostrow AM, Freeze H, Rychik J. Protein-losing enteropathy after fontan operation: Investigations into possible pathophysiologic mechanisms. *Ann Thorac Surg* 2006; **82:** 695–700.
93. Hoashi T, Ichikawa H, Ueno T, Kogaki S, Sawa Y. Steroid pulse therapy for protein-losing enteropathy after the Fontan operation. *Congenit Heart Dis* 2009; **4:** 284–287.
94. Uzun O, Wong JK, Bhole V, Stumper O. Resolution of protein-losing enteropathy and normalization of mesenteric Doppler flow with sildenafil after Fontan. *Ann Thorac Surg* 2006; **82:** e39–e40.
95. Vyas H, Driscoll DJ, Cabalka AK, Cetta F, Hagler DJ. Results of transcatheter Fontan fenestration to treat protein losing enteropathy. *Catheter Cardiovasc Interv* 2007; **69:** 584–589.
96. John AS, Driscoll DJ, Warnes CA, Phillips SD, Cetta F. The use of oral budesonide in adolescents and adults with protein-losing enteropathy after the Fontan operation. *Ann Thorac Surg* 2011; **92:** 1451–1456.
97. Thacker D, Patel A, Dodds K, Goldberg DJ, Semeao E, Rychik J. Use of oral budesonide in the management of protein-losing enteropathy after the Fontan operation. *Ann Thorac Surg* 2010; **89:** 837–842.
98. Kanter KR, Mahle WT, Vincent RN, Berg AM, Kogon BE, Kirshbom PM. Heart transplantation in children with a Fontan procedure. *Ann Thorac Surg* 2011; **91:** 823–829.
99. Davies RR, Sorabella RA, Yang J, Mosca RS, Chen JM, Quaegebeur JM. Outcomes after transplantation for "failed" Fontan: A single-institution experience. *J Thorac Cardiovasc Surg* 2012; **143:** 1183–1192.e4.
100. Abrams DJ, Earley MJ, Sporton SC, Kistler PM, Gatzoulis MA, Mullen MJ, et al. Comparison of noncontact and electroanatomic mapping to identify scar and arrhythmia late after the Fontan procedure. *Circulation* 2007; **115:** 1738–1746.
101. Deal BJ, Mavroudis C, Backer CL. Arrhythmia management in the Fontan patient. *Pediatr Cardiol* 2007; **28:** 448–456.
102. Mavroudis C, Deal BJ, Backer CL, Stewart RD, Franklin WH, Tsao S, et al. J. Maxwell Chamberlain Memorial Paper for congenital heart surgery: 111 Fontan conversions with arrhythmia surgery: Surgical lessons and outcomes. *Ann Thorac Surg* 2007; **84:** 1457–1465.
103. Bassareo PP, Tumbarello R, Piras A, Mercuro G. Evaluation of regional myocardial function by Doppler tissue imaging in univentricular heart after successful Fontan repair. *Echocardiography* 2010; **27:** 702–708.
104. Garofalo CA, Cabreriza SE, Quinn TA, Weinberg AD, Printz BF, Hsu DT, et al. Ventricular diastolic stiffness predicts perioperative morbidity and duration of pleural effusions after the Fontan operation. *Circulation* 2006; **114**(Suppl)**:** I56–I61.
105. Hsu DT, Zak V, Mahony L, Sleeper LA, Atz AM, Levine JC, et al; Pediatric Heart Network Investigators. Enalapril in infants with single ventricle: Results of a multicenter randomized trial. *Circulation* 2010; **122:** 333–340.
106. Ishibashi N, Park IS, Takahashi Y, Nishiyama M, Murakami Y, Mori K, et al. Effectiveness of carvedilol for congestive heart failure that developed long after modified Fontan operation. *Pediatr Cardiol* 2006; **27:** 473–475.
107. Kiesewetter CH, Sheron N, Vettukattill JJ, Hacking N, Stedman B, Millward-Sadler H, et al. Hepatic changes in the failing Fontan circulation. *Heart* 2007; **93:** 579–584.
108. Kendall TJ, Stedman B, Hacking N, Haw M, Vettukattill JJ, Salmon AP, et al. Hepatic fibrosis and cirrhosis in the Fontan circulation: A detailed morphological study. *J Clin Pathol* 2008; **61:** 504–508.
109. Schwartz MC, Sullivan L, Cohen MS, Russo P, John AS, Guo R, et al. Hepatic pathology may develop before the Fontan operation in children with functional single ventricle: An autopsy study. *J Thorac Cardiovasc Surg* 2012; **143:** 904–909.
110. Ghaferi AA, Hutchins GM. Progression of liver pathology in patients undergoing the Fontan procedure: Chronic passive congestion, cardiac cirrhosis, hepatic adenoma, and hepatocellular carcinoma. *J Thorac Cardiovasc Surg* 2005; **129:** 1348–1352.
111. Mavroudis C, Backer CL, Deal BJ. Late reoperations for Fontan patients: State of the art invited review. *Eur J Cardiothorac Surg* 2008; **34:** 1034–1040.
112. Backer CL, Tsao S, Deal BJ, Mavroudis C. Maze procedure in single ventricle patients. *Semin Thorac Cardiovasc Surg Pediatr Card Surg Annu* 2008; **11:** 44–48.
113. Gamba A, Merlo M, Fiocchi R, Terzi A, Mammana C, Sebastiani R, et al. Heart transplantation in patients with previous Fontan operations. *J Thorac Cardiovasc Surg* 2004; **127:** 555–562.