

# Practical Management of ECPELLA

Makiko Nakamura,<sup>1</sup> MD and Teruhiko Imamura,<sup>1</sup> MD

## Summary

Veno-arterial extracorporeal membrane oxygenation (ECMO) is a strong mechanical circulatory device for patients with hemodynamic deterioration due to cardiogenic shock, but its drawback is an increase in left ventricular afterload. The Impella axial-flow transcatheter left ventricular assist device is a recently developed promising device to mechanically unload the left ventricle, although its support flow may not necessarily be sufficient to support shock vital. Recently, ECMO and concomitant Impella support (ECPELLA) is increasingly being used to treat cardiogenic shock by maintaining systemic circulation and unloading the left ventricle. There are several pitfalls to maintaining ECPELLA, and one useful tool is the pulmonary artery pulsatility index. The clinical advantages of ECPELLA compared to conventional ECMO alone should be demonstrated in larger scale studies in the near future.

(Int Heart J 2020; 61: 1094-1096)

**Key words:** Heart failure, Hemodynamics, Unloading

**I**mpella (Abiomed, Danvers, MA, USA), a percutaneous catheter-based transvalvular left ventricular (LV) assist device, directly reduces left ventricular preload and increases systemic flow, and results in a decrease in pulmonary artery wedge pressure and improvements in systemic perfusion (Figure 1).

In cases of ventricular tachycardia/ventricular fibrillation, right ventricular failure, pulmonary congestion or severe hypoxia, severe acidosis with an elevated lactate level, or the need for right ventricle (RV) support and oxygenation supply with gas exchange, veno-arterial extracorporeal membrane oxygenation (VA-ECMO) is concomitantly used together with Impella (i.e., ECPELLA; Figure 2).

VA-ECMO is superior to the Impella with respect to the recovery of end-organ dysfunction and RV failure, whereas it increases systemic afterload, LV filling pressures, and pulmonary artery wedge pressure due to the blood return to the central artery. In cases with cardiogenic shock, who are in INTERMACS profile 1, i.e., critical cardiogenic shock, we introduce VA-ECMO first, followed by concomitant Impella support for left ventricular unloading if pulmonary congestion or LV dysfunction exists. The increased systemic afterload and cardiac filling pressure can be reduced by concomitant use of Impella.<sup>1)</sup> Alternatively, there are also cases with broad ST-elevation myocardial infarction or acute myocarditis who are initiated with Impella at first, however, they subsequently required VA-ECMO insertion for progressive end-organ damage or right ventricular failure.<sup>2)</sup>

As described above, VA-ECMO and Impella can mutually support the disadvantage of the other therapy. Re-

cently, various favorable clinical outcomes of ECPELLA support have been reported.<sup>1)</sup> Some studies reported that the use of ECPELLA was associated with a higher weaning rate from VA-ECMO and bridging to a durable ventricular assist device or cardiac transplant.<sup>3,4)</sup> However, the management of ECPELLA in real-world practice might not be well-reviewed thus far. In this review article, we will introduce up-to-date practical management of ECPELLA.

## Access Site of ECPELLA

In patients with cardiogenic shock with INTERMACS Profile 1, the ECMO cannula and Impella catheter are inserted via the bilateral femoral arteries in most cases. In cases with severe peripheral vascular disease, hostile femoral access due to infection, indwelling endovascular devices or obesity, post-cardiac surgery, or having prospects for long support and need for providing mobility and ambulation, the axillary approach or ascending aorta (central) approach can be considered for ECMO therapy.<sup>5,6)</sup> In a similar situation, a subclavian artery approach is sometimes preferred for Impella therapy.

## Management of ECPELLA

ECMO flow should be maintained at a sufficient level (or rather increased if necessary) until the systemic circulatory failure and hypoxia improve with the following targets: (1) target mean blood pressure > 70 mmHg, (2) mixed venous oxygen saturation (SvO<sub>2</sub>) > 60% (preferably > 65%), and (3) a decreasing trend in the serum lactate

From the <sup>1</sup>Second Department of Internal Medicine, University of Toyama, Toyama, Japan.

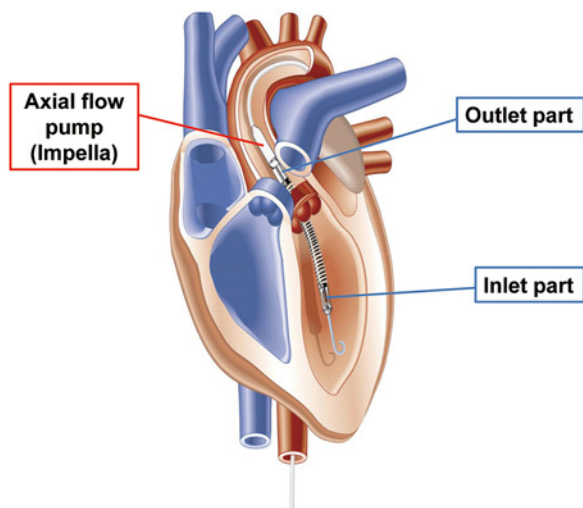
Address for correspondence: Teruhiko Imamura, MD, Second Department of Internal Medicine, Toyama University, 2630 Sugitani, Toyama, Toyama 930-0194, Japan. E-mail: teimamu@med.u-toyama.ac.jp

Received for publication March 9, 2020. Revised and accepted July 20, 2020.

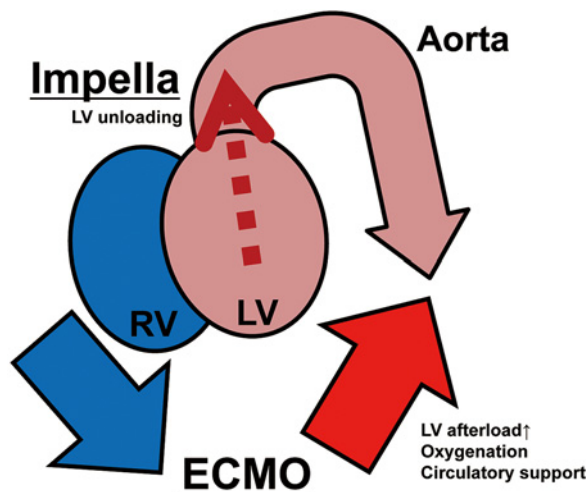
Released in advance online on J-STAGE October 28, 2020.

doi: 10.1536/ihj.20-172

All rights reserved by the International Heart Journal Association.



**Figure 1.** Schema of Impella axial-flow transcatheter left ventricular assist device. Blood is removed from the inlet part located in the left ventricle and returned into the aorta from the outlet part located in the ascending aorta to achieve left ventricular unloading and circulatory support. Reused from Lee, *et al.* with a permission.<sup>7)</sup>



**Figure 2.** Schema of ECMO and Impella system (ECPPELLA). ECMO removes deoxygenated blood from a central vein (or RV) and returns oxygenated blood into the central aorta, which in return increases LV afterload and suppresses LV unloading. Impella is inserted through aortic valve to unload LV. ECMO indicates extracorporeal membrane oxygenation; LV, left ventricle; and RV, right ventricle.

level.

Systemic arterial pressure is dominantly determined by the ECMO support flow level, and the ECMO flow should be increased if hypotension persists. If the blood removing catheter (usually located in the central vein) is too small or hypovolemia persists, increasing the rotation speed alone would cause hemolysis and would not increase the support flow. A volume supplement or size up of the removing catheter is highly recommended for such a situation.

In cases with advanced pulmonary congestion and pulmonary oxygenation disorders, a veno-arterio-venous ECMO system, which removes blood from a central vein and returns the oxygenated blood into both a central vein and the aorta, is preferable to the VA-ECMO system to prevent the hypoxic blood from being propelled into the aortic root and coronary artery via the Impella.<sup>7)</sup>

### Weaning of ECMO System

The Impella support level (rotation speed) is initiated at P-2 (minimum level), as an LV venting. When the mean pulmonary artery pressure or pulmonary artery wedge pressure remains elevated, we raise the Impella P-level or adjust the volume status if necessary using diuretics to achieve optimal hemodynamics.

Given the improvement of end-organ dysfunction and oxygenation, a reduction of ECMO support flow in addition to the incremental support level of Impella is attempted (ECMO weaning). When the flow balance between ECMO and Impella is inappropriate, the Impella suction alarm, hemolysis, or ventricular arrhythmia due to LV sucking would occur.<sup>8)</sup> The flow balance should be carefully monitored using echocardiography and right heart catheter data.

Withdrawal of ECMO should be within one week, at

the latest within two weeks, because comorbidities during longer-term ECMO support, such as infection, hemorrhage, and limb ischemia, are often fatal. In patients with Impella 2.5, some cases experience a decrease in arterial blood pressure and an elevation of pulmonary artery wedge pressure when weaning from ECMO. In such cases, upgrading the Impella or the administration of inotropes should be considered for additional left ventricle support.

### Assessment of RV Function

When RV failure exists, it is often challenging to achieve incremental Impella flow and the weaning of ECMO. Tricuspid annular plane systolic excursion and RV fractional area change in echocardiography are useful indices for estimating RV function. Of note, we often encounter patients with ECPPELLA supports in whom an apical 4-chamber view cannot be visualized due to multiple devices and limited position.

The pulmonary artery pulsatility index (PAPi) (systolic pulmonary artery pressure - diastolic pulmonary artery pressure) / (right atrial pressure), is one of the indices of RV function and might be a useful tool.<sup>9)</sup> When PAPi is low (for example, under 0.9), an additional approach to manage RV failure should be considered, including the administration of inotropes to achieve ECMO weaning.<sup>2)</sup> The central venous pressure/pulmonary artery wedge pressure ratio is another parameter with which to assess RV function, although it is sometimes challenging to blindly measure pulmonary artery wedge pressure in an intensive care setting.

### Post-Weaning from ECMO

When the hemodynamics of a patient remain rela-

tively stable even after the withdrawal of ECMO support, the weaning of Impella is the next concern. If hemodynamic stability is completely dependent on the Impella support, the next strategies are device upgrade from an Impella 2.5/CP to Impella 5.0 or a bridge to a durable left ventricular assist device, taking into consideration the background and comorbidities of the patient.

### Disclosure

**Conflicts of interest:** None.

### References

1. Tschope C, Van Linthout S, Klein O, *et al.* Mechanical Unloading by Fulminant Myocarditis: LV-IMPELLA, ECMELLA, BIPELLA, and PROPELLA Concepts. *J Cardiovasc Transl Res* 2019; 12: 116-23.
2. Nakamura M, Imamura T, Ueno H, Kinugawa K. Current indication and practical management of percutaneous left ventricular assist device support therapy in Japan. *J Cardiol* 2020; 75: 228-32.
3. Vallabhajosyula S, O'Horo JC, Antharam P, *et al.* Venoarterial Extracorporeal Membrane Oxygenation With Concomitant Impella Versus Venoarterial Extracorporeal Membrane Oxygenation for Cardiogenic Shock. *ASAIO J* 2020; 66: 497-503.
4. Bertoldi LF, Pappalardo F, Lubos E, *et al.* Bridging INTERMACS 1 patients from VA-ECMO to LVAD via Impella 5.0: De-escalate and ambulate. *J Crit Care* 2020; 57: 259-63.
5. Tayal R, Hirst CS, Garg A, Kapur NK. Deployment of acute mechanical circulatory support devices via the axillary artery. *Expert Rev Cardiovasc Ther* 2019; 17: 353-60.
6. Hysi I, Renaut C, Fabre O. Direct axillary artery cannulation in cardiac surgery: clinical outcomes. *Asian Cardiovasc Thorac Ann* 2017; 25: 502-3.
7. Lee SI, Hwang HJ, Lee SY, *et al.* Veno-veno-arterial extracorporeal membrane oxygenation for acute respiratory distress syndrome with septic-induced cardiomyopathy due to severe pulmonary tuberculosis. *J Artif Organs* 2017; 20: 359-64.
8. Au SY, Fong KM, Ng WY, So SO, Leung KH. Interaction between VA-ECMO and Impella. *J Echocardiogr* 2019 (in press).
9. Kochav SM, Flores RJ, Truby LK, Topkara VK. Prognostic Impact of Pulmonary Artery Pulsatility Index (PAPi) in Patients With Advanced Heart Failure: Insights From the ESCAPE Trial. *J Card Fail* 2018; 24: 453-9.