INTERNAL MEDICINE

□ CASE REPORT □

Adult Patient with Epstein-Barr Virus (EBV)-Associated Lymphoproliferative Disorder: Chronic Active EBV Infection or de novo Extranodal Natural Killer (NK)/T-cell Lymphoma, Nasal Type?

Rie Ohtsuka[1], Yasunobu Abe[1], Eriko Sada[1], Junichi Kiyasu[1], Akiyo Ashikari[1], Motoaki Shiratsuchi[1], Junji Nishimura[2], Ryoichi Takayanagi[1] and Koichi Ohshima[3]

Abstract

Chronic active Epstein-Barr virus (EBV) infection, which is considered to be a childhood disease, often develops into natural killer (NK) or T-cell lymphoma after recurrent infectious mononucleosis (IM)-like symptoms. We describe a 56-year-old woman who developed NK-cell lymphoma after 9 months of recurrent IM-like symptoms. The patient had an unusual anti-EBV antibody profile. Increased levels of EBV genome were detected in the liver and peripheral blood. Several chemotherapy regimens were ineffective, and the patient died of progression of lymphoma. Certain subtypes of NK-cell lymphoma showing a long-lasting prodrome related to chronic EBV infection may exist.

Key words: chronic active Epstein-Barr virus infection, extranodal NK/T-cell lymphoma, nasal type, adult patient

(Inter Med 48: 471-474, 2009)
(DOI: 10.2169/internalmedicine.48.1346)

Introduction

Epstein-Barr virus (EBV) infection generally arises during childhood, and sometimes leads to infectious mononucleosis (IM), when it occurs in young adults. IM is a benign self-limiting disease characterized by cytotoxic T-cell proliferation against EBV-infected B cells. EBV can also infect T and natural killer (NK) cells, but persistent infection is uncommon. When it occurs, however, persistent infection causes chronic active EBV infection (CAEBV) characterized by chronic or recurrent IM-like symptoms such as low grade fever, liver dysfunction and lymphadenopathy (1). This rare disease is more prevalent in East Asian countries and has a poor prognosis.

Proposed guidelines for diagnosing CAEBV include (2) persistent or recurrent IM-like symptoms, unusual anti-EBV antibody profile with increased levels of anti-viral capsid antigen (VCA) and anti-early antigen (EA), detection of increased levels of EBV genome in affected tissues, including the peripheral blood, and chronic illness that cannot be explained by other known disease processes at diagnosis. CAEBV has been considered to be a disease of children and young adults, therefore CAEBV in older groups is poorly understood. We describe herein an elderly woman who developed NK-cell lymphoma after recurrent IM-like symptoms and discuss the relationship with CAEBV.

Case Report

In February 2002, a 56-year-old Japanese woman began suffering repeated symptoms, such as fever, fatigue and right upper abdominal pain. At the time of onset, there were no findings of liver dysfunction and peripheral blood cell counts were normal. Elevated levels of serum aspartate aminotransferase (AST) and alanine aminotransferase (ALT)

[1]Department of Medicine and Bioregulatory Science, Graduate School of Medical Sciences, Kyushu University, Fukuoka, [2]Department of Clinical Immunology, Medical Institute of Bioregulation, Kyushu University, Fukuoka and [3]Department of Pathology, School of Medicine, Kurume University, Fukuoka
Received for publication May 25, 2008; Accepted for publication December 3, 2008
Correspondence to Dr. Yasunobu Abe, abey@intmed3.med.kyushu-u.ac.jp

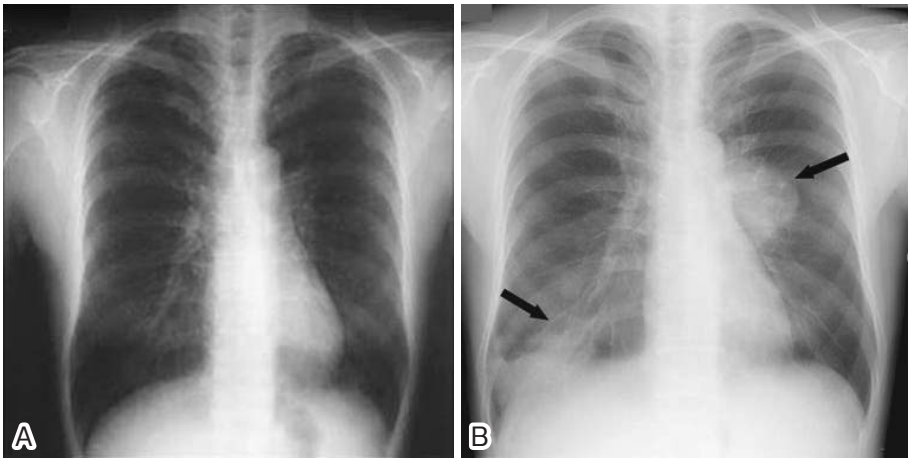

Figure 1. Chest X ray findings. Findings are normal in February 2002 (A); bilateral lung masses in November 2002 (B).

were documented in April, and increased to 631 IU/L and 578 IU/L, respectively, in July. Concurrently, progressive pancytopenia was presented; hemoglobin level was 9.7 g/dL, white blood cell count was 1.88 × 10^9/L including 70% lymphocytes with a few (1%) atypical lymphocytes, and platelet count was 40 × 10^9/L. Enzyme-linked immunosorbent assay (ELISA) revealed that she was positive for anti-VCA IgG and anti-EA IgG. These anti-EBV antibodies indicated reactivation of EBV. In August, peripheral blood cell counts and serum levels of AST and ALT were recovered within normal ranges without any therapy. In November 2002, the patient complained her right chest pain and fever lasting for one week. Then, she was referred to our hospital because of bilateral lung masses initially detected by chest X-ray (Fig. 1). Upon admission, she had no enlarged surface lymph nodes, and abdominal ultrasonography revealed mild hepatosplenomegaly. Peripheral blood cell count showed mild pancytopenia; hemoglobin level was 11.2 g/dL, white blood cell count was 1.57 × 10^9/L including 32.5% lymphocytes, and platelet count was 54 × 10^9/L. The fraction of CD 3-positive cells (T cells), CD16-positive cells (NK cells) and CD20-positive cells (B cells) in peripheral blood, as determined by flow cytometry, was 67.2%, 31.6% and 3.3%, respectively. Morphologically abnormal lymphocytes such as large granular lymphocytes with irregular, hyperchromatic nuclei were not seen. Bone marrow aspiration showed normocellular bone marrow with 3.0% activated macrophages engulfing blood cells (Fig. 2B), and 11.5% lymphocytes with no atypia.

The patient also had liver dysfunction, with blood chemistry results as follows: total bilirubin, 1.1 mg/dL; AST, 817 IU/L; ALT, 777 IU/L; lactate dehydrogenase (LDH), 902 IU/L; alkaline phosphatase (ALP), 1,778 IU/L; and γ-glutamyl transpeptidase (γ-GTP), 132 IU/L. Hepatitis B virus (HBV) surface antigen and anti-Hepatitis C virus (HCV) antibody were negative. Serum levels of ferritin and soluble interleukin 2 receptor were markedly elevated to 3,063.7 ng/mL and 12,900 IU/mL, respectively. Serological tests for antibodies against EBV revealed very high titers of anti-VCA IgG (1 : 1,280) and anti-EA IgG (1 : 320), and low titers (1 : 20) for antibodies against EBV-associated nuclear antigen (EBNA). This unusual profile is similar to that of CAEBV. EBV viral load in peripheral blood CD3-positive cells and CD16-positive cells purified by using immunomagnetic beads was 1.3 × 10^3 copies/μg DNA and 1.7 × 10^4 copies/μg DNA, respectively. EBV mainly infected NK cells, although several T cells may have also harbored EBV. Because the efficacy of their purification using immunomagnetic beads was over 90%, we believe EBV predominantly infected NK cells. Southern blotting using the terminal repeat as a probe confirmed the monoclonal proliferation of EBV-infected cells in the bone marrow. There were no rearranged bands of T cell receptor β gene and immunoglobulin heavy chain gene. Liver biopsy revealed the infiltration of medium-sized lymphoid cells, which were positive for CD56 and EBV encoded RNA-1 (EBER-1) by in situ hybridization (Fig. 2C, D). On the other hand, cytology of bronchoalveolar lavage (BAL) fluid showed large atypical lymphoid cells that were positive for CD56 (Fig. 2A). Culture of BAL fluid showed no growth of bacteria and fungus. Therefore, extranodal NK-cell lymphoma was diagnosed. Lung nodules shrank transiently after CHOP (cyclophosphamide, doxorubicin, vincristine, prednisolone) therapy; however, the duration of this response was short. Despite salvage therapy such as ESHAP (etoposide, cisplatin, high-dose cytarabine, methyl-prednisolone), bilateral pleural effusion containing cells that were positive for CD2 and CD56 developed and was further aggravated. The patient died of progressive disease 8 months after diagnosis of NK-cell lymphoma.

Discussion

CAEBV constitutes a continuous spectrum of reactive and neoplastic features ranging from polymorphic lymphoproliferative disorder (LPD) without clonal proliferation of EBV-infected cells to monomorphic LPD with clonality (5). During the clinical course of CAEBV, NK or T-cell lymphoma often develops (3-5). In the current WHO classification,

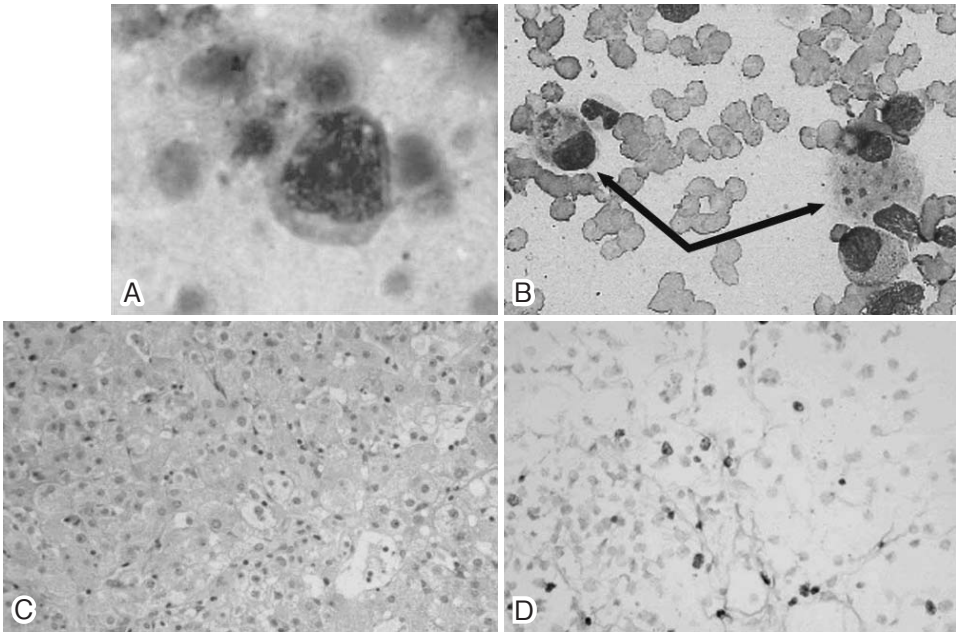

Figure 2. A: Cytology of bronchoalveolar lavage fluid showed large atypical lymphoid cells (×1000). B: Bone marrow aspiration showed 3.0% activated macrophages (arrows) engulfing the blood cells (×400). C, D: Histopathological examination of liver (×400). Hematoxylin and Eosin staining shows infiltration of medium-sized lymphoid cells (C). In situ hybridization detected EBV in lymphocytes at the same time (D).

LPD of mature NK cells is categorized into two entities; aggressive NK-cell leukemia (ANKL), and extranodal NK/T-cell lymphoma, nasal type (ENKTL) (6).

ENKTL is more prevalent in East Asian countries and mainly involves the nasopharyngeal region, skin and gastrointestinal tract. There are similarities between CAEBV and ENKTL. Proliferating cells in these disorders are positive for EBV, CD56 and cytotoxic molecules such as TIA-1. The concept of CAEBV is often confusing, and de novo ENKTL with increased levels of EBV genome in peripheral blood, which reflects tumor size, is often misdiagnosed as CAEBV. We should avoid interpreting the presence of EBV-associated lymphocytes as a hallmark of CAEBV, and clinical episodes suggestive of CAEBV prior to onset of lymphoma are important for the diagnosis of CAEBV.

Because we failed to detect neoplastic NK cells in the patient's peripheral blood, she was diagnosed to have de novo ENKTL rather than ANKL. Although her IM-like symptoms lasting 9 months were considered as the B symptoms of lymphoma patients, no apparent tumor was documented at the onset of her illness. In addition, her IM-like symptoms recurred frequently, while spontaneous regression occurred without any treatments. These findings are unlikely observed in ENKL. Furthermore, most cases of ENKTL initially involve nasopharyngeal sites or the skin. In the present case, the initial involved sites on admission were lung, liver and bone marrow. Morphollogically normal CD16-positive cells that harbored EBV were also present in peripheral blood at the time of admission. This clinical course and distribution was unusual for ENKTL, and it is difficult to diagnose this disease only by morphologic abnormalities according to WHO classification. Another possibility was that this LPD was CAEBV progressing to NK-cell lymphoma during the course of the illness. This setting may explain the reason for her IM-like symptoms lasting 9 months.

EBV-associated NK/T-cell lymphoma in adult patients might be classified into two categories, i.e., de novo lymphoma and lymphoma arising from the clinical setting of CAEBV. Indeed, the first peak of its incidence was observed in the population aged 16 to 25 years, and the second one was shown in those aged 56 to 65 years in Korea and Japan (7). Immunological deterioration as a result of the aging process might be related to the reactivation of latent EBV infection (8). Therefore, some parts of this lymphoma in older patients may be related to CAEBV.

The usefulness of this classification is uncertain, but recognizing CAEBV and measuring EBV-related antibodies or EBV load among elderly patients with chronic symptoms such as low-grade fever and liver damage may be important. Early recognition and diagnosis of CAEBV, which is a borderline condition with a high risk of evolution into aggressive NK/T-cell lymphoma, may lead to beneficial treatment strategies. Further information on EBV-associated LPD in elderly patients is necessary to establish its clinical entity.

References

1. Kimura H, Hoshino Y, Kanegane H, et al. Clinical and virologic characteristics of chronic active Epstein-Barr virus infection.

Blood **98**: 280-286, 2001.

2. Okano M, Kawa K, Kimura H, et al. Proposed guidelines for diagnosing chronic active Epstein-Barr virus infection. Am J Hematol **80**: 64-69, 2005.

3. Kanegane H, Bhatia K, Gutierrez M, et al. A syndrome of peripheral blood T-cell infection with Epstein-Barr virus (EBV) followed by EBV-positive T-cell lymphoma. Blood **91**: 2085-2091, 1998.

4. Kawa-Ha K, Ishihara S, Ninomiya T, et al. CD3-negative lymphoproliferative disease of granular lymphocytes containing Epstein-Barr viral DNA. J Clin Invest **84**: 51-55, 1989.

5. Suzuki K, Ohshima K, Karube K, et al. Clinicopathological states of Epstein-Barr virus-associated T/NK-cell lymphoproliferative disorders (severe chronic active EBV infection) of children and young adults. Int J Oncol **24**: 1165-1174, 2004.

6. Chan JKC, Jaffe ES, Ralfkiaer E. Extranodal NK/T-cell lymphoma, nasal type. In: World Health Organization Classification of Tumors. Pathology and Genetics. Tumours of Haematopoietic and Lymphoid Tissues. Jaffe ES, Harris NL, Stein H, Vardiman JW, Eds. International Agency for Research on Cancer (IARC) Press, Lyon, 2001: 204-207.

7. Ohshima K, Kimura H, Yoshino T, et al. Proposed categorization of pathological states of EBV-associated T/natural killer-cell lymphoproliferative disorder (LPD) in children and young adults: overlap with chronic active EBV infection and infantile fulminant EBV T-LPD. Pathol Int **58**: 209-217, 2008.

8. Shimoyama Y, Yamamoto K, Asano N, Oyama T, Kinoshita T, Nakamura S. Age-related Epstein-Barr virus-associated B-cell lymphoproliferative disorders: special references to lymphomas surrounding this newly recognized clinicopathologic disease. Cancer Sci **99**: 1085-1091, 2008.

© 2009 The Japanese Society of Internal Medicine
http://www.naika.or.jp/imindex.html