

[CASE REPORT]

Renal Artery Stenting Recovered Renal Function after Spontaneous Renal Artery Dissection

Yasuhiro Aoki, Yoshiaki Sakai, Takashi Kimura, Tomoki Yamaoka, Sachiko Maekawa, Junpei Maekawa, Masanori Sano, Koki Matsuno and Iwao Ishibashi

Abstract:

Spontaneous renal artery dissection (SRAD) is a rare entity and the management of this disease has not been established. A 54-year-old man presented with severe flank pain, and contrast-enhanced computed tomography images suggested SRAD in his left renal artery. After two weeks of conservative treatment, stents were placed in the renal artery. The pre- and post-procedural renal function was independently assessed by renography. After stenting, his left renal function recovered from the renal failure pattern. Renal artery stenting in an acute phase of SRAD may salvage the renal function, even if it appears to be non-functioning.

Key words: spontaneous renal artery dissection, stent, renal function, renogram

(Intern Med 58: 2191-2194, 2019)

(DOI: 10.2169/internalmedicine.2550-18)

Introduction

Only approximately 200 cases of spontaneous renal artery dissection (SRAD) have been reported in the literature. The diagnosis is often delayed due to the rarity of the disease and nonspecific clinical presentations such as flank pain, hypertension, fever, hematuria, and acute renal failure. Prior to 1980, SRAD was mostly diagnosed by autopsy and rarely by angiography. Corresponding to the development of imaging technologies such as computed tomography (CT), SRAD became more readily identifiable (1). In a recent report based on a retrospective analysis of CT imaging, SRAD was identified in 17% of patients who were previously diagnosed with acute renal infarction (2); however, the etiology of this disease has not been clarified, and the treatment and long-term management of this disease is poorly understood.

Case Report

A 54-year-old man who was previously healthy presented to a hospital complaining of severe left flank pain that had occurred intermittently for one week. Contrast-enhanced CT images showed left renal infarction. He was transferred to our hospital for further investigations and treatment. His ab-

domen was soft and flat. His blood pressure was 160/110 mmHg, and his laboratory data showed mild leukocytosis (11,900/ μ L), slight renal dysfunction (creatinine 1.1 mg/dL), and dyslipidemia (LDL-cholesterol 178 mg/dL). No proteinuria or hematuria was observed. Contrast-enhanced CT images showed low enhancement of the left kidney and intraluminal filling defects in the left renal artery. Multiplanar reconstruction images of the area orthogonal to the left renal artery showed ring-shaped filling defects in the renal artery, and a 3D CT image showed an extremely narrowed left renal artery (Fig. 1). There were no clinical signs of connective tissue disorders (e.g., Marfan syndrome or Ehlers-Danlos syndrome) and his illness was diagnosed as SRAD. An expert sonographer performed Doppler ultrasonography and the blood flow in the left renal artery was below the limit of detection. The patient was managed conservatively with antihypertensive drugs for two weeks. Within that period, we assessed the individual left and right renal function by 99m Tc-diethylene triamine penta-acetic acid (DTPA) renography. The renogram of the left kidney showed a decreased glomerular filtration rate (21.4 mL/min) and a renal failure pattern that represented only background blood activity (Fig. 2A) (3).

After obtaining informed consent, we decided to perform renal artery stenting. There are several reasons for this deci-

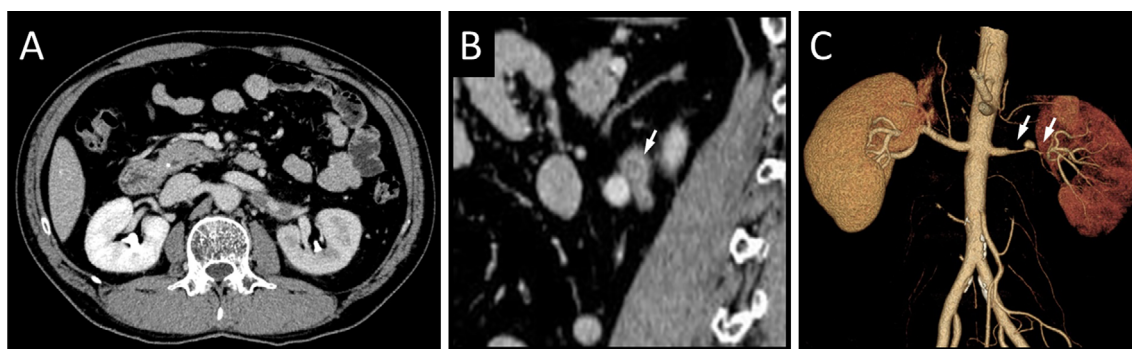


Figure 1. Low enhancement of the left kidney and intraluminal filling defects in the left renal artery (A). A ring-shaped filling defect in the left renal artery (B). An extremely narrow left renal artery (C).

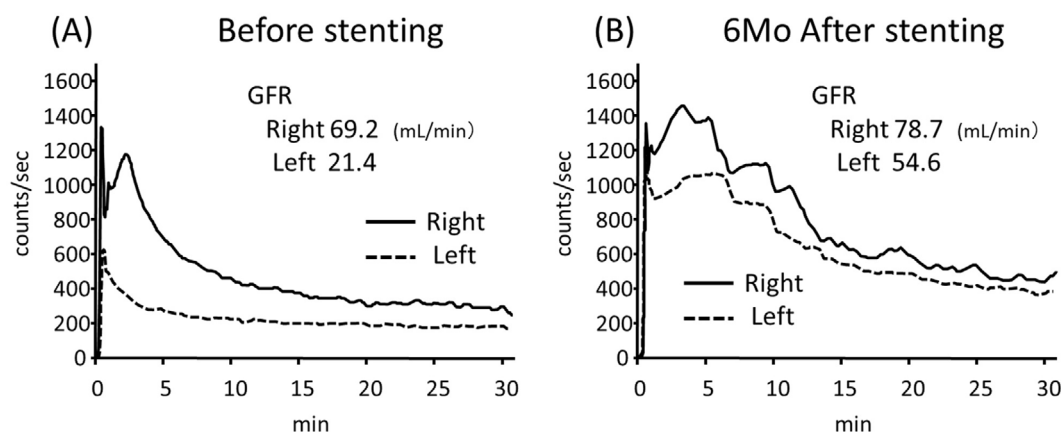


Figure 2. ^{99m}Tc -diethylene triamine penta-acetic acid renogram. Before stenting (A) and after six months (B).

sion. First, we considered that there might still be a chance to salvage the renal function while the renal artery was not completely occluded and the duration of low flow time was limited to a few weeks. Second, it might decrease the blood pressure, which might provide an opportunity to reduce or cease the administration of the patient's medicines. Lastly, stenting at the site of the lesion looked technically feasible and the vessel diameter was large enough to deploy stents. CT angiography revealed that the distal portion of the dissected area was proximal to the bifurcation and that the vessel diameter of the distal portion was 4 mm. Renal stents from 4 mm in diameter were available.

Procedure: Two antiplatelet agents, aspirin (100 mg/day) and clopidogrel (75 mg/day), were administered orally prior to stenting. From a right femoral approach, the left renal artery was cannulated with a 6F guiding catheter (Mach1, RDC1, Boston Scientific, Marlborough, USA). Then a 0.014-inch guide wire (Cruise, Asahi Intecc, Seto, Japan) was passed across the lesion, and dissection and the entry tear were confirmed by intravascular ultrasound (IVUS) (Fig. 3A). After predilatation with a 3.5×20-mm balloon, 6.0×18-mm and 4.0×19-mm balloon-expandable stents (Express Vascular SD, Boston Scientific) were deployed. The final angiogram showed the recanalization of two inferior seg-

mental arteries (Fig. 3B).

He was discharged four days after the procedure. At discharge, the patient's blood pressure had decreased to 120 mmHg with the oral administration of nifedipine (40 mg/day); his blood pressure was 140 mmHg nifedipine (80 mg/day). The patient's serum creatinine level was 1.1 mg/dL at discharge.

A renogram and a CT angiogram were obtained at a follow-up examination performed six months after intervention. The renogram curve of the left kidney showed a later and higher peak in comparison to before stenting, suggesting the emergence of renal uptake, and the glomerular filtration rate of left kidney was ameliorated to 54.6 mL/min (Fig. 2B). CT images showed no restenosis and new contrast filling at inferior pole, which was defected before stenting (Fig. 4). At this time, the patient's blood pressure was maintained at approximately 120 mmHg with nifedipine (20 mg/day), and his serum creatinine level had decreased to 0.69 mg/dL.

Discussion

There are no guidelines or established treatments for SRAD. SRAD has been managed by medical therapy (4-9),

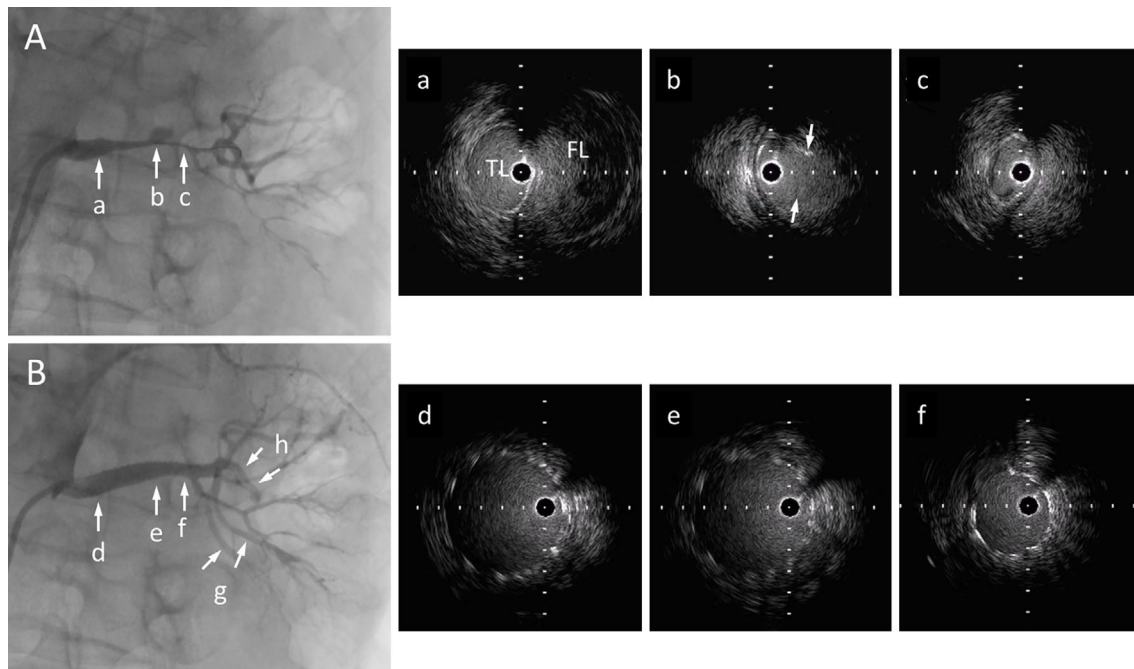


Figure 3. Pre-procedural (A) and post-procedural (B) angiography of the left renal artery. (a) - (f) Correspond to each IVUS images on the right-hand side. True and false lumen and an entry tear (arrow) were identified. Two newly enhanced inferior segmental arteries (e). Periprocedural small dissection (f). TL: true lumen, FL: false lumen

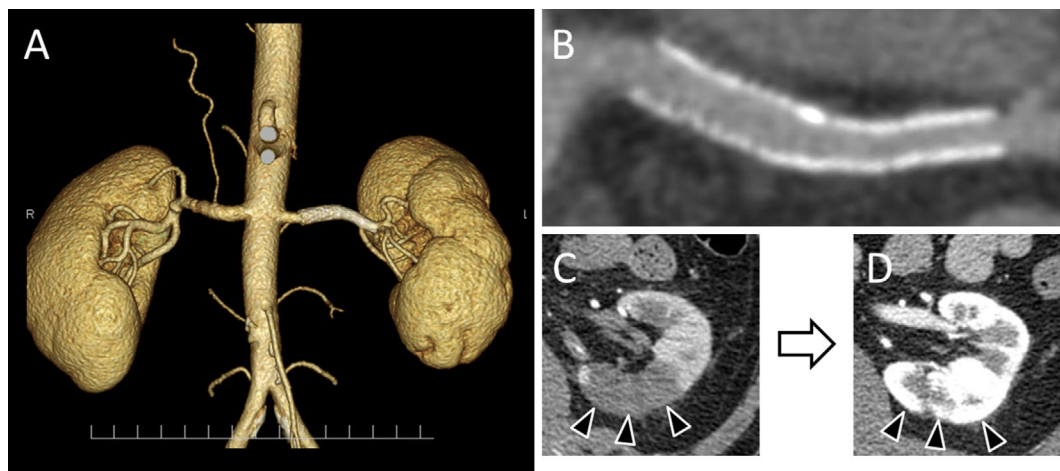


Figure 4. 3D CT angiography (A) and curved multiplanar reconstruction image of stented site (B) at six months follow-up. The contrast filling defect at the inferior pole (C) was improved after six months (D).

renal artery embolization (10), surgical revascularization, partial or complete nephrectomy (11-13), or endovascular treatment (14) with or without thrombolysis (15). Because surgical techniques are highly invasive, cases described in the recent publications were often treated conservatively or endovascularly.

Patients who showed neither uncontrollable high blood pressure nor a worsening serum creatinine level were frequently treated conservatively with antihypertensive agents if necessary, and reported no further major clinical events (4, 6). In several case reports, patients received anti-

coagulant therapy for a short or long period to avoid thromboembolic events, and in most cases, the treatment course was uneventful (5). Katz-Summercorn et al. reported the complete resolution of dissection with anticoagulant therapy (9). However, no clinical studies have compared therapies with or without anticoagulation. It might not be effective in some cases, and it might even cause negative outcomes. Ando et al. reported the case of a SRAD patient who was treated with heparin. After four months, the patient's serum creatinine level had normalized but the kidney on the diseased side became atrophic (7). In one of three cases re-

ported by Stawicki et al., the dissection progressed during anticoagulation therapy (8).

Pellerin et al. reported 16 consecutive patients with SRAD who were treated with endovascular stent placement. In this series, all patients had uncontrolled hypertension and 10 patients had progressive renal insufficiency. During the average of 8.6 years of follow up, the mean blood pressure and plasma creatinine level normalized. Images of the renal arteries showed no signs of restenosis or occlusion in any patient (14). Endovascular treatment may be considered for patients with worsening blood pressure and/or a worsening renal function.

Because kidneys are bilateral organs and each has a huge reserve capacity, unilateral SRAD would not have a heavy impact on the systemic renal function if the other side is functioning normally. Yoon et al. reported four patients with unilateral SRAD who were treated conservatively. Their estimated glomerular filtration rate (eGFR) decreased but never fell below 60 mL/min/1.73 m² (2). However, SRAD is known to emerge bilaterally in 10-15% of cases (1), as late as 7 years after the first occurrence (16). Thus, we believe that treatment of the diseased side is worthwhile-even if there is no uncontrolled hypertension or progressive renal insufficiency-if the individual renal function on the diseased side is diminished, due to the possibility of future recurrence on the other side.

Renography is a useful modality for evaluating the individual renal function. To the best of our knowledge, this is the first report to follow the individual renal function after renal artery stenting for SRAD. With this modality, we could detect insufficiency of the left kidney that might have been overlooked in a serum creatinine level analysis. Furthermore, a functional recovery was demonstrated from the renal failure pattern. Renography may provide valuable information for decision making and evaluating treatment efficacy.

We deemed that, for this particular case, the fact that the renal artery was not completely occluded and the duration of ischemic time was limited were factors that brought about a preferable result in this patient. The accumulation of further cases is necessary to clarify the patients for whom this procedure is suitable.

Conclusion

We reported a case in which SRAD was successfully treated. This case suggests that-in cases that are anatomically and technically feasible-renal artery stenting in the acute phase of SRAD may salvage the renal function, even the kidney appears to be non-functioning.

The authors state that they have no Conflict of Interest (COI).

References

1. Mansoor MS, Shafiq M. Spontaneous renal artery dissection: current perspective. *J Pak Med Assoc* **62**: 1333-1337, 2012.
2. Yoon K, Song S-Y, Lee CH, et al. Spontaneous renal artery dissection as a cause of acute renal infarction: clinical and MDCT findings. *J Korean Med Sci* **32**: 605-612, 2017.
3. Taylor AT. Radionuclides in nephrourology, part 2: pitfalls and diagnostic applications. *J Nucl Med* **55**: 786-798, 2014.
4. Beroniade V, Roy P, Froment D, Pison C. Primary renal artery dissection presentation of two cases and brief review of the literature. *Am J Nephrol* **7**: 382-389, 1987.
5. Ramamoorthy SL, Vasquez JC, Taft PM, McGinn RF, Hye RJ. Nonoperative management of acute spontaneous renal artery dissection. *Ann Vasc Surg* **16**: 157-162, 2002.
6. Misrai V, Peyromaure M, Poiree S, Marteau V, Laurian C. Spontaneous dissection of branch renal artery- Is conservative management safe and effective? *J Urol* **176**: 2125-2129, 2006.
7. Ando T, Ohno H, Hirata Y, Emoto A, Ogata S, Mimata H. Spontaneous recovery from renal infarction resulting from renal artery dissection. *Int J Urol* **12**: 405-408, 2005.
8. Stawicki SP, Rosenfeld JC, Weger N, Fields EL, Balshi JD. Spontaneous renal artery dissection: three cases and clinical algorithms. *J Hum Hypertens* **20**: 710-718, 2006.
9. Katz-Summercorn AC, Borg CM, Harris PL. Spontaneous renal artery dissection complicated by renal infarction: A case report and review of the literature. *Int J Surg Case Rep* **3**: 257-259, 2012.
10. Mudrick D, Arepally A, Geschwind J-F, Ronsiville JA, Lund GB, Scheel P. Spontaneous renal artery dissection: treatment with coil embolization. *J Vasc Interv Radiol* **14**: 497-500, 2003.
11. van Rooden CJ, van Baalen JM, van Bockel JH. Spontaneous dissection of renal artery: long-term results of extracorporeal reconstruction and autotransplantation. *J Vasc Surg* **38**: 116-122, 2003.
12. Lacombe M. Isolated spontaneous dissection of the renal artery. *J Vasc Surg* **33**: 385-391, 2001.
13. Müller BT, Reiher L, Pfeiffer T, et al. Surgical treatment of renal artery dissection in 25 patients: indications and results. *J Vasc Surg* **37**: 761-768, 2003.
14. Pellerin O, Garçon P, Beyssen B, et al. Spontaneous renal artery dissection: long-term outcomes after endovascular stent placement. *J Vasc Interv Radiol* **20**: 1024-1030, 2009.
15. Jeon YS, Cho SG, Hong KC. Renal infarction caused by spontaneous renal artery dissection: treatment with catheter-directed thrombolysis and stenting. *Cardiovasc Intervent Radiol* **32**: 333-336, 2009.
16. Afshinnia F, Sundaram B, Rao P, Stanley J, Bitzer M. Evaluation of characteristics, associations and clinical course of isolated spontaneous renal artery dissection. *Nephrol Dial Transplant* **28**: 2089-2098, 2013.

The Internal Medicine is an Open Access journal distributed under the Creative Commons Attribution-NonCommercial-NoDerivatives 4.0 International License. To view the details of this license, please visit (<https://creativecommons.org/licenses/by-nc-nd/4.0/>).