

[ CASE REPORT ]

## Effectiveness of Crizotinib for Inflammatory Myofibroblastic Tumor with *ALK* mutation

Misato Ogata<sup>1</sup>, Yukimasa Hatachi<sup>1</sup>, Takatsugu Ogata<sup>1</sup>, Hironaga Satake<sup>1,2</sup>,  
Yukihiro Imai<sup>3</sup> and Hisateru Yasui<sup>1</sup>

### Abstract:

Inflammatory myofibroblastic tumor (IMT), a rare sarcoma, is primarily treated via resection of the mass. However, in cases of recurrence or unresectable tumors, no standard care exists. While crizotinib, an anaplastic lymphoma kinase (*ALK*) inhibitor, is only approved for non-small-cell lung cancer with *ALK* mutation, it is reportedly effective for other malignant tumors with *ALK* mutation. We herein report a case involving a 37-year-old woman with retroperitoneal IMT with *ALK* mutation, who experienced recurrence after complete resection, in whom crizotinib treatment resulted in complete response. *ALK*-inhibitor efficacy against malignancies with *ALK* mutations should be investigated in future.

**Key words:** *ALK* mutation, crizotinib, inflammatory myofibroblastic tumor

(Intern Med 58: 1029-1032, 2019)

(DOI: 10.2169/internalmedicine.1640-18)

### Introduction

Precision medicine has become one of the most concerning issues among oncologists. Pembrolizumab, for all patients with unresectable or metastatic and microsatellite instability-high or mismatch repair-deficient solid tumors, was the first approved cancer treatment (US Food and Drug Administration) based on a biomarker analysis. In the future, cancer treatments may be determined based on the biological findings of the tumor rather than its location. We herein report a case of recurrent inflammatory myofibroblastic tumor (IMT) with *anaplastic lymphoma kinase (ALK)* mutation, in which a complete response was achieved using crizotinib, a tyrosine kinase inhibitor targeting *ALK*. The treatments for recurrent IMTs remain controversial, partly because of its rarity; thus, the accumulation of research on this condition can be meaningful. In addition, we would like to introduce the first reported phenomenon where the rearrangement of the *ALK* gene with multiple partner fusion genes was identified in the IMT of a single patient.

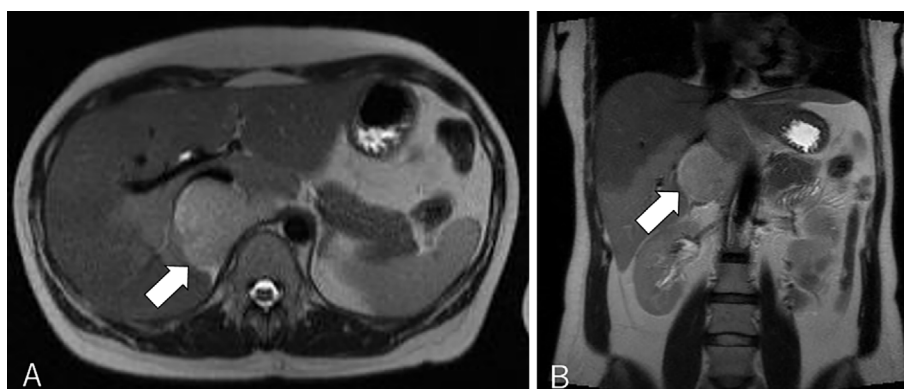
### Case Report

A 37-year-old woman presented to our hospital after a right adrenal gland mass was incidentally detected by ultrasound sonography in an annual medical checkup. She did not have any symptoms. Computed tomography (CT) and magnetic resonance imaging (MRI) revealed a hypervascular mass of 6 cm in diameter adjacent to the right adrenal gland and inferior vena cava (IVC) (Fig. 1). The mass showed the same signal as muscle on T1-weighted imaging and a high signal intensity on T2-weighted imaging. Contrast enhancement was observed gradually from the margin to the center. Positron emission tomography-CT revealed no area of uptake other than the retroperitoneal mass. The patient's laboratory data, including her adrenocorticotrophic hormone, cortisol, dehydroepiandrosterone sulfate, aldosterone, renin, adrenaline, noradrenaline, and dopamine levels were normal, indicating that the function of the adrenal gland was normal. Laparoscopic surgery was conducted in November 2015 to confirm the diagnosis, and the right adrenal gland mass (70×60×50 mm) was removed without any residual lesion. The

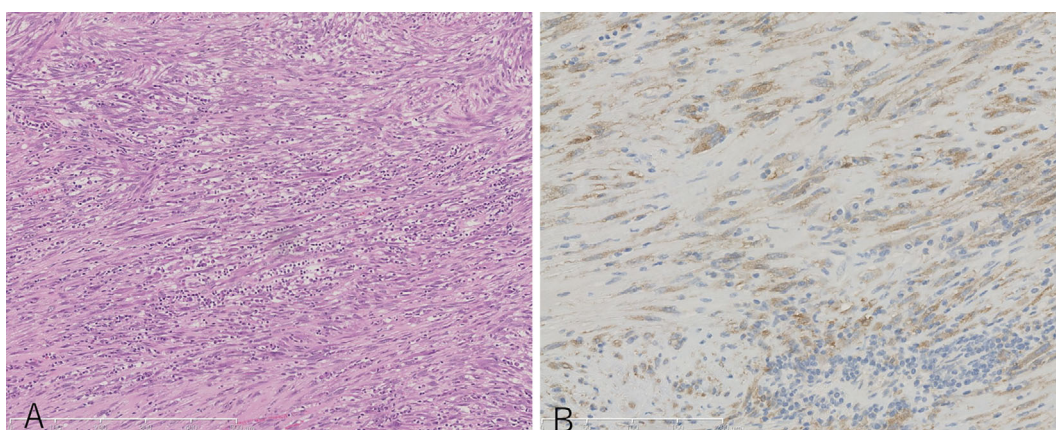
<sup>1</sup>Department of Medical Oncology, Kobe City Hospital Organization Kobe City Medical Center General Hospital, Japan, <sup>2</sup>Cancer Treatment Center, Kansai Medical University Hospital, Japan and <sup>3</sup>Department of Pathology, Kobe City Hospital Organization Kobe City Medical Center General Hospital, Japan

Received: June 3, 2018; Accepted: September 3, 2018; Advance Publication by J-STAGE: November 19, 2018

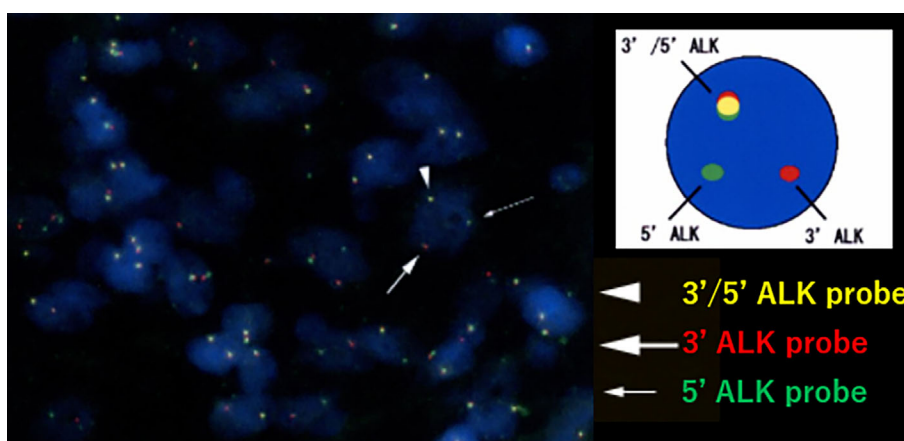
Correspondence to Dr. Yukimasa Hatachi, 1227.yukimasa@gmail.com



**Figure 1.** The magnetic resonance imaging (MRI) findings at the time of the diagnosis. A: Transverse plane (arrow). B: Coronal plane (arrow).



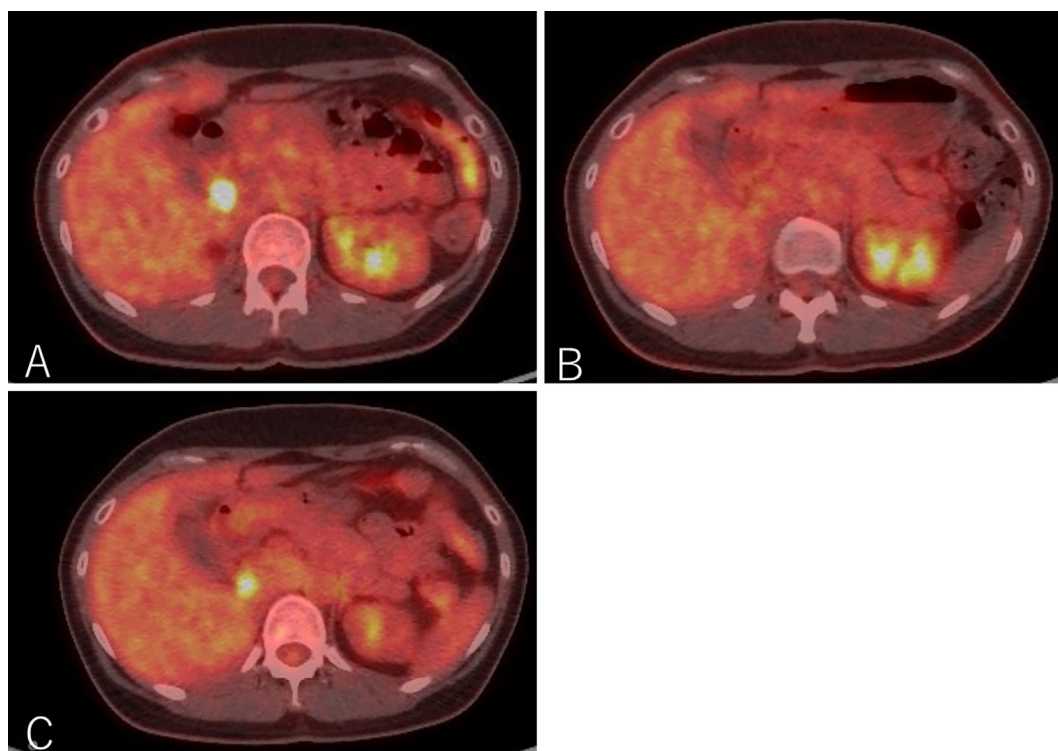
**Figure 2.** The histopathological examination of the first resected mass. A: Hematoxylin and Eosin staining  $\times 10$ . Spindle cells and inflammatory cells were observed. B: *ALK* staining  $\times 20$ . Tumor cells were positive for *ALK*.



**Figure 3.** The *ALK* gene rearrangement that was detected by fluorescent *in situ* hybridization.

tumor was composed of spindle cells in a storiform growth pattern with infiltrating inflammatory cells that were mainly composed of plasma cells (Fig. 2A). An immunohistochemical analysis revealed that the tumor cells were positive for *ALK* (in the cytoplasm) (Fig. 2B) and negative for S-100, desmin, c-kit, and CD34. *ALK* gene rearrangement was de-

tected by fluorescent *in situ* hybridization (Fig. 3); thus, the tumor was diagnosed as IMT with *ALK* rearrangement. We performed RNA sequencing to identify the partner gene and observed that the *ALK* gene had multiple fusion partner genes: *TPM3* (tropomyosin 3), *MPRIP* (myosin phosphatase Rho interacting protein), *KLC1* (kinesin light chain 1), *KIF5*



**Figure 4.** The Positron Emission Tomography-Computed Tomography (PET-CT) findings during the course of treatment. **A:** First recurrence. **B:** Complete response after five months of crizotinib treatment. **C:** Second local recurrence nine months after the discontinuation of crizotinib.

*B* (kinesin family member 5B), *EML4* (echinoderm microtubule associated protein like 4), and *HIP1* (huntingtin interacting protein 1), in descending order from the point of the read counts. Thoracoabdominal examinations using CT were conducted every 3 months, and the first recurrence was observed 7 months after the operation (Fig. 4A). The largest mass was located between the IVC and the right kidney. Small nodal paravertebral lesions showed the uptake of fluorodeoxyglucose and a small mass between the IVC and the pancreas was detected by MRI; these were also likely to be recurrent lesions. Since the suspected recurrent lesions were multiple and unresectable, we assessed that they were inoperable. The patient, whose Eastern Cooperative Oncology Group Performance Status was 0, started crizotinib therapy at a dose of 500 mg per day. Before starting crizotinib, we obtained written informed consent from the patient for off-label use and the approval of crizotinib use in our study by the Ethics Committee of Kobe City Medical Center General Hospital. We discontinued crizotinib one month later, because the patient's aspartate transaminase (AST) and alanine transaminase (ALT) levels increased to 47 U/L and 112 U/L, respectively. Two weeks later, her liver enzymes recovered to within normal limits, and crizotinib therapy was restarted at a dose of 250 mg/day, which was increased to 400 mg/day three weeks later. ALT transiently increased to 73 U/L but finally reached within normal limits. The patient experienced grade 1 visual disturbance (afterimage) and grade 1 diarrhea; however, they were tolerable. Positron emission tomography-CT revealed that she had achieved a

complete response (Fig. 4B); thus, we discontinued crizotinib. The total administration period was five months. Local recurrence was observed again at nine months after treatment, at the same location as the first recurrence (Fig. 4C). This time the mass was small, and she underwent surgical resection. *ALK* staining of the resected tumor was positive. The patient is now free from any treatment and is receiving regular imaging surveillance.

## Discussion

IMT is a rare mesenchymal tumor with an unclear etiology. It can arise in various locations, and is locally aggressive. The first choice of treatment for IMT is surgical resection. Local recurrence may occur once or more than once, but distant metastasis is rare (1). Approximately 50% of IMTs harbor *ALK* gene rearrangement with various fusion partner genes (2). It is known that the pathological features of IMTs, such as the mitotic rate, presence or absence of necrosis, or cellular atypia, do not correspond with the clinical outcome (3, 4). On the other hand, *ALK* rearrangement has been associated with local recurrence but not with distant metastasis, according to a previously reported immunohistochemical study of IMTs (4). *ALK* immunostaining is categorized into three patterns, which appear to be determined by fusion partners (3). The three staining patterns are as follows: smooth cytoplasmic staining, granular cytoplasmic staining, and distinctive nuclear membrane staining; our case showed smooth cytoplasmic staining, which is reason-



**Table. Summary of the Past IMT Cases Using Crizotinib.**

Reference	Age, Sex	Tumor site	Duration of crizotinib use	Result	Major side effects
6	43 y, F	Uterus	Not mentioned	DLT→ceritinib	Not mentioned, but intolerable
7	26 y, M	Cerebrum	16 months	PR→PD→ceritinib	QT prolongation
8	32 y, M	Lung, chest wall, muscle, omentum	8 months	PR→PD→ceritinib	Not mentioned
9	50's, F	Uterine	6 months	PR	tolerable
10	45 y, F	Liver, adrenal gland, lumbar spine	27 months	CR	Not mentioned
11	44 y, M	Abdomen, pelvis	22 months	CR	tolerable

IMT: inflammatory myofibroblastic tumor, F: female, M: male, DLT: dose limiting toxicities, PR: partial response, PD: progressive disease, CR: complete response

able for *TPM3-ALK* fusion. There is no consensus on the optimal treatment of recurrence, as was observed in our patient. In previous case reports, crizotinib has been considered to be effective for *ALK*-positive IMT. Table presents the six cases in which crizotinib was used for *ALK*-positive IMT in adults. The patients were young and their tumor locations varied. In most cases crizotinib first resulted in a partial or better response; however, the final outcomes differed. Our case is the first report of a Japanese patient and is an additional example of that suggests that crizotinib is effective for *ALK*-positive IMT, regardless of where the tumor is.

Crizotinib was first developed as a c-Met (mesenchymal-epithelial transition factor) inhibitor, which is now widely known as an *ALK* inhibitor. Grade ≥3 adverse events included *ALT* elevation in 11% of cases, *AST* elevation in 4% of cases, neutropenia in 9% of cases, QT prolongation in 2% of cases, and interstitial lung disease in 0.6% of cases. Grade 1 eye disorder, which was observed in this case, was reported in 62% of patients in a clinical trial of crizotinib against non-small-cell lung cancer (5). A few cases of interstitial lung disease and liver dysfunction resulted in death in this phase 3 trial; however, most side effects are tolerable. This suggests that crizotinib is a safely manageable drug, and our case also supports the safety of the drug. Similar to crizotinib, off-target effects may lead to the development of new drugs. In conclusion, IMTs occur in various locations; however, regardless of the tumor location, the use of *ALK* inhibitors, such as crizotinib, may be effective for tumors harboring *ALK* mutations.

All procedures followed were in accordance with the ethical standards of the responsible committee on human experimentation (institutional and national) and with the Helsinki Declaration of 1964 and later versions. Informed consent for inclusion in the study, or its equivalent, was obtained from the patient.

**The authors state that they have no Conflict of Interest (COI).**

## References

- Coffin CM, Watterson J, Priest JR, Dehner LP. Extrapulmonary inflammatory myofibroblastic tumor (inflammatory pseudotumor). A clinicopathologic and immunohistochemical study of 84 cases. *Am J Surg Pathol* **19**: 859-872, 1995.
- Gleason BC, Hornick JL. Inflammatory myofibroblastic tumours: where are we now? *J Clin Pathol* **61**: 428-437, 2008.
- Cook JR, Dehner LP, Collins MH, et al. Anaplastic lymphoma kinase (*ALK*) expression in the inflammatory myofibroblastic tumor: a comparative immunohistochemical study. *Am J Surg Pathol* **25**: 1364-1371, 2001.
- Coffin CM, Hornick JL, Fletcher CD. Inflammatory myofibroblastic tumor: comparison of clinicopathologic, histologic, and immunohistochemical features including *ALK* expression in atypical and aggressive cases. *Am J Surg Pathol* **31**: 509-520, 2007.
- Shaw AT, Kim DW, Nakagawa K, et al. Crizotinib versus chemotherapy in advanced *ALK*-positive lung cancer. *N Engl J Med* **368**: 2385-2394, 2013.
- Pickett JL, Chou A, Andrici JA, et al. Inflammatory myofibroblastic tumors of the female genital tract are under-recognized: a low threshold for *ALK* immunohistochemistry is required. *Am J Surg Pathol* **41**: 1433-1442, 2017.
- Chennouf A, Arslanian E, Roberge D, et al. Efficiency of crizotinib on an *ALK*-positive inflammatory myofibroblastic tumor of the central nervous system: a case report. *Cureus* **9**: e1068, 2017.
- Mansfield AS, Murphy SJ, Harris FR, et al. Chromoplectic *TPM3-ALK* rearrangement in a patient with inflammatory myofibroblastic tumor who responded to ceritinib after progression on crizotinib. *Ann Oncol* **27**: 2111-2117, 2016.
- Subbiah V, McMahon C, Patel S, et al. STUMP un“stumped”: anti-tumor response to anaplastic lymphoma kinase (*ALK*) inhibitor based targeted therapy in uterine inflammatory myofibroblastic tumor with myxoid features harboring *DCTN1-ALK* fusion. *J Hematol Oncol* **8**: 66, 2015.
- Jacob SV, Reith JD, Kojima AY, Williams WD, Liu C, Vila Duckworth L. An unusual case of systemic inflammatory myofibroblastic tumor with successful treatment with *ALK*-inhibitor. *case Rep Pathol* **2014**: 470340, 2014.
- Butrynski JE, D'Adamo DR, Hornick JL, et al. Crizotinib in *ALK*-rearranged inflammatory myofibroblastic tumor. *N Engl J Med* **363**: 1727-1733, 2010.

The Internal Medicine is an Open Access journal distributed under the Creative Commons Attribution-NonCommercial-NoDerivatives 4.0 International License. To view the details of this license, please visit (<https://creativecommons.org/licenses/by-nc-nd/4.0/>).