Internal Medicine
The Japanese Society of Internal Medicine

doi: 10.2169/internalmedicine.4752-20
Intern Med 60: 145-150, 2021
http://internmed.jp

【 CASE REPORT 】

Membranous Nephropathy with Proteinase 3-ANCA-associated Vasculitis Successfully Treated with Rituximab

Shun Yoshida, Shunichiro Hanai, Daiki Nakagomi, Kei Kobayashi,
Kazuya Takahashi and Fumihiko Furuya

Abstract:
Membranous nephropathy (MN) with anti-neutrophil cytoplasmic antibody (ANCA)-associated glomerulonephritis (ANCA-GN) is seen infrequently. Previous reports of patients with ANCA-GN with MN showed that the most frequent ANCA subtype was myeloperoxidase-ANCA. We herein present a 73-year-old woman with scleritis, hematuria, proteinuria, and positive serum proteinase 3 (PR3)-ANCA. She underwent a renal biopsy and was diagnosed with MN and ANCA-GN. Immunofluorescence staining for PR3 colocalized with IgG along the glomerular basement membrane were observed. Oral prednisolone and intravenous rituximab therapy immediately improved her symptoms and urinalysis abnormalities. PR3-ANCA may be involved in the pathogenesis of MN via the formation of immune complexes.

Key words: small vessel vasculitis, glomerular disease, secondary membranous nephropathy, immune complex deposits, immunofluorescence staining

(Intern Med 60: 145-150, 2021)
(DOI: 10.2169/internalmedicine.4752-20)

Introduction

Anti-neutrophil cytoplasmic antibody (ANCA)-associated vasculitis (AAV) is defined as necrotizing vasculitis, with few or no immune deposits, predominantly affecting small vessels. AAV is comprised of microscopic polyangiitis, granulomatosis with polyangiitis, and eosinophilic granulomatosis with polyangiitis; glomerulonephritis is common (1). The typical renal involvement of AAV is pauci-immune necrotizing and crescentic glomerulonephritis. However, immune complex deposition in ANCA-associated glomerulonephritis (ANCA-GN) is not unusual (2, 3).

Membranous nephropathy (MN) is the most common cause of nephrotic syndrome in nondiabetic adults (4). MN is an immune complex disease caused by subepithelial deposits. The pathologic features of MN on light microscopy include glomerular basement membrane (GBM) thickening with little or no cellular proliferation or infiltration (5). Approximately 20% of all cases of MN are secondary to other diseases, such as infections, malignancy, and autoimmune diseases, or to drugs and toxins. Among autoimmune diseases, the most common cause is systemic lupus erythematosus (4).

Crescentic GN with MN and small vessel vasculitis, such as AAV, have been reported recently, but these reports were mainly case studies and case series (6-10). In these previous studies, the most frequent ANCA subtype was myeloperoxidase (MPO)-ANCA, whereas proteinase 3 (PR3)-ANCA was rare. We herein present a 73-year-old woman who had MN with PR3-ANCA-associated vasculitis who was successfully treated with glucocorticoid therapy and rituximab (RTX).

Case Report

A 73-year-old Japanese woman developed ophthalmalgia and congestion of her left eye a month earlier. She was diagnosed with scleritis by an ophthalmologist and referred to our hospital for the further assessment of possible rheumatic diseases. She had hypertension and dyslipidemia, and was taking oral amlodipine 2.5 mg and atorvastatin 5 mg daily. The results of a physical examination on admission were as follows: temperature, 36.4°C; heart rate, 80 beats per minute; blood pressure, 131/69 mmHg; and oxygen saturation,

Third Department of Internal Medicine, University of Yamanashi, Japan
Received: March 1, 2020; Accepted: June 28, 2020; Advance Publication by J-STAGE: August 22, 2020
Correspondence to Dr. Shunichiro Hanai, shanai@yamanashi.ac.jp

98% while breathing ambient air. Both lungs were clear on auscultation. Heart sounds were normal, and no murmur was audible. Scleral congestion of her left eye was observed. Edema or purpura was not present on her lower extremities.

Here serum creatinine level was 0.91 mg/dL; C-reactive protein, 0.4 mg/dL; IgG, 1,165 mg/dL; C3, 111 mg/dL; C4, 29 mg/dL; anti-nuclear antibody was positive (1:80 with homogenous and speckled pattern); rheumatoid factor, 11 IU/mL (normal, <15 IU/mL); anti-double stranded DNA antibody, 10 U/mL (normal, <12 U/mL); MPO-ANCA, <0.5 U/mL (normal, <3.5 U/mL); PR3-ANCA, 725 U/mL (normal, <15 U/mL); and anti-GBM antibody and anti-phospholipase A2 receptor (PLA2R) antibody were negative. Urinalysis findings included a positive occult blood test (3+), and protein was 2+ (urine protein was negative in a medical checkup 1 year previously). The urinary sediment contained 10 to 15 erythrocytes per high-power field. No urine casts were observed. The urine protein/creatinine ratio (UPCR) was 2.6 g/gCr. Chest X-ray showed no apparent pulmonary opacity, but computed tomography of the lungs revealed bilateral ground-glass opacity, which indicated alveolar hemorrhaging (Fig. 1). However, she had no bloody sputum or hemoptysis. Based on the positive PR3-ANCA, urinalysis, and computed tomography findings, she was suspected of having PR3-AAV.

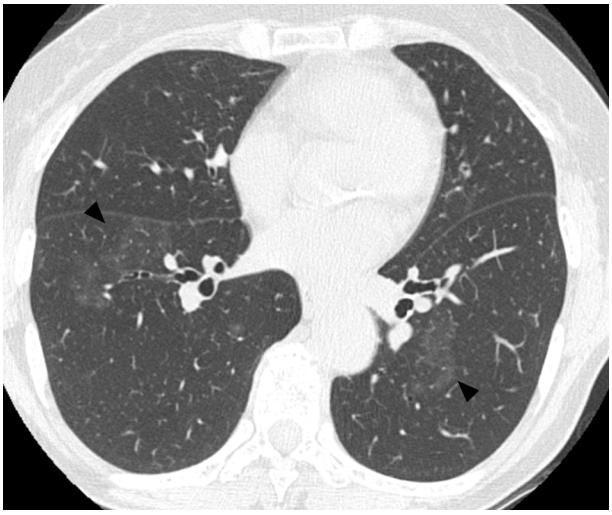

Figure 1. High-resolution computed tomography of the lungs shows bilateral ground-glass opacity, which indicates alveolar hemorrhaging (arrowhead).

A renal biopsy was performed, and the findings on light microscopy showed 24 glomeruli, 2 with global sclerosis and 1 with fibrocellular crescents (Fig. 2A). Spike formation and a bubbly appearance of the basement membrane were observed on the outer surface of the capillary wall with periodic acid-methenamine silver staining (Fig. 2A). Subepithelial deposits were detected with Masson trichrome staining (Fig. 2B). Immunofluorescence staining revealed diffuse and global granular deposits of IgG along the outer surfaces of all capillary walls (score 2+, on a scale of 0 to 4+, Dako, Denmark) (Fig. 3). An IgG subclass analysis (Binding Site Group, UK) showed that IgG1 was 2+, IgG2, IgG3, and IgG 4 were 1+ (Fig. 3). No apparent staining was seen for IgA, IgM, C1q, C3, or C4 (data not shown). Electron microscopy showed electron-dense deposits mainly in the subepithelial area, spike formation of the glomerular basement membrane, effacement of the podocyte foot processes, and thickening of the GBM (Fig. 4A). Findings on light and electron microscopy indicated MN stage II concomitant with crescentic GN. Immunofluorescence staining for PR3 colocalized with IgG along the GBM were observed (Fig. 4B) (Immunofluorescence with Alexa Fluor 555 (red)-labeled anti-PR3; MyBioSource, San Diego, USA, and FITC (green)-labeled anti-

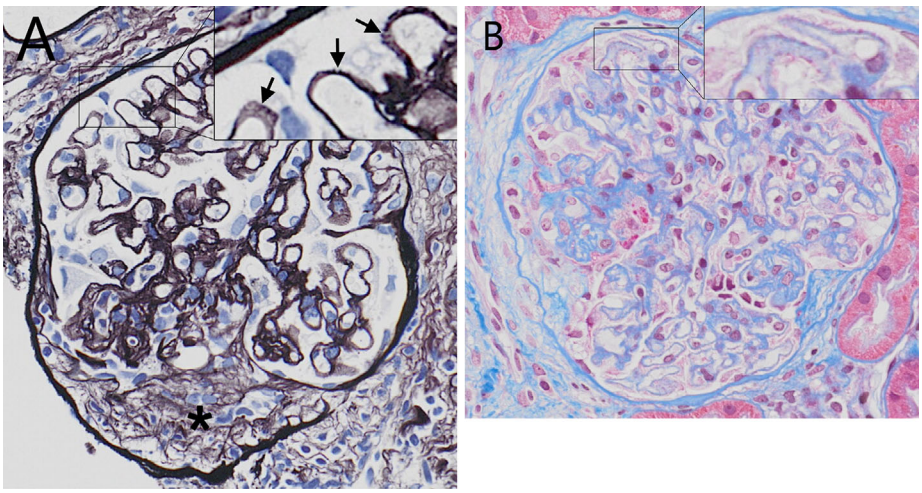

Figure 2. Histopathologic findings of the kidney biopsy specimen. (A) Spike formation and a bubbly appearance of the basement membrane are observed on the outer surface of the capillary wall (arrow) (periodic acid-methenamine silver staining; original magnification, ×400). Fibrocellular crescents are detected in the same glomeruli (*). (B) Subepithelial deposits are globally detected in glomeruli. (Masson trichrome staining; original magnification, ×400).

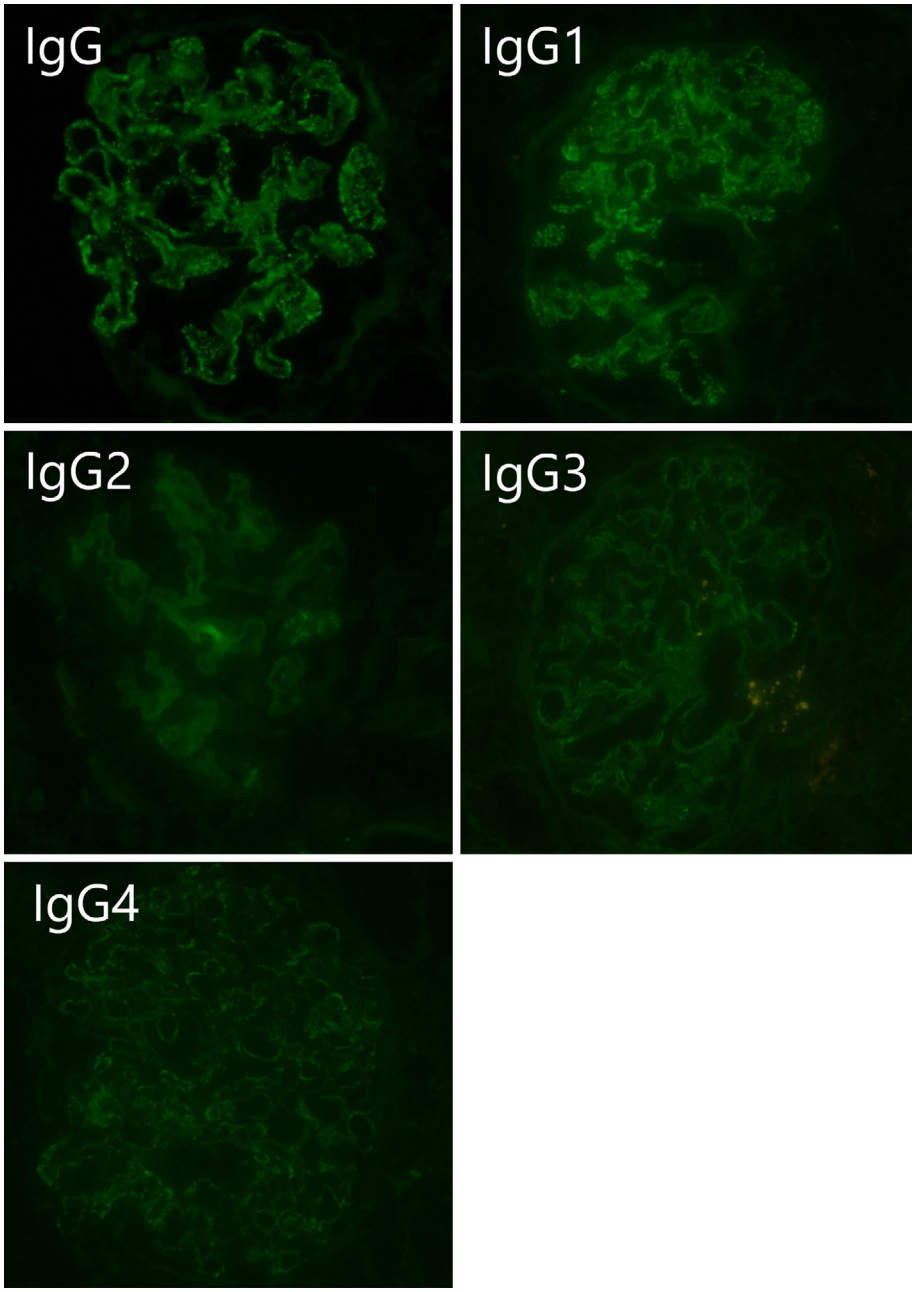

Figure 3. Immunofluorescence staining of the kidney biopsy specimen. There are granular deposits of IgG along the outer surfaces of all capillary walls (original magnification, ×400, score 2+). The intensity levels of IgG subclass staining are IgG1: 2+, IgG2 1+, IgG3 1+, and IgG4 1+.

IgG; Proteintech Group, Rosemont, USA). In contrast, nephrosclerosis showed no staining for PR3.

According to her clinical symptoms, such as scleritis, radiographic findings indicating pulmonary hemorrhage, and histopathologic findings of renal biopsy, she was diagnosed with MN and PR3-AAV. There were no signs of interstitial pneumonia or otolaryngologic involvement. Her clinical course is shown in Fig. 5. She received oral prednisolone 25 mg/day and 4 infusions of RTX (375 mg/m^2) at 1-week intervals. Her ophthalmalgia and congestion thereafter immediately improved, and UPCR gradually decreased. Four weeks after induction of therapy, UPCR was reduced to 0.15 g/gCr. No deterioration in her renal function was seen. Thereafter, she received maintenance therapy with infusions of RTX 1,000 mg every 6 months a total of 3 times. Glucocorticoid therapy was gradually tapered off over 7 months. She has had no recurrence for about 2 years.

Discussion

The typical renal involvement of AAV is crescentic GN characterized by a paucity of glomerular immune complex deposits (1). The term "pauci-immune" is defined as 2+ or lower staining for any immunoglobulin on immunofluorescence staining (on a scale of 0 to 4+) and the absence of immune complex type electron dense deposits on electron microscopy (11). Previous studies reported that 18-54% of AAV patients who underwent renal biopsies had glomerular

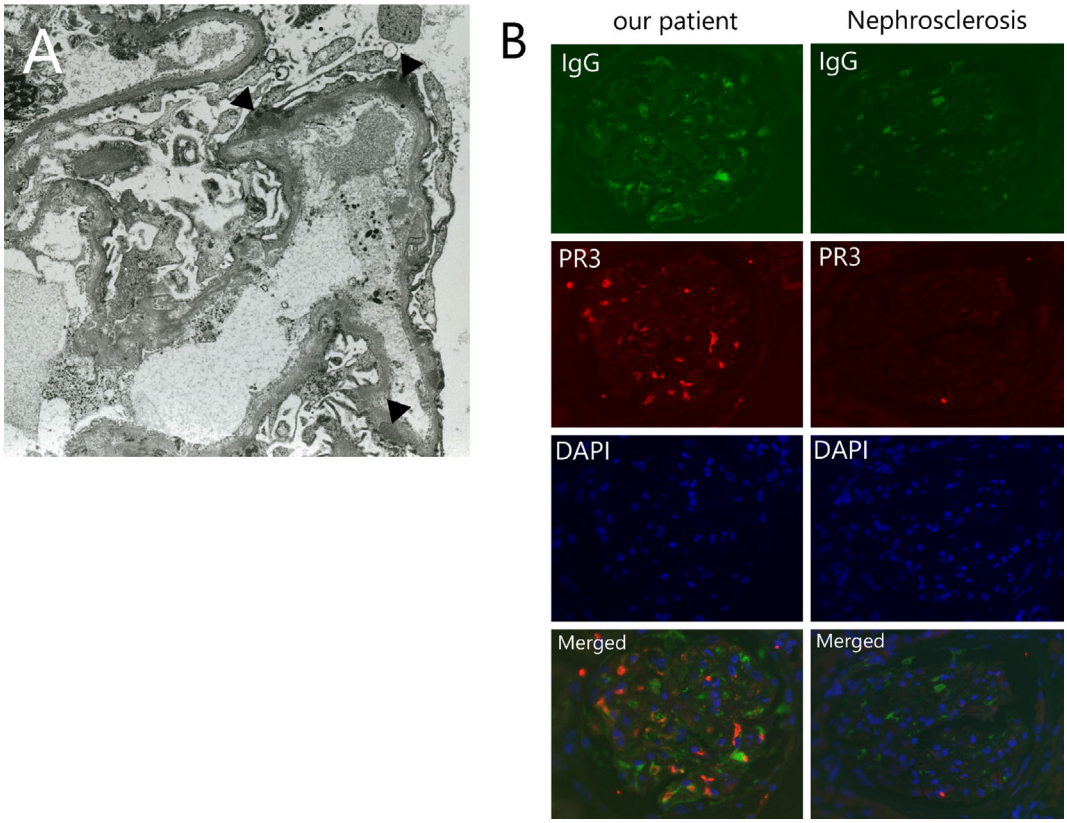

Figure 4. **(A) Electron microscopy showed electron-dense deposits in the subepithelial lesion (arrowhead) and thickening of the glomerular basement membrane. (B) Immunofluorescence with Alexa Fluor 555 (red) -labeled anti-PR3, and FITC (green) -labeled anti-IgG. The merger of immunofluorescence in some parts of the GBM and the mesangium demonstrated colocalization of PR3 and IgG within these areas. In contrast, nephrosclerosis showed no staining for PR3.**

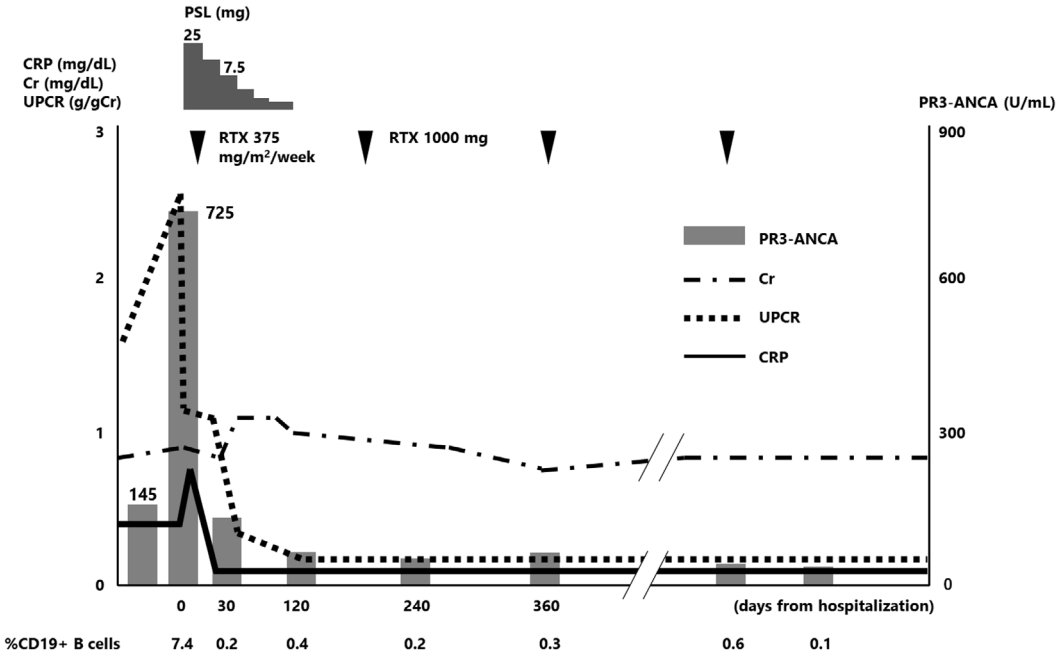

Figure 5. **The clinical course of the patient. Cr: creatinine, CRP: C-reactive protein, PR3-ANCA: proteinase 3-anti-neutrophil cytoplasmic antibodies, PSL: prednisolone, RTX: rituximab, UPCR: urine protein/creatinine ratio**

immune complex deposits on light or electron microscopy (2, 3, 12). In these patients, crescentic GN with immunoglobulin deposition in the mesangium or capillary loops represented the majority of renal histopathological features, while concomitant IgA nephropathy or MN was rarely reported.

The occurrence of ANCA-GN with MN has been increasingly documented (6-10), but these reports are confined mainly to case studies and case series, and the pathogenesis has not yet been fully elucidated. In a case series of 14 patients with ANCA-GN with MN, heavy proteinuria, hematuria, and acute renal injury were noted (7). Additionally, in a cohort study of 27 patients with combined ANCA-GN and MN, patients had significantly higher levels of initial serum creatinine, a higher Birmingham Vasculitis Activity Score, and a worse renal outcome than ANCA-GN patients without MN (10). According to previous studies, ANCA-GN with MN is more likely to have a progressive clinical course than MN alone (7, 9, 10), although our patient had a favorable clinical outcome. We considered that her early diagnosis based on her clinical symptoms and renal biopsy findings, and intensive treatment with RTX contributed to her good prognosis.

RTX is a monoclonal antibody against the CD20 antigen expressed on B lymphocytes. The selective depletion of B cells by RTX is known to be a beneficial treatment for idiopathic MN (13). Previous studies have demonstrated the efficacy of RTX for MN (13). A combination of glucocorticoid therapy and cyclophosphamide has been the standard therapy to induce a remission of AAV (14, 15). However, various adverse events including infertility, cytopenia, infections, bladder injury, and cancer limit this treatment strategy. Two major controlled trials demonstrated the efficacy and safety of RTX for AAV treatment (14, 15). Due to the efficacy of an RTX-based regimen for both idiopathic MN and AAV patients, RTX may therefore be a promising treatment for patients with ANCA-GN with MN. As mentioned above, because patients with ANCA-GN with MN may have severe proteinuria and a poor renal prognosis, the immediate induction of remission may be key to improving the renal outcome. A favorable outcome for our patient was achieved with low-dose glucocorticoid and RTX combination therapy.

Our patient exhibited serum PR3-ANCA positivity. The ANCA subtypes reported in previous studies were mostly MPO- or perinuclear-ANCA (7-10, 16); PR 3- and cytoplasmic-ANCA were rare (3, 7, 10). The precise mechanisms of MN formation with ANCA-GN are still unclear. In cases of MPO-ANCA-GN with MN, it is hypothesized that MPO released from activated neutrophils may bind to immune complex deposits and thus lead to the development of MN-like lesions. Indeed, the colocalization of MPO and IgG within the GBM was observed in patients with ANCA-GN with MN (10, 17). Similar to these reports, our patient exhibited granular deposition of PR3 and IgG along the GBM. This finding may indicate that PR3 can induce MN via the formation of immune complexes. *In vitro* data indicate that both ANCA serotypes can activate neutrophils and release inflammatory mediators (18). Subsequently, ANCAs are released into the circulation from neutrophils and bind to endothelial cells, thus causing vascular inflammation (18). Additionally, PR3 expression is genetically determined (19). From these findings, it was speculated that PR3 released into the circulation from highly expressed activated neutrophils formed immune complexes with IgG, which were trapped within the GBM and consequently caused MN.

Previous studies indicated that IgG subclasses and anti-PLA2R antibodies were important to distinguish idiopathic from secondary MN (10, 20). Idiopathic MN typically shows positive serum anti-PLA2R antibodies and IgG4 staining on immunofluorescence, but the significance of these findings has not been fully elucidated. Secondary MN, including that seen in our patient, is generally associated with negative anti-PLA2R antibodies (10), although some reports have shown MPO-ANCA-MN patients with positive serum PLA2R antibodies (16). The important issue in this patient is whether MN occurred with or was secondary to PR3-AAV. Negative serum anti-PLA2R antibodies may indicate that MN was secondary to PR3-AAV in our case. Additionally, as mentioned above, PR3 and IgG staining along the GBM may indicate the formation of immune complexes. Thus, we assume that MN was caused by PR3-AAV in this patient. Further investigations are needed to clarify the relationship between PR3-ANCA and MN formation.

To the best of our knowledge, there have been no reports presenting immunofluorescence staining of PR3 and IgG with ANCA-GN with MN. PR3-ANCA as well as MPO-ANCA may be involved in the formation of ANCA-MN. We should keep in mind that ANCA-GN with MN is not a rare condition. Generally, ANCA-MN may have a poor renal outcome. Thus, making an early diagnosis and treatment, which could include the use of RTX, is important.

Written informed consent was obtained from the patient by the corresponding author. The signed consent forms are retained by the corresponding author. We anonymized the patient's details as much as possible.

The authors state that they have no Conflict of Interest (COI).

Acknowledgement

We thank Drs. Daiichiro Akiyama, Makiko Konishi, Takeyuki Takamura, and Hiroshi Suwa for advice on the analysis of the renal pathology.

References

1. Jennette JC, Falk RJ, Bacon PA, et al. 2012 revised International Chapel Hill Consensus Conference Nomenclature of Vasculitides. Arthritis Rheum **65**: 1-11, 2013.
2. Haas M, Eustace JA. Immune complex deposits in ANCA-associated crescentic glomerulonephritis: a study of 126 cases. Kidney Int **65**: 2145-2152, 2004.
3. Yu F, Chen M, Wang SX, Zou WZ, Zhao MH, Wang HY. Clinical and pathological characteristics and outcomes of Chinese patients

with primary anti-neutrophil cytoplasmic antibodies-associated systemic vasculitis with immune complex deposition in kidney. Nephrology (Carlton) **12**: 74-80, 2007.

4. Couser WG. Primary membranous nephropathy. Clin J Am Soc Nephrol **12**: 983-997, 2017.

5. Fogo AB, Lusco MA, Najafian B, Alpers CE. AJKD atlas of renal pathology: membranous nephropathy. Am J Kidney Dis **66**: e15-e17, 2015.

6. Balafa O, Kalaitzidis R, Liapis G, et al. Crescentic glomerulonephritis and membranous nephropathy: a rare coexistence. Int Urol Nephrol **47**: 1373-1377, 2015.

7. Nasr SH, Said SM, Valeri AM, et al. Membranous glomerulonephritis with ANCA-associated necrotizing and crescentic glomerulonephritis. Clin J Am Soc Nephrol **4**: 299-308, 2009.

8. Suwabe T, Ubara Y, Tagami T, et al. Membranous glomerulopathy induced by myeloperoxidase-anti-neutrophil cytoplasmic antibody-related crescentic glomerulonephritis. Intern Med **44**: 853-858, 2005.

9. Tse WY, Howie AJ, Adu D, et al. Association of vasculitic glomerulonephritis with membranous nephropathy: a report of 10 cases. Nephrol Dial Transplant **12**: 1017-1027, 1997.

10. Zou R, Liu G, Cui Z, Chen M, Zhao MH. Clinical and immunologic characteristics of patients with ANCA-associated glomerulonephritis combined with membranous nephropathy: a retrospective cohort study in a single Chinese center. Medicine (Baltimore) **94**: e1472, 2015.

11. Falk RJ, Jennette JC. ANCA small-vessel vasculitis. J Am Soc Nephrol **8**: 314-322, 1997.

12. Neumann I, Regele H, Kain R, Birck R, Meisl FT. Glomerular immune deposits are associated with increased proteinuria in patients with ANCA-associated crescentic nephritis. Nephrol Dial Transplant **18**: 524-531, 2003.

13. Fervenza FC, Appel GB, Barbour SJ, et al. Rituximab or cyclosporine in the treatment of membranous nephropathy. N Engl J Med **381**: 36-46, 2019.

14. Stone JH, Merkel PA, Spiera R, et al. Rituximab versus cyclophosphamide for ANCA-associated vasculitis. N Engl J Med **363**: 221-232, 2010.

15. Jones RB, Tervaert JW, Hauser T, et al. Rituximab versus cyclophosphamide in ANCA-associated renal vasculitis. N Engl J Med **363**: 211-220, 2010.

16. Tominaga K, Uchida T, Imakiire T, et al. Anti-neutrophil cytoplasmic antibody-associated glomerulonephritis with detection of myeloperoxidase and phospholipase A2 receptor in membranous nephropathy-lesions: report of two patients with microscopic polyangiitis. BMC Nephrol **19**: 120, 2018.

17. Hanamura K, Tojo A, Kinugasa S, et al. Detection of myeloperoxidase in membranous nephropathy-like deposits in patients with anti-neutrophil cytoplasmic antibody-associated glomerulonephritis. Hum Pathol **42**: 649-658, 2011.

18. Hilhorst M, van Paassen P, Tervaert J.W. Proteinase 3-ANCA vasculitis versus myeloperoxidase-ANCA vasculitis. J Am Soc Nephrol **26**: 2314-2327, 2015.

19. Witko-Sarsat V, Thieblemont N. Granulomatosis with polyangiitis (Wegener granulomatosis): a proteinase-3 driven disease? Joint Bone Spine **85**: 185-189, 2018.

20. Kuroki A, Shibata T, Honda H, Totsuka D, Kobayashi K, Sugisaki T. Glomerular and serum IgG subclasses in diffuse proliferative lupus nephritis, membranous lupus nephritis, and idiopathic membranous nephropathy. Intern Med **41**: 936-942, 2002.

The Internal Medicine is an Open Access journal distributed under the Creative Commons Attribution-NonCommercial-NoDerivatives 4.0 International License. To view the details of this license, please visit (https://creativecommons.org/licenses/by-nc-nd/4.0/).

© 2021 The Japanese Society of Internal Medicine
Intern Med 60: 145-150, 2021