

[CASE REPORT]

Two Cases of Autoimmune Neutropenia Complicated with Other Lineages of Autoimmune Cytopenia, Successfully Treated with Prednisolone

Yoshiya Adachi, Yumi Yamazoe-Ishiguri, Satoshi Iwata, Atsushi Murase,
Rika Kihara and Koichi Watamoto

Abstract:

Though adult-onset primary autoimmune pancytopenia (AIP) rarely follows a self-limited course, a standard treatment strategy has not yet been established. We herein report two cases, each involving primary autoimmune neutropenia complicated with autoimmune thrombocytopenia or Evans syndrome. They were refractory to granulocyte-colony stimulating factor, but all lineages of cytopenia promptly recovered with prednisolone (PSL). In case 1, PSL was tapered and discontinued six months after its initiation without AIP relapse. In case 2, PSL has been tapered for five months without relapse. To establish an optimal treatment strategy for AIP, it is necessary to accumulate more cases.

Key words: autoimmune neutropenia, autoimmune pancytopenia, prednisolone, antineutrophil antibody

(Intern Med 60: 1271-1277, 2021)

(DOI: 10.2169/internalmedicine.6032-20)

Introduction

Autoimmune neutropenia (AIN) is a hematological disease caused by the autoantibody-induced destruction of neutrophils (1). Auto-antineutrophil antibodies react to surface proteins on neutrophils, such as human neutrophil antigen (HNA)-1. AIN is a rare disorder and is less frequently reported than idiopathic thrombocytopenic purpura (ITP) and autoimmune hemolytic anemia (AIHA), both of which are also categorized as autoimmune cytopenia. It is well established that Evans syndrome is a result of the combination of ITP and AIHA; however, it is relatively rare for ITP and/or AIHA to additionally complicate AIN.

Several treatment agents, such as granulocyte-colony-stimulating factor (G-CSF), steroids, and/or immunosuppressive drugs, have been recommended for AIN, but a standard treatment strategy has not yet been established (2, 3).

We herein report two cases, each involving primary AIN complicated with autoimmune thrombocytopenia (AIT) or Evans syndrome, neither of which responded to G-CSF; however, both were successfully treated with prednisolone

(PSL).

Case Reports

Case 1

A 67-year-old man with hyperuricemia and hyperlipidemia visited his primary physician due to a fever that had persisted for 3 days. His blood test revealed leukocytopenia. He was suspected of having a hematological disorder and was referred to our hospital.

At the initial physical examination, he had a fever of 37.6°C, but his overall condition was unremarkable. His laboratory data are shown in Table 1. His white blood cell and neutrophil counts were 1,100/μL and 33/μL, respectively. He did not have thrombocytopenia or anemia, but his direct and indirect Coombs tests were positive. In addition to neutropenia, aspartate aminotransferase (AST) and alanine aminotransferase (ALT) levels were elevated. He was therefore suspected of having a viral infection, such as cytomegalovirus (CMV) or Epstein-Barr virus (EBV). Although CMV IgM initially showed weak positivity, the CMV IgG meas-

Table 1. Laboratory Findings at Diagnosis of Case 1.

WBC	1,100 / μ L	T-Bil	0.6 mg/dL	CMV IgM (EIA)	1.37
Band	1.0 %	AST	95 IU/L	CMV IgG (EIA)	20.0
Seg	2.0 %	ALT	202 IU/L	CMV pp65 (C10;C11)	(0,0)
Eosino	9.0 %	LDH	140 IU/L	EBVCA IgM (EIA)	0.9
Baso	0.0 %	BUN	13.5 mg/dL	EBVCA IgG (EIA)	11.0
Mono	53.0 %	Cre	0.92 mg/dL	EBNA IgG (EIA)	4.1
Lym	33.0 %	Fe	37.7 μ g/dL	LA	1.30
RBC	395 \times 10 ⁴ / μ L	Ferritin	610 ng/mL	Anti-CL- β 2GPI Ab	<1.2 U/mL
Hb	13.1 g/dL	TIBC	195 μ g/dL	CL-IgG Ab	<8 U/mL
MCV	94.9 fL	Vit.B12	1,901 pg/mL	PA IgG	351
Plt	21.5 \times 10 ⁴ / μ L	Folic acid	14.6 ng/mL	sIL2-R	1,150 U/mL
Reti	8.0 ‰	IgG	1,371 mg/dL	D-Coombs	3+
		IgA	175 mg/dL	I-Coombs	+
PT-INR	1.09	IgM	83.5 mg/dL	Haptoglobin	263 mg/dL
APTT	30.5 sec	CH50	48.9 U/mL	Antineutrophil Ab	+
Fib	668 mg/dL	ANA	\times 40	Anti- <i>H. pylori</i> IgG	<3
FDP	5.5 μ g/mL	Anti-dsDNA Ab	<2.0 IU/mL		

CH50: 50% hemolytic complement activity, ANA: antinuclear antibody, Anti-ds DNA Ab: anti-double stranded DNA antibody, CMV: cytomegalovirus, EBVCA: Epstein-Barr virus capsid antigen, EBNA: Epstein-Barr virus-nuclear antibody, EIA: enzyme immunoassay, LA: lupus anticoagulant, Anti-CL- β 2GPI Ab: anti cardiolipin β 2- glycoprotein I complex antibody, CL-IgG Ab: anticardiolipin antibodies-IgG, PA IgG: platelet-associated IgG, sIL2R: soluble interleukin-2 receptor, D-Coombs: direct Coombs test, I-Coombs: indirect Coombs test

ured by an enzyme immunoassay 14 and 28 days later showed no marked increases compared with the initial data (CMV IgG at days 1, 14, and 28: 20.0, 19.1, and 17.8, respectively). CMV antigenemia was also negative. EBV IgM was weakly positive, but EBV IgG and EBV nuclear antibody (EBNA) were positive. These findings for CMV and EBV were indicative of a previous but not present infection.

To screen for collagen diseases, several autoantibodies were measured. There were no increases in anti-nuclear Ab (ANA) or anti-dsDNA Ab or decreases in 50% hemolytic complement activity (CH50). In addition to these results, as the patient had no skin symptoms or arthritis, he was deemed negative for collagen diseases.

His bone marrow smears were normocellular, with no decrease in megakaryocytes. There were decreases in mature myeloid cells, such as band and segment cells (3.6% and 0.2%), and relative increases in myelocytes and metamyelocytes (25.4% and 22.8%) (Fig. 1a). There was no significant increase in myeloblasts (1.6%). The myeloid:erythroid ratio was 3.0. There was no morphological dysplasia in any of the hematological cell lineages, and a flow cytometry analysis did not detect any abnormal cell populations in his bone marrow sample. A chromosomal analysis of his bone marrow sample showed a normal karyotype.

Computed tomography (CT) revealed no signs of infection, swollen lymph nodes, or hepatosplenomegaly. As these findings led to suspicions that he had AIN, further testing confirmed that he was positive for antineutrophil antibody.

The clinical course of case 1 is shown in Fig. 2a. The patient was treated with cefepime (CFPM) and filgrastim for febrile neutropenia after 3 days of filgrastim; however, there was no increase in neutrophils. Although thrombocytopenia

was not detected at the time of admission, his platelet count gradually decreased and sank to $17\times 10^3/\mu$ L at 12 days post-admission. His coagulation and bone marrow tests were then re-assessed, but there was no sign of disseminated intravascular coagulation (DIC) or a decrease in his bone marrow megakaryocytes. To rule out drug-induced thrombocytopenia, we switched from CFPM to piperacillin/tazobactam (PIPC/TAZ) and discontinued administering allopurinol and pravastatin. Platelet transfusions were conducted, but as there was no increase in the platelet count [1-hour corrected count increment (CCI) = $1,000/\mu$ L, and 24-hour CCI = $1,500/\mu$ L], he was considered to be platelet transfusion-refractory. These findings indicated that, in addition to AIN, he also had AIT.

Both the AST and ALT elevations gradually improved post-admission. After 14 days, the AST level was in the normal range, and the ALT level had decreased to about 40~50 IU/L. Based on these results, and combined with the positive direct and indirect Coombs tests, he was finally diagnosed with autoimmune pancytopenia and started on oral PSL at a dose of 0.5 mg/kg/day (30 mg/day).

His neutrophil and platelet counts increased after PSL administration, and 8 days post-PSL induction (22 days post-admission), his neutrophil count rose to $651/\mu$ L. As his fever had resolved, PIPC/TAZ was discontinued. Seventeen days post-PSL induction (35 days post-admission), as his temperature and neutrophil counts were both in the normal range and his platelet count had also improved, he was discharged. His PSL dose was gradually tapered and finally discontinued six months after initial administration. At his last visit (six months after PSL discontinuation), his neutrophil and platelet counts remained normal, and his anti-

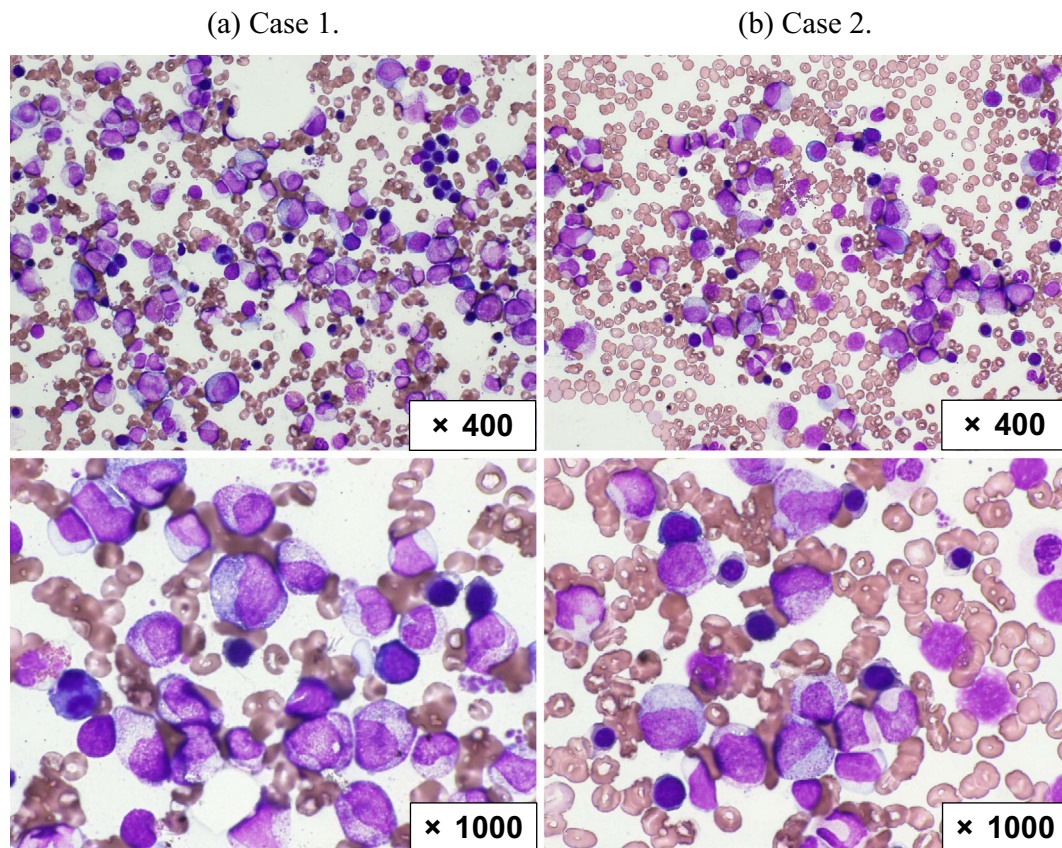


Figure 1. Bone marrow aspiration smear at admission (May-Giemsa staining). (a, b) In both cases, bone marrow smears revealed decreases in myeloid mature cells and relative increases in promyelocytes and myelocytes without an increase in blasts. There was no morphological dysplasia.

neutrophil antibody were confirmed to be negative.

Case 2

A 48-year-old woman who had previously been treated with PSL for AIHA 16 years earlier, and had maintained remission without any immunosuppressive treatments for about 15 years was referred to our hospital's dentist due to a 5-day history of a fever after tooth extraction. The dentist could not identify the focus of the infection in her oral cavity; however, her blood test revealed severe leukocytopenia (WBC 400/ μ L). Due to the leukocytopenia and persistent fever, she was referred to a hematologist.

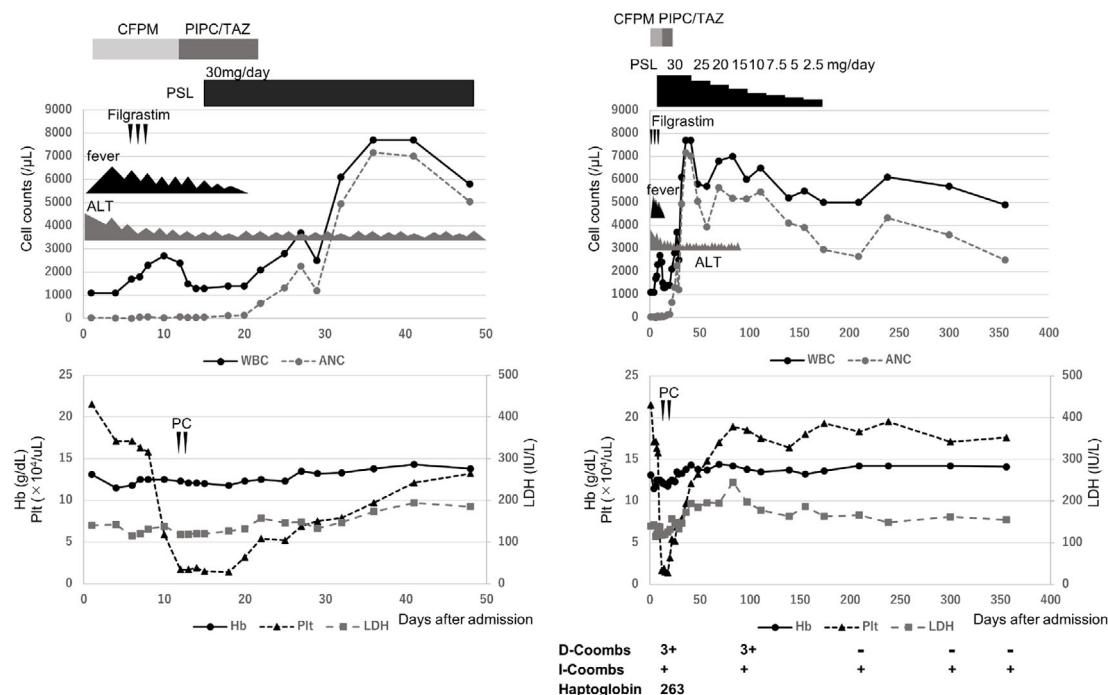
She had a fever of 37.9°C, and her spleen was palpable 3 finger-breadths below the left costal margin; other physical signs were unremarkable. Her laboratory data are shown in Table 2. Her blood test revealed severe neutropenia (neutrophil count 96/ μ L) with slight anemia and thrombocytopenia. Her direct and indirect Coombs tests were positive with a decrease in haptoglobin, which suggested a relapse of AIHA. In addition, she showed thrombocytopenia without signs of DIC, anti-phospholipid antibody syndrome (APS), and deep vein thrombosis (DVT), suggesting Evans syndrome.

To screen for collagen diseases, several autoantibodies were measured. There was an increase in ANA but no increase in anti-dsDNA Ab or decrease in CH50. In addition,

as she had no skin symptoms or arthritis, she was deemed negative for collagen diseases. Her bone marrow smears were normocellular, with no decrease in megakaryocytes. There were slight increases in erythroid lineage cells, decreases in mature neutrophils (band and segment cells were 7.6% and 2.8%, respectively), and a relative increase in myelocytes (30.8%). In addition, there was no increase in blast cells (1.4%) (Fig. 1b). The myeloid: erythroid ratio was 2.0. A flow cytometric analysis of a bone marrow sample revealed no abnormal cell populations. Furthermore, a chromosomal analysis of G-banding showed a normal karyotype. CT showed mild to moderate splenomegaly (Fig. 3a) but no signs of infection or swollen lymph nodes. Based on these results, and after testing positive for antineutrophil antibody in her blood serum, the cause of her neutropenia was confirmed to be AIN.

The clinical course of case 2 is shown in Fig. 2b. The patient was treated with CFPM and filgrastim for febrile neutropenia. Filgrastim administration for 4 days did not relieve her fever or increase her neutrophil count. As extended-spectrum beta-lactamase (ESBL)-producing *Escherichia coli* was detected in her urine culture, we switched from CFPM to meropenem (MEPM). Her fever was resolved after a few days of MEPM treatment, but there was no neutrophil count recovery. Furthermore, her thrombocytopenia and anemia worsened. Thus, she received PSL at 1.0 mg/kg/day (50 mg/

(a)



(b)

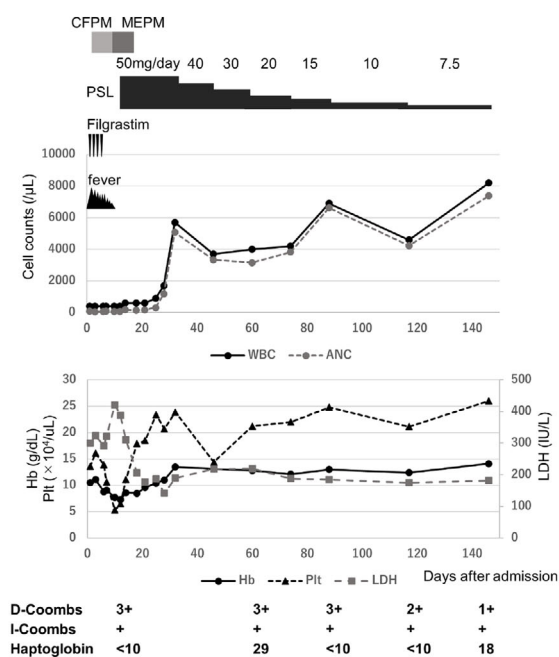


Figure 2. Clinical courses of case 1 (a) and case 2 (b). (a) The left and right figures show the clinical courses of the first 50 days after admission and 1 year after PSL administration, respectively. Both cases were refractory to granulocyte-colony-stimulating factor but promptly responded to prednisolone. CFPM: cefepime, PIPC/TAZ: piperacillin/tazobactam, MEPM: meropenem, PSL: prednisolone, PC: platelet concentrate, ANC: absolute neutrophil count, D-Coombs: direct Coombs test, I-Coombs: indirect Coombs test

day) in accordance with a standard AIHA treatment strategy.

Her anemia, lactate dehydrogenase (LDH) elevation, and thrombocytopenia promptly recovered, and after four days of PSL treatment, her neutropenia also gradually resolved.

Seventeen days post-PSL treatment (28 days post-admission), her neutrophil count rose to $1,173/\mu\text{L}$, and she was discharged. Her PSL dose has been tapered, with no relapse of pancytopenia. CT conducted 32 days post-PSL

Table 2. Laboratory Findings at Diagnosis of Case 2.

WBC	400 / μ L	T-Bil	1.0 mg/dL	CH50	56.8 U/mL
Band	0.0 %	AST	17 IU/L	ANA	$\times 160$
Seg	24.0 %	ALT	9 IU/L	Homo	$\times 160$
Eosino	2.0 %	LDH	300 IU/L	Speckled	$\times 160$
Baso	1.0 %	BUN	12.4 mg/dL	Anti-dsDNA IgG	<2.0 IU/mL
Mono	37.0 %	Cre	0.90 mg/dL	LA	1.12
Lym	36.0 %	Fe	19.4 μ g/dL	Anti-CL- β 2GPI Ab	<1.2 U/mL
RBC	355×10^4 / μ L	Ferritin	53.8 ng/mL	CL-IgG Ab	11 U/mL
Hb	10.5 g/dL	TIBC	271 μ g/dL	PA IgG	264
MCV	86.5 fL	Vit.B12	627 pg/mL	sIL2-R	1,470 U/mL
Plt	13.6×10^4 / μ L	Folic acid	11.1 ng/mL	D-Coombs	3+
Reti	50.0 %	IgG	1,572 mg/dL	I-Coombs	+
		IgA	289 mg/dL	Haptoglobin	<10 mg/dL
		IgM	31.7 mg/dL	Antineutrophil Ab	+
PT-INR	1.11			Anti- <i>H. pylori</i> IgG	<3
APTT	32.3 sec				
Fib	417 mg/dL	CD55+RBC	97.5 %		
FDP	5.1 μ g/mL	CD59+RBC	100 %		

CH50: 50% hemolytic complement activity, ANA: antinuclear antibody, Anti-ds DNA Ab: anti-double stranded DNA antibody, LA: lupus anticoagulant, Anti-CL- β 2GPI Ab: anti cardiolipin β 2- glycoprotein I complex antibody, CL-IgG Ab: anticardiolipin antibodies-IgG, PA IgG: platelet-associated IgG, sIL2R: soluble interleukin-2 receptor, D-Coombs: direct Coombs test, I-Coombs: indirect Coombs test

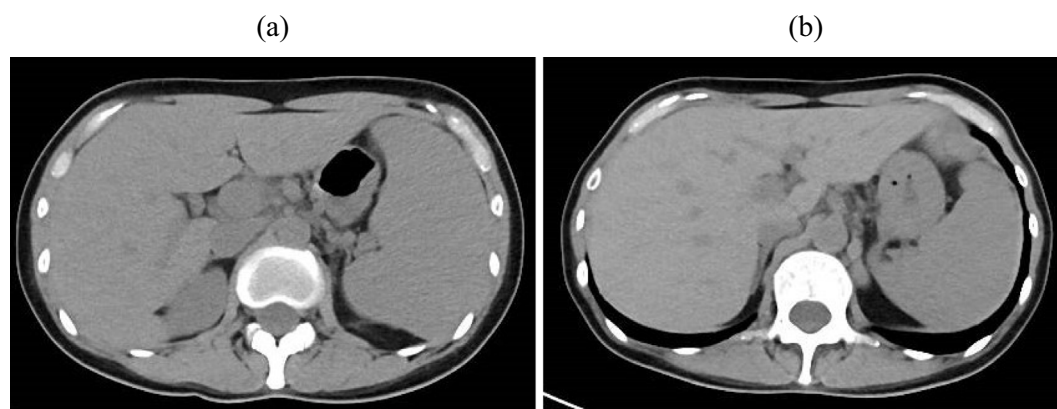


Figure 3. Computed tomography (CT) images at the diagnosis (a) and 32 days post-PSL treatment (b). The CT images showed some improvement in the patient's splenomegaly after PSL treatment.

treatment also showed some improvement in her splenomegaly (Fig. 3b).

Discussion

We diagnosed both cases with primary autoimmune pancytopenia based on their clinical courses and laboratory tests. Autoimmune cytopenia can be caused by various factors, such as collagen diseases, medications, infections, and lymphoid malignancies (2, 3). As the patient in case 2 was not taking any medications at the onset of pancytopenia, drug-induced pancytopenia was ruled out. The patient in case 1 had been taking allopurinol and pravastatin, which can both cause cytopenia; however, his antineutrophil antibody was positive, and his neutrophil count recovered after PSL induction, suggesting that his cytopenia had not been caused by these medications. We initially suspected that the

patient in case 1 had CMV infection, but the samples of CMV IgG and CMV antigenemia showed negative findings. To screen for collagen diseases that could cause secondary autoimmune cytopenias, in both cases, autoimmune antibodies were tested, and neither case met the criteria for common collagen diseases, such as systemic lupus erythematosus or rheumatoid arthritis.

It is relatively rare for a patient with adult primary AIN to also develop autoimmune cytopenia of other lineages (4, 5). The AIN in case 1 was complicated with AIT, and the patient's Coombs test results were positive without anemia. The AIN in case 2 was complicated with Evans syndrome. These results showed that both cases had autoimmune antibodies of three lineages.

Although a standard treatment strategy for AIN has not yet been established, treatments with G-CSF or steroids are commonly reported (2, 6-8). To compare the responses to

Table 3. Clinical Findings from Reported Cases of Adult Primary AIN without Other Lineages of Autoimmune Cytopenia.

PN	Age/Sex	Response to G-CSF	Immunosuppressive treatment	Response	Ref
1	75/F	Transiently R	PSL (40 mg/day)	R	6
2	90/F	Transiently R	PSL (1 mg/kg/day)	R	7
3	57/F	Not R	PSL (0.5 mg/kg/day)	R	8
4	63/F	Transiently R	PSL (1 mg/kg/day)	R	9
5	78/M	Not R	Dexa40 mg/day×4 days→PSL (15 mg/day)	Not R	10
6	22/M	Not R	PSL (2 mg/kg/day)+CyA (12 mg/kg/day)	R	11
7	35/M	Not R	PSL (100 mg/week)+CyA+Rituximab	Not R	12

PN: patient number, G-CSF: granulocyte-colony stimulating factor, R: responded (defined as neutrophil count above 1,500/ μ L, and no additional treatment was required), Transiently R: transiently responded (defined as a transient response that required further treatment), PSL: prednisolone, Dexa: dexamethasone, CyA: cyclosporin A, ref: reference

Table 4. Clinical Findings from Reported and Current Cases of Adult Primary AIN Complicated with AIT or Evans Syndrome.

PN	Age/Sex	Disease	1st line Tx	Response	2nd line Tx	Response	3rd line Tx	Response	Ref
8	73/F	AIN+Evans	Lenograstim	Transiently R	PSL (0.5 mg/kg/day)	R	N/A	N/A	13
9	48/F	AIN+Evans	PSL*	R	N/A	N/A	N/A	N/A	5
10	64/F	AIN+Evans	G-CSF+IVIG	Not R	Rituximab	R	N/A	N/A	14
11	31/M	AIN+Evans	PSL*+IVIG	Not R	CyA (10 mg/kg/day)	R**	N/A	N/A	5
12	48/F	AIN+Evans	Filgrastim	Not R	PSL (1.0 mg/kg/day)	R	N/A	N/A	C
13	69/M	AIN+AIT	PSL*	R	N/A	N/A	N/A	N/A	5
14	52/M	AIN+AIT	PSL (0.5 mg/kg/day)	Transiently R	PSL*+EPAG	Partially R****	N/A	N/A	15
15	70/M	AIN+AIT	PSL (1.0 mg/kg/day)	R	N/A	N/A	N/A	N/A	16
16	35/M	AIN+AIT	PSL (1.0 mg/kg/day)	Partially R***	IVIG+splenectomy	Partially R***	Rituximab	R	17
17	39/F	AIN+AIT	Dexa (0.75 mg/kg/day)	Partially R***	IVIG	Not R	Rituximab	Partially R***	17
18	67/M	AIN+AIT	Filgrastim	Not R	PSL (0.5 mg/kg/day)	R	N/A	N/A	C

Tx: treatment, PN: patient number, AIN: autoimmune neutropenia, Evans: Evans syndrome, R: responded [defined as effective for cytopenia of all lineages (Hb>12g/dL, Neutrophil>1,500/ μ L, Platelet>100,000/ μ L), and no additional treatment was required], Partially R: partially responded (defined as only effective for cytopenia of single lineage), Transiently R: transiently responded (defined as a transient response that required further treatment), N/A: not applicable, G-CSF: granulocyte-colony stimulating factor, IVIG: intravenous immunoglobulin, PSL: prednisolone, Dexa: dexamethasone, CyA: cyclosporin A, EPAG: eltrombopag, C: current case, ref: reference

*: Dose was not mentioned, **: Died of sepsis, ***: Only effective for platelet, ****: Platelet count achieved above 100,000/ μ L and neutrophil count remained above 500/ μ L.

steroid treatment between adult primary AIN cases both with and without other lineages of autoimmune cytopenia, a review of the literature was performed. We initially focused on adult primary AIN without other lineages of cytopenia, and using PubMed search, we found only seven case reports of primary AIN that had been treated with steroid-containing immunosuppressive agents (Table 3) (6-12). This is because, for cases of primary AIN, G-CSF is recommended as a first-line treatment, and high response rates have been reported (2). Therefore, there are relatively few available documented cases of primary AIN treated with steroids. Among these seven cases, four were refractory to G-CSF [Patient number (PN) 3,5-7], indicating that the cohort of these cases is not typical in terms of the G-CSF response. Regarding the efficacy of the steroid-containing immunosuppressive agents used in these seven cases, PSL was effective in four cases, and PSL plus cyclosporin A (CyA) was effective in one. The remaining two documented cases were refractory to steroid-containing immunosuppressive treatments

and were ultimately successfully treated with rituximab (PN 5) or alemtuzumab (PN 7).

We next conducted an examination of the characteristics of adult primary AIN complicated with AIT or Evans syndrome. As it is rare to encounter AIN complicated with AIT or Evans syndrome, there are not many case reports available. Upon searching PubMed, we found only nine documented cases of adult primary AIN complicated with AIT or Evans syndrome (Table 4) (5, 13-17), excluding the two present cases. Four were cases of AIN complicated with Evans syndrome (PN 8-11), and five were cases of AIN complicated with AIT (PN 13-17). In 10 of these 11 total cases (PN 8, 9, 11-18), steroids were used as a first- or second-line treatment. The blood cell counts considered to indicate efficacy were as follows: Hb >12 g/dL, neutrophils >1,500/ μ L, platelets >100,000/ μ L (18-20). The number of patients who showed a response (effective for cytopenia of all lineages, with no additional treatment required), partial response (only effective for cytopenia of a single lineage), or transient

response (transient response that required further treatment) were six (PN 8, 9, 12, 13, 15, 18), two (PN 16, 17), and one (PN 14), respectively. In the remaining case (PN 11), the patient did not respond to PSL but was effectively treated with CyA; however, he eventually died of septic complications. The patient who transiently responded to PSL (PN 14) was treated with a thrombopoietin receptor agonist (Eltrombopag) and his platelet count was above 100,000/ μ L. While his neutrophil count did not reach 1,500/ μ L, it remained above 500/ μ L without any infection. Rituximab was successful in treating two cases (PN 10, 16), one of which was only partially responsive to steroids (PN 16). G-CSF was administered in four cases (PN 8, 10, 12, 18), but only one case exhibited a transient response (PN 8), whereas the remaining three cases were unresponsive (PN 10, 12, 18). Although this is a review of a very limited number of case reports, there seems to be no marked difference in the efficacy of steroids between cases of adult primary AIN, both with and without other lineages of autoimmune cytopenia.

Concerning the two current cases (PN 12, 18), as G-CSF did not show any efficacy for neutropenia, we decided to use PSL. In case 1, the dose of PSL was 0.5 mg/kg/day, and in case 2, the dose was 1.0 mg/kg/day, in accordance with a standard AIHA treatment strategy (21). Case 1 showed neutrophil count recovery of over 500/ μ L by day 8 post-PSL administration, and case 2 showed the same result by day 17. In both cases, thrombocytopenia (and anemia, which was only present in case 2) resolved a few days earlier than the respective increases in neutrophil counts. In case 1, PSL was tapered and discontinued six months after starting, without any relapses of neutropenia and thrombocytopenia. The patient's direct Coombs test result was negative approximately six months after PSL induction, as was his antineutrophil antibody test result almost a year after starting PSL. In case 2, PSL has been tapered without any relapse of pancytopenia.

To establish an optimal treatment strategy, it is necessary to accumulate data acquired from not only clear-cut AIN cases but also those with AIT and/or AIHA complications.

The authors state that they have no Conflict of Interest (COI).

References

- Akhtari M, Curtis B, Waller EK. Autoimmune neutropenia in adults. *Autoimmun Rev* **9**: 62-66, 2009.
- Sicre de Fontbrune F, Moignet A, Beaupain B, et al. French severe chronic neutropenia registry. Severe chronic primary neutropenia in adults: report on a series of 108 patients. *Blood* **126**: 1643-1650, 2015.
- Capsoni F, Sarzi-Puttini P, Zanella A. Primary and secondary autoimmune neutropenia. *Arthritis Res Ther* **7**: 208-214, 2005.
- Bux J, Kissel K, Nowak K, Spengel U, Mueller-Eckhardt C. Autoimmune neutropenia: clinical and laboratory studies in 143 patients. *Ann Hematol* **63**: 249-252, 1991.
- Martino R, Muniz-Diaz E, Arilla M, et al. Combined autoimmune cytopenia. *Haematologica* **80**: 305-310, 1995.
- Imoto S, Hashimoto M, Miyamoto M, et al. Response to granulocyte colony-stimulating factor in an autoimmune neutropenic adult. *Acta Haematol* **101**: 153-156, 1999.
- Murphy PT, Casey MC. Unusual presentation of primary autoimmune neutropenia. *Br J Haematol* **107**: 214-215, 1999.
- Fujita M, Kawabata H, Oka T, et al. A rare case of adult autoimmune neutropenia successfully treated with prednisolone. *Intern Med* **56**: 1415-1419, 2017.
- Fujimi A, Matsunaga T, Ohnishi R, et al. Successful treatment with G-CSF and corticosteroid of adult idiopathic autoimmune neutropenia presenting as recurrent enterocolitis. *Rinsho Ketsueki* **43**: 998-1003, 2002 (in Japanese, Abstract in English).
- Hagihara M, Hua J, Inoue M, Michikawa N, Taniguchi K, Kobayashi M. Sustained complete remission for one year following low-dose rituximab therapy for chronic autoimmune neutropenia. *Rinsho Ketsueki* **52**: 63-67, 2011 (in Japanese, Abstract in English).
- Martino R, Sureda A, Ayats R, Muniz-Diaz E, Altes A, Brunet S. Successful treatment of chronic autoimmune neutropenia with cyclosporin A. *Haematologica* **79**: 66-69, 1994.
- Neerukonda AR, Lan F, Gabig T, Saraya T. Refractory adult primary autoimmune neutropenia that responded to alemtuzumab. *Intern Med* **55**: 1667-1670, 2016.
- Mitani S, Okubo Y, Nishi K, et al. Rapidly progressive autoimmune pancytopenia successfully treated with steroids. *Rinsho Ketsueki* **57**: 2324-2328, 2016 (in Japanese, Abstract in English).
- Provan D, Butler T, Evangelista ML, Amadori S, Newland AC, Stasi R. Activity and safety profile of low-dose rituximab for the treatment of autoimmune cytopenias in adults. *Haematologica* **92**: 1695-1698, 2007.
- Tokunaga M, Yamada M, Kondo A, et al. Neutrophil recovery by eltrombopag treatment in a patient with adult-onset autoimmune neutropenia and immune thrombocytopenia. *Rinsho Ketsueki* **59**: 310-314, 2018 (in Japanese, Abstract in English).
- Yabushita T, Hiramoto N, Ono Y, et al. Adult-onset primary cyclic autoimmune neutropenia: a case report. *Transfusion* **58**: 884-890, 2018.
- Faurschou M, Hasselbalch HC, Nielsen OJ. Sustained remission of platelet counts following monoclonal anti-CD20 antibody therapy in two cases of idiopathic autoimmune thrombocytopenia and neutropenia. *Eur J Haematol* **66**: 408-411, 2001.
- Hill QA, Hill A, Berentsen S. Defining autoimmune hemolytic anemia: a systematic review of the terminology used for diagnosis and treatment. *Blood Adv* **3**: 1897-1906, 2019.
- Dale DC, Bolyard AA. An update on the diagnosis and treatment of chronic idiopathic neutropenia. *Curr Opin Hematol* **24**: 46-53, 2017.
- Neunert C, Terrell DR, Arnold DM, et al. American Society of Hematology 2019 guidelines for immune thrombocytopenia. *Blood Adv* **3**: 3829-3866, 2019.
- Zanella A, Barcellini W. Treatment of autoimmune hemolytic anemia. *Haematologica* **99**: 1547-1554, 2014.

The Internal Medicine is an Open Access journal distributed under the Creative Commons Attribution-NonCommercial-NoDerivatives 4.0 International License. To view the details of this license, please visit (<https://creativecommons.org/licenses/by-nc-nd/4.0/>).