

[CASE REPORT]

Perigraft Abscess Subsequent to Aortoesophageal Fistula

Norie Takei¹, Takeshige Kunieda¹, Yoshitaka Kumada² and Masanori Murayama¹

Abstract:

A 79-year-old man with appetite loss and nausea for 1 month was admitted to our hospital. His thoracic aortic aneurysm had gradually increased in size due to perigraft endoleak after the previous aneurysm repair surgery. Although he showed no hematemesis, melena, or a fever, gastrointestinal endoscopy and contrast-enhanced computed tomography (CT) revealed an aortoesophageal fistula (AEF). He developed septic shock due to a perigraft abscess and eventually died, although aortic graft replacement and esophageal transection were performed. Clinical suspicion is the most important factor for obtaining an accurate diagnosis and improving the prognosis in cases of AEF.

Key words: aortoesophageal fistula (AEF), endoleak, perigraft abscess

(Intern Med Advance Publication)

(DOI: 10.2169/internalmedicine.0493-17)

Introduction

Aortoesophageal fistula (AEF) is a rare and often fatal complication after any aortic intervention. The clinical symptoms of AEF generally comprise hematemesis, chest pain, and a fever, but a substantial subset of patients show nonspecific clinical findings. This report describes a case of AEF without gastrointestinal bleeding or infectious symptoms that developed after aortic surgical reconstructions. Although a preoperative diagnosis was made, the patient ultimately died of septic shock due to a perigraft abscess. We discuss the proper diagnostic and therapeutic procedures to reduce the mortality of AEF.

Case Report

A 79-year-old man with a history of aortic reconstruction surgery was admitted to our hospital because of appetite loss and nausea. He had been diagnosed with thoracic and abdominal aortic aneurysms 15 years before admission at 64 years of age. Ten years later, at 74 years of age, he had undergone prosthetic replacement of the abdominal aorta by traditional open surgery. Four weeks after the operation, graft replacement of the thoracic aorta via median sternotomy was planned. Because his thoracic aneurysm ex-

tended to the arch, open surgery rather than thoracic endovascular aortic repair (TEVAR) was deemed suitable. However, his general condition worsened in the operating room, and he underwent the operation using the pull-through technique as a less-invasive procedure.

He received periodic follow-up examinations at the cardiovascular surgery section, and computed tomography (CT) showed that his thoracic aortic aneurysm had gradually increased in size due to perigraft leak (blood flow entry between the graft and the aneurysm), without ectopic gas or other findings. Because he had mild cognitive impairment and no symptoms, he did not want to receive any surgical treatments. He had been taking medication for hypertension, and his blood pressure was well-controlled. Over the past four weeks, he had reported appetite loss and nausea after eating. He occasionally vomited without hematemesis or melena. He also had an esophageal hiatal hernia that had been identified on gastrointestinal endoscopy one year before this admission. He had tried taking lansoprazole orally at 15 mg/day empirically, without relief. He also reported a weight loss of 6 kg/3 months and was referred to us for further investigation. He was afebrile and had no chest pain or abdominal pain. His history was also significant for chronic kidney disease and hypertension, for which he took telmisartan 40 mg/day and amlodipine 5 mg/day.

At the time of admission, the patient was 173 cm tall and

¹Department of General Internal Medicine, Matsunami General Hospital, Japan and ²Department of Cardiovascular Surgery, Matsunami General Hospital, Japan

Received: November 7, 2017; Accepted: April 10, 2018; Advance Publication by J-STAGE: July 6, 2018

Correspondence to Dr. Norie Takei, coco_nat_972@yahoo.co.jp

weighed 59 kg. On a physical examination, his temperature was 36.6 °C, blood pressure 131/85 mmHg, pulse rate 75 bpm, and respiration rate 16/min. His oxygen saturation was 98% on ambient air. There were no heart murmurs, and the lungs were clear. No carotid, subclavian, or abdominal bruits were present. An abdominal examination and the remainder of the physical examination findings were unremarkable.

Blood tests revealed hemoglobin 13.3 g/L, total leucocyte count 8,400/ μ L, erythrocyte sedimentation rate 2 mm/h, and C-reactive protein (CRP) 0.30 mg/dL. Other laboratory test results are shown in Table. Chest radiograph showed the marked widening of the mediastinum without pleural effusion or infiltration, which had not changed for more than one year (Fig. 1A). Contrast-enhanced CT revealed a dilated aorta 9.5 cm in diameter with ectopic gas adjacent to it (Fig. 1B). However, there were no air bubbles in the aortic arch, and we noted no other signs of infection around it (Fig. 1C). As his vital signs were stable and he did not desire to undergo an operation at that time, he was conservatively treated with parenteral nutrition and an intravenous antacid (omeprazole 40 mg/day) without improvement. On

the third day of admission, gastrointestinal endoscopy was performed. It showed bloody fluid in the esophagus and stomach but no active bleeding. Several ulcerations and fistulas were detected in the lower esophagus (Fig. 2), suggesting an aorto-esophageal fistula (AEF). He was started on intravenous antibiotic agents (cefmetazole 2 g/day). Elective surgery was considered, and he developed a low-grade fever with an elevated level of C-reactive protein (11.81 mg/dL) 3 days after an endoscope examination. Mild anemia (hemoglobin 10.8 g/L) and hypotension (86/69 mmHg) also developed without signs of gastrointestinal hemorrhaging or leukocytosis (total leucocyte count, 8,330/ μ L with 84.0% neutrophils). Chest CT showed fluid collection and multiple air bubbles in the thoracic aorta (Fig. 3), so he was diagnosed with septic shock due to thoracic aortic and prosthetic infections.

Left thoracotomy with subsequent aortic graft replacement and esophageal transection was performed as an emergency operation. Three fistulas between the aorta and the lower esophagus were noted during the operation, and a widespread perigraft abscess was observed in the thoracic aorta, with a strong odor. Blood and perigraft discharge culture yielded *Enterococcus faecium* and *Candida glabrata*. After the surgery, the patient was admitted to the intensive-care unit, and his antibiotics were changed from cefmetazole to daptomycin (350 mg/day) and meropenem (2 g/day) and clindamycin (1,200 mg/day). An antifungal agent (micafungin 150 mg/day) was also added, and mechanical ventilatory support was continued. The fever and elevation of CRP seemed to be transiently improved, but his sepsis relapsed within a few days. Although he was started on continuous hemofiltration and hemodialysis (CHDF) and administered adrenergic drugs, in addition to increasing the dose of micafungin, he developed renal failure and eventually died on the 16th day after surgery. The patient's clinical course is shown in Fig. 4.

Table. The Results of Laboratory Tests on Admission.

Complete blood count		Blood chemistry	
WBC	8,400 / μ L	TP	6.5 g/dL
Neutro	91.8 %	Alb	3.4 g/dL
Baso	0.2 %	T-bil	1.8 mg/dL
Eosino	0.1 %	AST	31 IU/L
Mono	2.5 %	ALT	20 IU/L
Lymph	6.4 %	LDH	452 U/L
RBC	457 $\times 10^4$ / μ L	γ -GTP	37 U/L
Hb	13.3 g/dL	Amylase	73 U/L
Ht	38.3 %	BUN	28 mg/dL
Plt	3.8 $\times 10^4$ / μ L	Na	145 mEq/L
ESR	2 mm/h	K	3.3 mEq/L
		Cl	106 mEq/L
		Glucose	140 mg/dL
		CRP	0.30 mg/dL

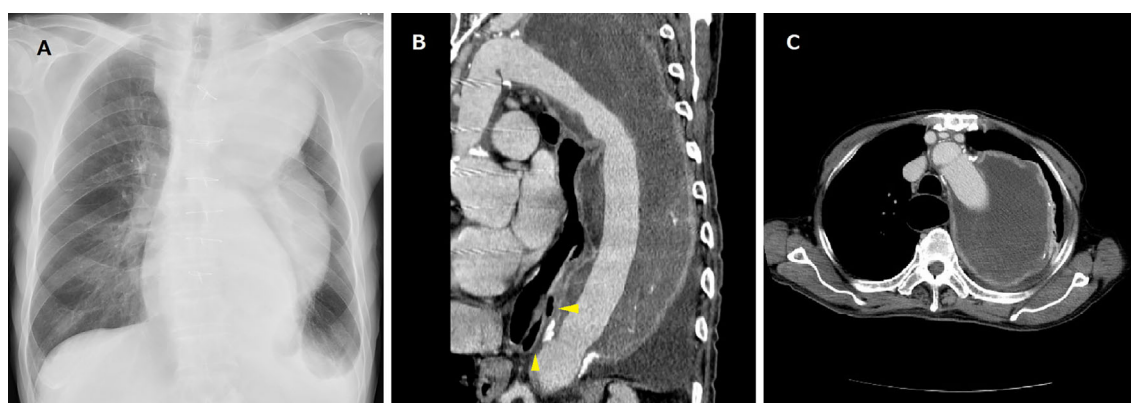


Figure 1. Chest radiograph (A) and contrast-enhanced CT (B, C) showing a markedly dilated thoracic aorta with ectopic gas (B, arrowheads) but without air bubbles in the aortic arch or any other signs of infection around it (C).

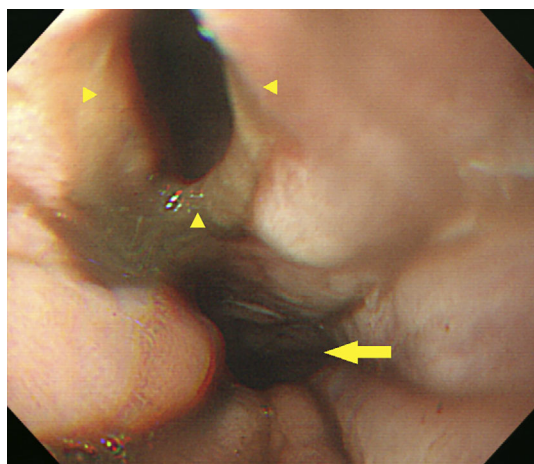


Figure 2. Upper gastrointestinal endoscopy showing a fistula (arrowheads) in the lower esophagus (arrow).

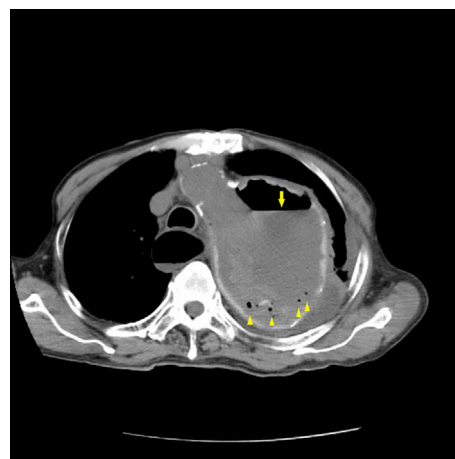

Figure 3. Chest CT showing a perigraft abscess with air bubbles (arrowheads) and fluid collection (arrow) in the thoracic aorta.

Discussion

AEF is a rare and often fatal complication that can occur following any aortic intervention. Its prevalence following aortic surgical reconstruction ranges from approximately 0.36% to 1.6% (1). Because of its rarity, the diagnosis of AEF is often difficult (3, 4). It is reported that the mean interval between the initial operation and symptom development is 59.5 months (5), and the rate of a diagnosis of AEF being made within 10 days of hospitalization is only 15% (6). Furthermore, the outcome of conservative management is almost invariably fatal, although both surgical and endovascular treatment are associated with high mortality. Therefore, the present report aimed to provide insight to further improve the prognosis of such a devastating condition.

The pathogenesis of AEF remains controversial, as both mechanical and infective factors may play important roles in its development. Repetitive mechanical damage due to arterial pulsation, esophageal wall circulation interruption by an enlarged aneurysm, and persistent vascular prosthesis infection are believed to cause AEF (7). A previous report described a case diagnosed with aortic prosthetic graft infection accompanied by aorto-enteric fistula after vascular surgery (2); however, in the present case, the thoracic aortic aneurysm had gradually increased in size because of a perigraft endoleak after aortic reconstruction without any sign of infection. Of note, it is extremely interesting that the patient's conditions started to worsen and he developed sepsis after the upper endoscope examination. We speculate that there were two causes of his deterioration: endoleak as well as infection occurring in relation to endoscopy.

Endoleak, which is defined as arterial perfusion outside the graft lumen and within the aneurysmal sac, has been well described after endovascular aortic repair (EVAR). The prevalence of endoleak in patient who underwent EVAR ranges from 8% to 44%, and its occurrence after open repair is much less common (8-10). The pull-through technique,

which was used for the aortic prosthesis implantation surgery of this patient, is recommended as a less-invasive alternative to conventional open surgery in select high-risk patients (11). It has also been reported that EVAR is superior to open repair due to its associated lower aneurysm-related death and major adverse events rates (8, 9, 12, 13). Although we found no literature describing AEFs after aortic repair surgery performed with the pull-through technique, any endovascular procedure could have caused the endoleak in the present patient. Once endoleak occurs, aortic aneurysms gradually increase in size, and continued pressurization of the aneurysm sac may also predispose a patient to AEF formation. We therefore believe that patients presenting with endoleak should always be closely followed up and recommended to undergo optimum surgical treatment as soon as possible.

The clinical symptoms of AEF generally comprise hematemesis, chest pain, and a fever. Patients with a history of aortic intervention who present with a fever and heightened inflammatory markers in addition to hematemesis should be strongly suspected of having AEF (14). One study reported that 94% patients with AEF had gastrointestinal hemorrhaging, and the remaining 6% presented with a fever or sepsis (15). In the present case, neither gastrointestinal hemorrhaging nor infectious symptoms were observed before admission. A substantial subset of patients demonstrate only nonspecific clinical findings, and the perigraft abscess in the present case might have been caused by endoscopy-associated gastrointestinal secretion leakage. We therefore speculate that, if the patient had undergone surgical treatment for an aortic aneurysm before this administration, then he might have survived. Moreover, if emergency surgery for AEF had been performed before the patient had developed sepsis, then he might also have recovered. For these reasons, surveillance and early intervention are necessary as part of the follow-up course in all cases of aneurysm repairs.

The most frequently employed diagnostic investigation for

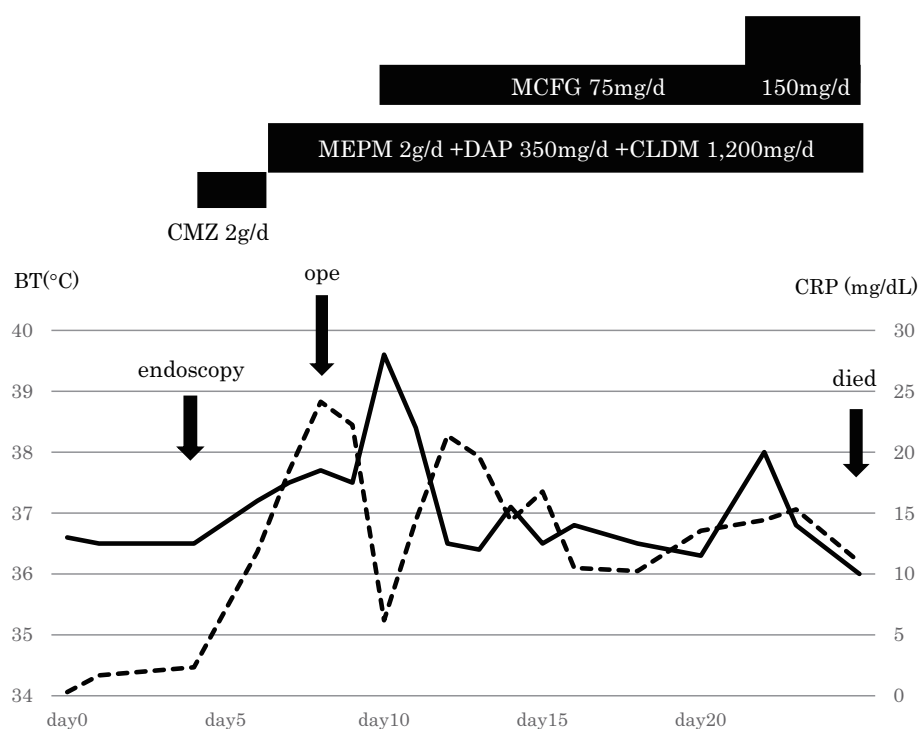


Figure 4. The clinical course of the patient. MCFG: micafungin, CMZ: cefmetazole, MEPM: meropenem, DAP: daptomycin, CLDM: clindamycin

AEF is an endoscopic examination of the upper gastrointestinal tract. CT with contrast enhancement can help obtain the diagnosis by showing signs suggestive of infection, such as the presence of intraluminal aortic gas or liquid surrounding the graft (16). However, because of their overlapping imaging features, AEF and perigraft infection may be difficult or impossible to differentiate. The diagnostic sensitivity of endoscopy and CT for AEF is 24% and 45%, respectively, and the combination of CT and diligent upper endoscopy possesses a high diagnostic accuracy (6). Because there is no single diagnostic investigation with very-high specificity and sensitivity, adjuvant techniques, such as CT angiography, gallium-67 scanning, or arteriography, are often used to detect AEF. As a novel approach to obtaining a correct diagnosis, the possibility of virtual endoscopy using CT has been reported (17). If the findings of these examinations are equivocal, a closer follow-up may help recognize AEF early.

Conservative management mainly consists of medical blockade of gastric acid with proton pump inhibitors and total enteral feeding via percutaneous gastrostomy to unburden the esophageal lesion. In addition, antibiotic treatment with or without antifungal agent is applied in cases accompanied by infection. Despite all efforts, AEF is nearly uniformly fatal without surgery. Particularly in the presence of infection, all infected and necrotic tissue must be debrided back to healthy tissue. In recent years, endovascular repair of AEF has been reported as a successful alternative to open surgery (10, 18). This approach is very useful for sealing the fistula and controlling bleeding, but unlike open repair with graft excision, the infected graft and/or aorta remains *in situ*.

This puts the newly implanted stent graft at risk for infection. Therefore, an endovascular approach has been suggested as a less-invasive method for temporarily managing AEF in unstable patients (18).

In conclusion, aggressive surgical treatment with aortic graft replacement following esophageal fistula repair/resection is the only definitive treatment for AEF, and the outcome depends upon the speed of the diagnosis, the patient's medical status, and the severity of infection. Avoiding a delay in the diagnosis is expected to further improve the outcome of AEF. Therefore, AEF must be kept in mind as a possible etiology of gastrointestinal bleeding, appetite loss, a chronic fever, and other nonspecific symptoms in patients with a history of aortic interventions. Furthermore, if they demonstrate an increase in the size of an aneurysm or an exacerbation of infection after an endoscopic examination, we should strongly recommend surgical treatment be performed as soon as possible.

The authors state that they have no Conflict of Interest (COI).

References

1. Kuestner LM, Reilly LM, Jicha DL, Ehrenfeld WK, Goldstone J, Stoney RJ. Secondary aortoenteric fistula: Contemporary outcome with use of extraanatomic bypass and infected graft excision. *J Vasc Surg* **21**: 184-196, 1995.
2. Amano M, Azuma T, Izumi C, et al. Aortic prosthetic graft infection accompanied with esophagomediastinal fistulas: A case report. *J Cardiol Cases* **6**: 51-54, 2012.
3. Geraci G, Pisello F, Li Volsi F, Facella T, Platia L, Modica G. Secondary aortoduodenal fistula. *World J Gastroenterol* **14**: 484-

- 486, 2008.
4. Iwaki T, Miyatani H, Yoshida Y, Okochi T, Tanaka O, Adachi H. Secondary aortoduodenal fistula without gastrointestinal bleeding directly detected by CT and endoscopy. *Radiol Case Rep* **7**: 774, 2012.
 5. Leon LR, Mills JL, Psalms SB, Kasher J, Kim J, Ihnat DM. Aortic Paraprothestic-colonic Fistulae: A Review of the Literature. *Eur J Vasc Endovasc Surg* **34**: 682-692, 2007.
 6. Pipinos II, Carr JA, Haithcock BE, Anagnostopoulos PV, Dossa CD, Reddy DJ. Secondary aortoenteric fistula. *Ann Vasc Surg* **14**: 688-696, 2000.
 7. Chiba D, Hanabata N, Araki Y, et al. Aorto-esophageal fistula after thoracic endovascular aortic repair diagnosed and followed with endoscopy. *Intern Med* **52**: 451-455, 2013.
 8. Frego M, Lumachi F, Bianchera G, et al. Risk factors of endoleak following endovascular repair of abdominal aortic aneurysm. A multicentric retrospective study, in vivo **21**: 1099-1102, 2007.
 9. Makaroun MS, Dillavou ED, Wheatley GH, Cambria RP. Five-year of endovascular treatment with the Gore TAG device compared with open repair of thoracic aortic aneurysms. *J Vasc Surg* **47**: 912-918, 2008.
 10. Stoneburner CG, Frey G, Hakaim AG. Endoleak after an open abdominal aortic aneurysm repair. *J of Vasc and Endovasc Surg* **1**: 1-4, 2016.
 11. Uchida T, Kim C, Oba E, et al. The Pull-through technique using the long elephant trunk for extensive thoracic aortic aneurysm. *Jpn J Vasc Surg* **21**: 663-668, 2012 (in Japanese, abstract in English).
 12. Walsh SR, Tang TY, Sadat U, et al. Endovascular stenting versus open surgery for thoracic aortic disease: systemic review and meta-analysis of perioperative results. *J Vasc Surg* **47**: 1094-1098, 2008.
 13. Cho JS, Haider SE, Makaroun MS. Endovascular therapy of thoracic aneurysms: Gore TAG trial results. *Semin Vasc Surg* **19**: 18-24, 2006.
 14. Eggbrecht H, Mehta RH, Dechene A, et al. Aorto-esophageal fistula after thoracic aortic stent-graft placement: a rare but catastrophic complication of a novel emerging technique. *JACC Cardiovasc Interv* **2**: 570-576, 2009.
 15. Yagi N, Akiyama H, Igaki N, et al. Two cases of aorto-gastrointestinal fistula. *Intern Med* **38**: 570-574, 1999.
 16. Kukora JS, Rushton FW, Cranston PE, et al. New computed tomographic signs of aortoenteric fistula. *Arch Surg* **119**: 1073-1075, 1984.
 17. Yoshimoto K, Shiiya N, Onodera Y, Yasuda K. Secondary aortoenteric fistula. *J Vasc Surg* **42**: 805, 2005.
 18. Xiromeritis K, Dalainas I, Stamatako M, Filis K. Aortoenteric Fistulae: Present-Day Management. *Int Surg* **96**: 266-273, 2011.
- The Internal Medicine is an Open Access article distributed under the Creative Commons Attribution-NonCommercial-NoDerivatives 4.0 International License. To view the details of this license, please visit (<https://creativecommons.org/licenses/by-nc-nd/4.0/>).