Cerebral Hemorrhagic Infarction after Radiation for Pituitary Adenoma

Satoko OGAKI, Seiji SUZUKI*, Hiroaki SUZUKI*, Masatsune SUZUKI, Hitoshi SHIMANO, Hideo TOYOSHIMA, Hirohito SONE, Yukichi OKUDA and Nobuhiro YAMADA

Abstract

We report a case of cerebral hemorrhagic infarction after radiation for pituitary adenoma. A 55-year-old woman was hospitalized to check for aldosteronism, post-operative pituitary function, and recurrence of thyroid cancer. She had short-term memory disturbance beginning two months prior to admission. Brain MRI showed a T1 and T2 high intensity lesion of her left anterolateral thalamus. Brain MRA revealed a narrowing in her left middle cerebral artery. The abnormal brain lesion was diagnosed as cerebral hemorrhagic infarction. She had received radiation therapy for pituitary adenoma 20 years earlier. It was considered that her cerebral hemorrhagic infarction was caused by radiation therapy.
(Internal Medicine 41: 834–838, 2002)

Key words: stroke, cerebral vasculopathy, radiotherapy

Introduction

Cerebral infarction following radiation therapy has rarely been reported (1–8). However, there were neurological symptomatic cases. Flickinger et al reported cerebral infarctions after radiotherapy in 7 of 156 patients irradiated for treatment of pituitary adenomas (10). We report a case in which radiation therapy was considered a cause of cerebral hemorrhagic infarction.

Case Report

A 55-year-old woman underwent removal of a non-functional pituitary adenoma (25 mm diameter) by the transsphenoidal approach, and radiation therapy (cobalt radiation 48 Gy in 15 fraction) twenty years previously. One month later, she received subtotal thyroidectomy for papillocarcinoma of the thyroid gland. Four years after the operation, adrenal insufficiency appeared. She had taken prednisolone (5 mg/day) for sixteen years. Three years previously, steroid-induced diabetes developed. Hypokalemia and hypertension appeared after removal of pituitary adenoma. Primary aldosteronism was suspected based on the results of a standing test with furosemide. However, abdominal CT showed no mass in her adrenal gland. She had short-term memory disturbance for two months prior to admission to our hospital in October 2000 for investigation of the cause of her memory disturbance.

The patient had a past history of cholecystolithiasis. Her family history was unremarkable. On admission, her height was 150 cm, her weight was 57.1 kg, and her body mass index was 25.4. Physical examination revealed a pulse of 75/min, and blood pressure of 120/76 mmHg. Her mental status was alert, and cranial nerves were normal. Her short-term memory was disturbed. Though she took potassium chloride, laboratory data showed hypokalemia (K 3.4 mEq/*l*) (Table 1).

Brain MRI showed a T1 and T2 high intensity lesion in her left anterolateral thalamus (Figs. 1A, B). The lesion had no mass effect and no edema. Brain MRA indicated that her left middle cerebral artery was narrowing (Fig. 2). She was diagnosed as having cerebral hemorrhagic infarction.

Endocrinological tests (Table 2) showed low LH and FSH concentrations. Her serum cortisol concentration was low (5.3 μg/dl at 8 AM), and urinary free cortisol concentration was low (15.3 μg/day). Renin concentration was low (0.1 ng/ml/h), and aldosterone concentration was within the normal limits (14.1 ng/dl). Her thyroid function was below the normal range (TSH 0.19 μU/ml, fT3 2.1 pg/ml, and fT4 0.97 ng/dl).

Before operation for pituitary adenoma, her cortisol response to hypoglycemia induced by insulin was low. The response of LH and FSH to LHRH test was normal before operation, but it became low after operation. We performed a CRH test and a GRH · TRH test in this case (Table 2). The cortisol response to CRH test was low, though the ACTH response was normal, as was the cortisol response to ACTH test. PRL, GH, and TSH responses to GRH · TRH test were low. We then performed

From the Department of Internal Medicine, Institute of Clinical Medicine, University of Tsukuba, Ibaraki and *the Department of Internal Medicine, National Hospital Tokyo Disaster Medical Center, Tokyo
Received for publication July 6, 2001; Accepted for publication May 7, 2002
Reprint requests should be addressed to Dr. Seiji Suzuki, the Department of Internal Medicine, National Hospital Tokyo Disaster Medical Center, 3256 Midori-cho, Tachikawa, Tokyo 190-0014

Table 1. Laboratory Data on Admission

Complete Blood Cell Count			
WBC	5,900/μl (Eo 0.9%)		
RBC	4.33×10^6/μl		
Hb	12.8 g/dl		
Hematocrit	38.0%		
Platelet	384×10^3/μl		
Urinalysis			
Specific gravity	1.017		
pH	6.0		
Protein	(–)		
Glucose	(–)		
Blood chemistry			
Total protein	8.1 g/dl	Urea nitrogen	13.9 mg/dl
Albumin	5.0 g/dl	Creatinine	0.6 mg/dl
Aspartate aminotransferase	35 U/*l*	Uric acid	4.6 mg/dl
Alanine aminotransferase	22 U/*l*	Total-cholesterol	162 mg/dl
Lactate dehydrogenase	212 U/*l*	High density lipoprotein	35.0 mg/dl
Alkaline phosphatase	244 U/*l*	Triacylglycerol	101 mg/dl
γ-glutamyl transpeptidase	23 U/*l*	Low density lipoprotein	103.0 mg/dl
Total-Bilirubin	1.5 mg/dl	C-reactive protein	0.07 mg/dl
Natrium	144 mEq/*l*	Lipoprotein (a)	25.3 mg/dl
Chloride	102 mEq/*l*	Blood glucose	82 mg/dl
Potassium	3.4 mEq/*l*	HbA1c	5.4 %

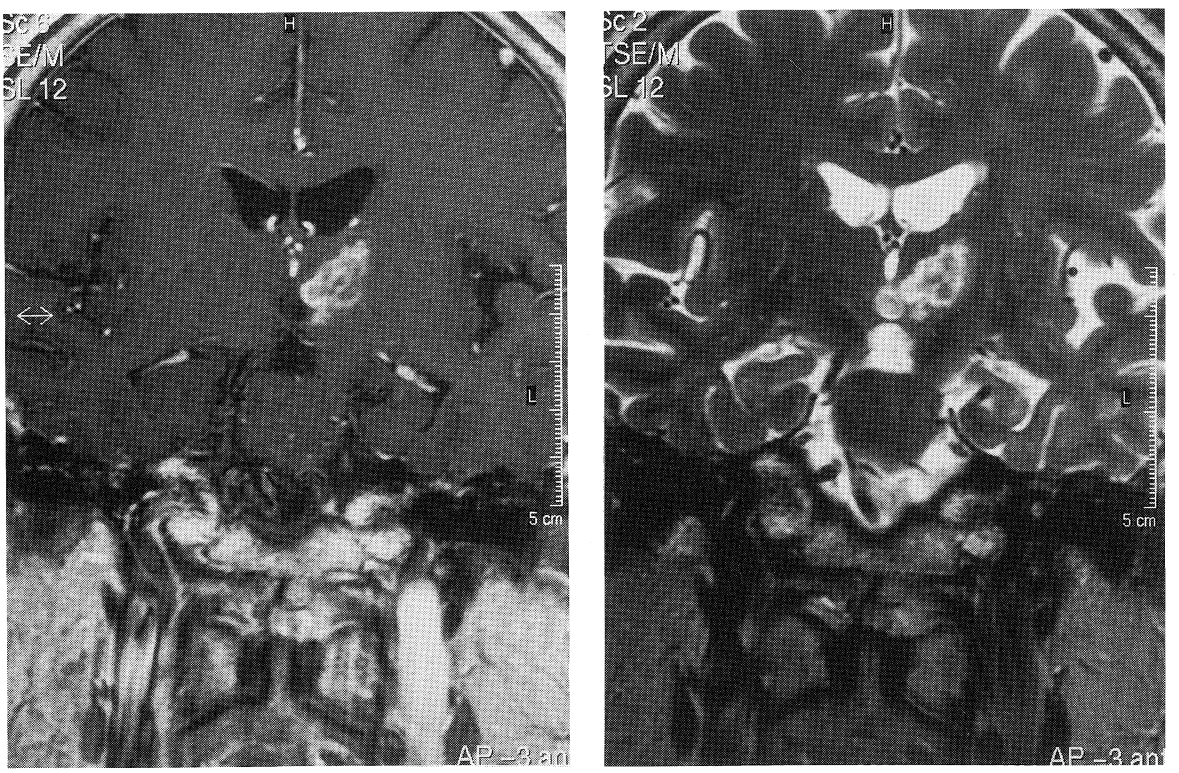

A B

Figure 1. Brain MRI of T1-weighted images (A) and T2-weighted images (B). T1 and T2 high intensity lesion is seen in her anterolateral thalamus.

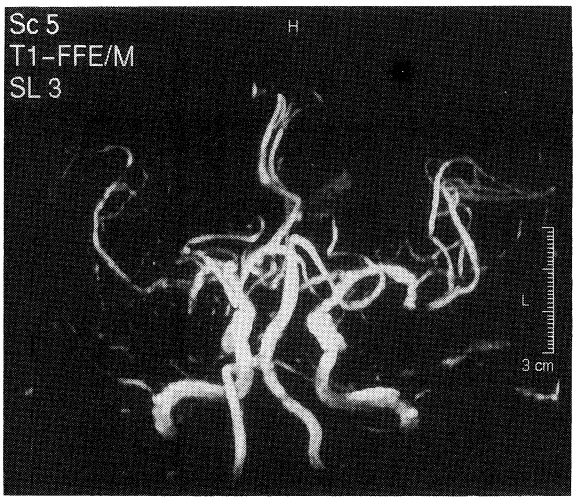

Figure 2. Brain MRA indicates a narrowing of her left middle cerebral artery as indicated by the arrow.

LHRH test for seven days. Her response showed improvement day by day. We determined the cause of the patient's hypopituitarism to be related to the hypothalamus.

Renin levels showed no response to the standing test using furosemide, nor to rapid ACTH test. Abdominal CT showed that her adrenal gland had no mass. But ^{131}I-adosterol scintigraphy indicated that both sides of her adrenal glands had unremarkable uptake. No difference was seen between blood samples taken from the right suprarenal vein and those taken from the left one. Based on these results, we concluded that she had idiopathic aldosteronism. Thyroid cancer (papillocarcinoma) was then found in her residual thyroid. She was discharged, but she will be admitted to our hospital again for surgery for thyroid cancer.

Discussion

Numerous documented reports have described cerebral vascular accidents in patients after radiation therapy to the brain (1–8), while some reports have described cerebral infarction after radiation for pituitary adenoma (2, 7, 8). Many of these reports documented arteriographic changes within the radiation portals. Strokes are a common problem in older patients. It is important to be alert to the possibility that radiation therapy might increase the risk for cerebral infarction.

Painter et al described four documented cases of cerebral vasculopathy after childhood radiation (1). Hirata et al described an arteriogram of a 10-year-old girl with amaurosis fugax showing Moyamoya syndrome after receiving 47 Gy at 1.5 Gy per fraction at 5 years of age for an optic glioma (2). Flickinger et al described a 10-year-old girl with hemiparesis and narrowing of the internal carotid artery after receiving 54 Gy at 1.8 Gy per fraction for an optic glioma at 6 years of age (3). Yamakami et al described a 7-year-old girl with cerebral ischemic attacks and narrowing of the anterior and middle cerebral arteries after receiving 40 Gy for a medulloblastoma at 3 years and 5 years of age (4).

Hirata et al described a 21-year-old woman with a suprasellar dysgerminoma who received 50 Gy in 25 fractions and in whom right hemiparesis developed 8 months later (2). Montanera et al described two cases of meningioma in which occlusive vasculopathy developed after radiation therapy (5). Groothuis and Mikhael described a 38-year-old man who received 50.4 Gy in 28 fractions to the left temporal lobe for Grade I astrocytoma in whom poor memory, aphasia, and right hemiparesis developed 2 years later due to a cerebral infarction (6). Lim et al described a 35-year-old man who received 40 Gy for pituitary adenoma in whom hemiparesis developed due to a cerebral right capsular infarction 4 years later (7). Hasegawa et al described a 15-year-old woman with pituitary adenoma who received 70 Gy and in whom transient ischemic attack with left sensory disturbance and narrowing of the right posterior cerebral artery developed 20 years later (8).

Hashimoto et al reported the long-term follow-up of 139 patients with pituitary tumors who had received radiation therapy. They described strokes occurring in ten patients after they received doses that varied between 50 and 60 Gy (9). Flickinger et al (10) reported the long-term follow-up of 156 patients with pituitary adenoma who received radiation therapy. They reported that the cumulative risk of stroke after radiation was 6% at 10 years, and 12% at 20 years. The expected risk of strokes for this population was 2% at 10 years, and 7% at 20 years. They reported that the cumulative risk of stroke by equivalent dose was 10% at 10 years in the higher dose group, and 12% at 20 years in the lower dose group. They described that the higher equivalent dose created a significantly greater risk of cerebral infarction (10).

In the present case, the patient received 48 Gy, which caused stenosis of the left middle cerebral artery to develop 20 years later. We did not perform cerebral angiography because we did not have the patient's consent. She had not previously undergone any tests regarding her cerebral arteries.

Cerebral vascular accidents in patients after radiation therapy to the brain are rare. The incidence of cerebral infarction generally increases as people age. There is no evidence that radiation therapy is the cause of cerebral infarction. However, there are some reports that the risk of stroke after radiation therapy is higher than that expected due to aging alone. It has been considered that radiation therapy influences cerebral infarction.

The present patient had taken prednisolone since 1984 for adrenal insufficiency after operation for pituitary adenoma. Steroid-induced diabetes developed in 1997. The dose of prednisolone she took was relatively high as a supplement dose. Her blood glucose control was not always optimum (HbA1c 7–9%). Her hypertension was controlled by manidipine. Her ocular fundus showed no change due to diabetes and hypertension. Hypertension and diabetes were risk factors for arterial sclerosis, but her duration of diabetes was short, her hypertension was well controlled by medication, and there were no re-

Table 2. Endocrinological Data

Blood chemistry					
Growth hormone (GRH)	0.1 ng/ml	(<5.0)	Free triiodothyronine (fT3)	2.1 pg/ml	(2.6–4.2)
Luteinizing hormone (LH)	0.2 mIU/ml	(4.2–79.6)	Free thyroxine (fT4)	0.97 ng/dl	(0.8–2.1)
Follicle-stimulating hormone (FSH)	1.2 mIU/ml	(12.6–235.7)	Cortisol	5.3 μg/dl	(6–18)
Prolactin (PRL)	20.1 ng/ml	(3.0–32.2)	Aldosterone	14.1 ng/dl	(3.0–15.9)
Adrenocorticotropic hormone (ACTH)	35.0 pg/ml	(7.1–53.8)	Renin	0.1 ng/ml/h	(0.2–2.7)
Thyroid stimulating hormone (TSH)	0.19 μU/ml	(0.3–4.0)			

Urinalysis		
Cortisol	15.3 μg/day	(30–150)
Aldosterone	6.57 μg/day	(≦ 10)
17-ketosteroids	2.34 mg/day	(2–9)
17-hydroxycorticosteroid	2.25 mg/day	(2–8)

Endocrinological test
Standing test with furosemide

	0'	30'	60'
Renin (ng/ml/h)	0.2	0.2	0.2
Aldosterone (ng/dl)	17.2	29.3	35.9

Rapid ACTH test

	0'	30'	60'
Cortisol (μg/dl)	8.1	13.9	15.1
Renin (ng/ml/h)	0.1	0.1	0.1
Aldosterone (ng/dl)	17.9	40.9	41.3

CRH test

	0'	15'	30'	60'	90'	120'
Cortisol (μg/dl)	6.6	9.7	10.8	11.8	9.7	10.2
ACTH (pg/ml)	38.0	80.4	79.7	74.4	61.7	55.3
Aldosterone (ng/dl)	14.8	24.1	26.8	23.1	23.3	20.3

GRH · TRH test

	0'	15'	30'	60'	90'	120'
GH (ng/ml)	0.1	0.8	1.6	2.8	2.4	1.4
PRL (ng/ml)	17.9	29.4	33.7	30.8	27.8	25.1
TSH (μU/ml)	0.31	1.07	1.60	2.34	2.64	2.70

LHRH test for seven days

	0'	15'	30'	60'	90'	120'
Day 0						
LH (mIU/ml)	0.2	0.2	0.2	0.3	0.4	0.4
FSH (mIU/ml)	1.3	1.3	1.4	1.6	1.7	1.9
Day 4						
LH (mIU/ml)	0.2	2.5	0.8	1.3	1.5	1.7
FSH (mIU/ml)	2.2	2.3	2.8	3.0	3.3	3.6
Day 7						
LH (mIU/ml)	0.3	0.8	1.4	2.3	2.7	3.0
FSH (mIU/ml)	3.3	3.2	3.7	4.4	4.7	5.6

markable diabetic or hypertensive changes in her retinal blood vessels. In addition, a brain MRI in 1998 showed no ischemic change. No atherothrombotic stenosis was found in her internal carotid artery or other systemic arteries. Diabetes is one of the risk factors for arteriosclerosis. Insulin resistance caused by obesity and steroid was considered to be influential in her cerebral hemorrhagic infarction. Yasaka et al reported that atherosclerosis of the major cerebral arteries is associated with smoking, hypertension, and low serum levels of HDL cholesterol. And, in patients with middle cerebral artery occlusion, occlusive lesions were commonly seen in the contralateral arteries (11). In the present patient although the influences of diabetes, hypertension, and insulin resistance were involved in the development of cerebral infarction, radiation was considered to be the most influential cause of her cerebral infarction.

In summary, we reported a case of cerebral hemorrhagic infarction after radiation therapy for pituitary adenoma. A number of cases of cerebral infarction after radiation therapy have been reported in the literature. The period between radiation therapy and the occurrence of cerebral infarction varies from 8 months to 20 years. There is no direct evidence linking radiation therapy to cerebral infarction. However, it is necessary to recognize the possibility of angiopathy, especially for long-term patients following radiation treatment.

References

1) Painter MJ, Chutorian AM, Hilal SK. Cerebrovasculopathy following irradiation in childhood. Neurology **25**: 189–194, 1975.
2) Hirata Y, Matsukado Y, Mihara Y, Kochi M, Sonoda H, Fukumura A. Occullusion of the internal carotid artery after radiation therapy for the chiasmal lesion. Acta Neurochir (Wien) **74**: 141–147, 1985.
3) Flickinger JC, Torres C, Deutsch M. Management of low-grade gliomas of the optic nerve and chiasm. Cancer **61**: 635–642, 1988.
4) Yamakami I, Sugaya Y, Sato M, Osato K, Yamaura A, Makino H. Diffuse stenotic changes in the large intracranial arteries following irradiation therapy for medulloblastoma; case report. No Shinkei Geka **18**: 1035–1039, 1990.
5) Montanera W, Chui M, Hudson A. Meningioma and occlusive vasculopathy: Coexisting complications of past extracranial radiation. Surg Neurol **24**: 35–39, 1985.
6) Groothuis DR, Mikhael MA. Focal cerebral vasculitis associated with circulating immune complexes and brain irradiation. Ann Neurol **19**: 590–592, 1986.
7) Lim YJ, Leem W, Park JT, Kim TS, Rhee BA, Kim GK. Cerebral infarction with ICA occlusion after Gamma Knife radiosurgery for pituitary adenoma: A case report. Stereotact Funct Neurosurg **72** Suppl 1: 132–139 1999.
8) Hasegawa S, Hamada J, Morioka M, Kai Y, Hashiguchi A, Ushio Y. Radiation-induced cerebrovasculopathy of the distal middle cerebral artery and distal posterior cerebral artery—case report. Neurogia medicochirurgica **40**: 220–223, 2000.
9) Hashimoto N, Handa H, Yamashita J, Yamagami T. Long-term follow-up of large or invasive pituitary adenomas. Surg Neurol **25**: 49–54, 1986.
10) Flickinger JC, Nelson PB, Martinez AJ, Deutsch M, Taylor F. Radiotherapy of nonfunctional adenomas of the pituitary gland: Results of long-term follow-up. Cancer **63**: 2409–2414, 1989.
11) Yasaka M, Yamaguchi T, Shichiri M. Distribution atherosclerosis and risk factors in atherothrombotic occlusion. Stroke **24**: 206–211, 1993