

CASE REPORT

Convulsive seizure and pulmonary edema during hyperbaric oxygen therapy : A case report

Kosai Cho¹, Takeya Minami¹, Yoshinori Okuno¹, Youhei Kakuda¹, Takahiko Tsutsumi¹, Toshiaki Kogame², Shigeru Ohtsuru¹, Norio Sato¹, and Kaoru Koike¹

¹Department of Primary Care and Emergency Medicine, Kyoto University Graduate School of Medicine ²Department of Dermatology, Kyoto University Graduate School of Medicine

Abstract : Hyperbaric oxygen therapy (HBOT) for carbon monoxide (CO) poisoning is widely performed to prevent delayed neuropsychiatric syndrome. Although HBOT can generally be performed with safety, the appropriate management of HBOT still remains unestablished. A 31-year-old man was transferred to our facility to undergo HBOT in a multiplace chamber with a diagnosis of CO poisoning. The first HBOT session ended uneventfully. During the second HBOT session, the patient suddenly experienced convulsive seizures. The accompanying doctor administered intravenous propofol to stop the convulsion and terminated the HBOT. Soon after the convulsion, the patient developed frothy secretions through the endotracheal-tube with impaired oxygenation. Head computed tomography scan showed no abnormalities, suggesting the seizure was associated with complications of HBOT. A chest X-ray revealed bilateral pulmonary edema, and echocardiography revealed normal cardiac function, indicating that the pulmonary edema resulted from HBOT or neurogenic mechanism secondary to the seizure. The patient's respiratory status improved without recurrence of the seizure and no delayed neurological sequelae was seen afterwards. Here we report unexpected rare adverse events during HBOT. Hyperbaric oxygen therapy for acute indications should be performed in multiplace chambers, with appropriate preparation and medical equipment. *J. Med. Invest.* 65 : 286-288, August, 2018

Keywords : hyperbaric oxygen therapy, carbon monoxide poisoning, multiplace chamber, convulsive seizure, pulmonary edema

INTRODUCTION

Carbon monoxide (CO) poisoning is one of the leading causes of poison-associated death (1). Although the treatment for CO poisoning is still not well-established and controversial, hyperbaric oxygen therapy (HBOT) appears to prevent delayed neuropsychiatric syndrome (2).

HBOT is generally safe and well tolerated, and the incidence of adverse events is reportedly quite low (3). We herein present a case with rare complications during HBOT and discuss the appropriate management of HBOT.

CASE PRESENTATION

A 31-year-old man without significant medical history was transported to the emergency department of a local hospital after being rescued from a fire in his apartment. The patient sustained no apparent burns on the body surface but had much soot in the nasal cavity, and bronchoscopy revealed swelling of the larynx, with serum carboxyhemoglobin level of 27.7%. The patient was diagnosed with inhalation injury and CO poisoning, and after endotracheal intubation he was transferred to our emergency department for the purpose of HBOT.

At our emergency department the patient was under sedation with Richmond Agitation-Sedation Scale of -1, with serum carboxy-

hemoglobin level of 3.7%. Significant neurological deficit could not be pointed out and no apparent seizures were seen. On the day of admission, the first HBOT session was carried out using Kawasaki KHO-302A (multiplace chamber), under the condition of 2.8 atmosphere absolute (ATA) for 90 minutes without any medical equipment like monitor or syringe pumps, which ended uneventfully (Figure 1).

On day 2, before the second HBOT session, the patient was almost alert with a Glasgow Coma Scale score of E4V6M6 and with stable respiratory status (Figure 2a). Laboratory exams and arterial blood gas analysis before the second session showed serum creatinine kinase level of 149 IU/L, serum carboxyhemoglobin level of 1.7%, partial pressure of oxygen level in arterial blood of 614.9 mmHg, and partial pressure of carbon dioxide level in arterial blood of 41.9 mmHg, respectively. Seventy minutes into the procedure under the condition of constant pressure of 2.8 ATA, the patient suddenly experienced a generalized tonic-clonic seizure. During the seizure the patient's radial artery was bilaterally well palpable. The accompanying doctor administered 30 mg of intravenous propofol to stop the convulsion and decided to terminate the HBOT session. During decompression, the patient developed frothy secretions through the endotracheal tube. After the second HBOT session, PaO₂/FiO₂ ratio of 68.1 in arterial blood gas indicated impaired oxygenation. Elevated serum creatinine kinase level of 671 IU/L and a serum lactate level of 64 mg/dL were both compatible with the occurrence of generalized seizures. Neither a serum creatine kinase-muscle/brain (CK-MB) nor cardiac enzyme levels were elevated. Chest X-ray revealed bilateral pulmonary edema (Figure 2b) and echocardiography showed normal cardiac function, indicating that the pulmonary edema resulted from HBOT, not from direct cardiovascular events; thus, the patient was placed on mechanical ventilation in the intensive care unit

Received for publication March 19, 2018 ; accepted March 26, 2018.

Address correspondence and reprint requests to Kosai Cho, M.D., Ph.D., Department of Primary Care and Emergency Medicine, Kyoto University Graduate School of Medicine, 54 Shogoin-kawaharacho, Sakyo-ku, Kyoto, 6068507, Japan and Fax : +81-75-751-4211.

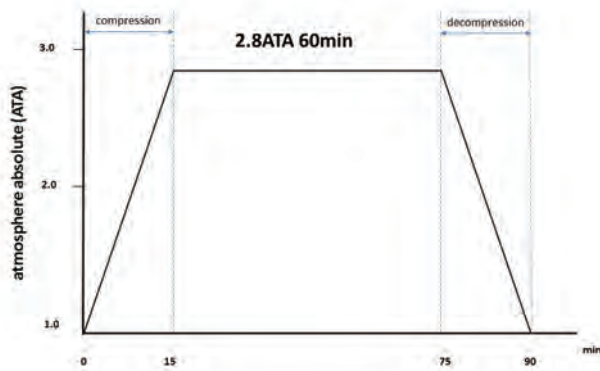


Figure 1

The treatment protocol of hyperbaric oxygen therapy for this case of CO poisoning - a total of 90 minutes procedure ; 2.8 ATA for 60 minutes and 15 minutes each for compression and decompression.

(ICU). Head computed tomography (CT) scan showed no abnormalities that could explain the convulsion (Figure 3). We decided not to perform any more HBOT sessions. Subsequently, seizures did not recur, and respiratory status improved without no significant signs of infection or allergy in a couple of days under conservative therapy (Figure 2c). The patient was discharged from the ICU on day 6 without any delayed neurological sequelae associated with CO poisoning afterwards.

DISCUSSION

We experienced a case of simultaneous convulsive seizure and pulmonary edema during HBOT. Pulmonary edema and convulsion during HBO rarely occur as separate events (4, 5), and their simultaneous occurrence has not been reported. The present case has two clinically significant implications.

First, an emergent HBOT should be performed in a multiplace chamber (6, 7). Well known major complications of HBOT include

barotrauma and oxygen toxicity (3), however, the exact mechanism underlying complication during HBOT is not fully established. The convulsive seizure in the present case is considered to be attributable to oxygen toxicity to the central nervous system because convulsion did not occur before the initiation of HBOT and recur after the cessation of HBOT, and there was no other apparent reason for the convulsion on the head CT image or physical examination. Although the direct action of CO poisoning could induce seizure, CO toxicity was not considered to the cause of the seizure in the present case since a serum carboxyhemoglobin level had been within normal range from the admission to our hospital and the patient did not present either any neurological deficit throughout the entire period or delayed neurological sequelae associated with CO poisoning afterwards. The etiology of pulmonary edema in the present case remains unclear but could possibly result from HBOT, because the echocardiogram and electrocardiogram both yielded normal findings, and no other apparent reasons for the pulmonary edema such as infection, allergic reaction were detected. The other possible cause is neurogenic pulmonary edema secondary to the seizure because neurogenic pulmonary edema can occur following generalized seizure (8). In addition to adverse side effects and complications directly associated with HBOT, various unexpected events could occur because those who require emergent HBOT are generally critically ill. Moreover, because an emergent HBOT is recommended within 24 hours after the exposure to CO poisoning (2), in many cases HBOT is initiated before completely grasping the patients' medical background. Therefore, HBOT for acute indications should be performed not in a monoplace chamber, but in a multiplace chamber, where a well-trained physician can accompany the patient to immediately detect subtle changes in their condition.

Second, medical equipment inside the hyperbaric chamber would lead to the safe and efficient management of patients undergoing HBOT. Although those who require emergent HBOT are critically ill and require monitoring or mechanical support, almost all medical devices are not permitted to be used under hyperbaric conditions due to safety concerns in Japan (7). Our facility, Kyoto University Hospital, equipped with a multiplace hyperbaric chamber for HBOT and receives referrals from many other hospitals in the Kansai area, does not have such medical equipment suitable for use under hyperbaric conditions. In contrast, medical equipment

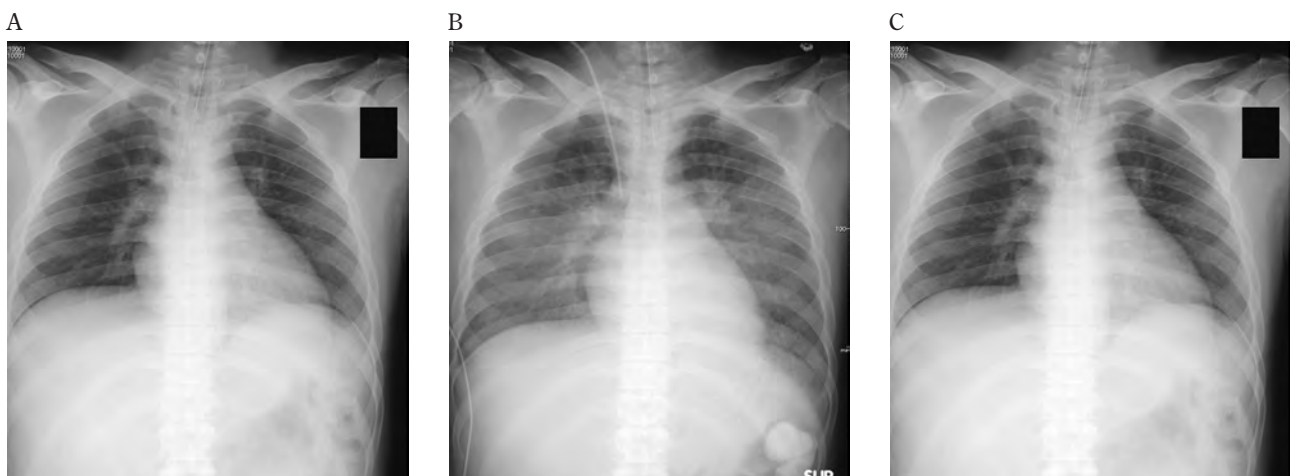


Figure 2

- Chest X-ray showed no abnormality just before HBOT on the second day after admission.
- Chest X-ray showed bilateral pulmonary edema without cardiomegaly just after termination of the second HBOT session.
- Chest X-ray showed improvement of the pulmonary edema 1 day after the second HBOT session.

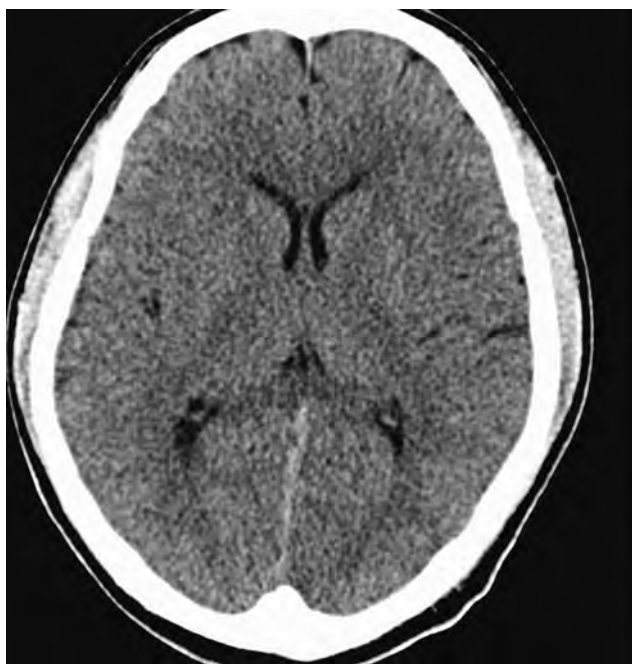

Figure 3
Head computed tomography scan revealed no abnormalities just after termination of the second HBOT session.

certified by manufacturers are widely used in European countries (9). Risk factors for seizures associated with HBOT include hypercapnia (4). In the present case we were forced to supervise the patient without any medical equipment like monitoring devices or syringe pumps. Mechanical monitoring of respiratory rate or capnometer would have prevented the occurrence of seizure in this case. Thus, sufficient medical equipment could be beneficial for the safe and efficient management of patients.

In Japan, many emergent HBOT sessions are forced to be performed in monoplace hyperbaric chambers because of a lack of multiplace hyperbaric chambers. We hereby propose placement of regional HBO centers, where a multiplace hyperbaric chamber, as well as medical equipment suitable for use under hyperbaric conditions are accessible from each region.

CONCLUSION

We present a rare case of simultaneous convulsive seizure and pulmonary edema during HBOT. Through this case, two significant clinical suggestions were obtained. First, HBOT for acute indications should be performed in multiplace chambers, so that accompanying physicians can treat the various expected and unexpected adverse events should they occur. Second, medical equip-

ment like monitoring devices or syringe pumps available under hyperbaric conditions should be introduced in Japan. As CO poisoning is one of the leading causes of poison-associated deaths, prompt improvement in the Japanese HBOT environment is required.

DISCLOSURE

The authors have no conflicts of interest to declare. Informed consent for publication of this case was obtained from the patient.

ACKNOWLEDGEMENT

We wish to thank Mr. T. Nitta from the Medical Equipment Department at Kyoto University Hospital for his technical advice.

REFERENCES

1. Rose JJ, Wang L, Xu Q, McTiernan CF, Shiva S, Tejero J, Gladwin MT : Carbon Monoxide Poisoning : Pathogenesis, Management, and Future Directions of Therapy. *Am J Respir Crit Care Med* 195 : 596-606, 2017
2. Weaver LK, Hopkins RO, Chan KJ, Churchill S, Elliott CG, Clemmer TP, Orme JF Jr, Thomas FO, Morris AH : Hyperbaric oxygen for acute carbon monoxide poisoning. *N Engl J Med* 347 : 1057-67, 2002
3. Jokinen-Gordon H, Barry RC, Watson B, Covington DS : A Retrospective Analysis of Adverse Events in Hyperbaric Oxygen Therapy (2012-2015) : Lessons Learned From 1.5 Million Treatments. *Adv Skin Wound Care* 30 : 125-129, 2017
4. Sanders RW, Katz KD, Suyama J, Akhtar J, O'Toole KS, Corl D, Ladenburger RN : Seizure during hyperbaric oxygen therapy for carbon monoxide toxicity : a case series and five-year experience. *J Emerg Med* 42 : e69-72, 2008
5. Weaver LK, Churchill S : Pulmonary edema associated with hyperbaric oxygen therapy. *Chest* 120 : 1407-9, 2001
6. Canadian Undersea and Hyperbaric Medical Association : Guidelines to the Practice of Clinical Hyperbaric Medicine and Provision of Hyperbaric Oxygen Treatment 2015. Available from : https://cuhma.ca/application/files/2814/7978/0661/CUHMA_Standards_of_Practice_Guidelines_1st_Edition.pdf
7. The Japanese Society of Hyperbaric and Undersea Medicine : Guidelines for Hyperbaric Oxygen Therapy version 1, 2005. Available from : http://square.umin.ac.jp/jachod/pdf/guide_line.ver1.pdf
8. Zhao H, Lin G, Shi M, Gao J, Wang Y, Wang H, Sun H, Cao Y : The mechanism of neurogenic pulmonary edema in epilepsy. *J Physiol Sci* 64 : 65-72, 2014
9. Kot J : Medical equipment for multiple hyperbaric chambers part I : Devices for Monitoring and Cardiac Support. *Europ J Underwater Hyperbaric Med* 6 : 115-120, 2005