Advance Publication

The Journal of Veterinary Medical Science

Accepted Date: 28 November 2021

J-STAGE Advance Published Date: 13 December 2021

©2021 The Japanese Society of Veterinary Science
Author manuscripts have been peer reviewed and accepted for publication but have not yet been edited.

Internal Medicine

Full paper

Diffusion tensor imaging-based quantitative analysis of the spinal cord in Pembroke Welsh Corgis with degenerative myelopathy

Eiji Naito[1], Kohei Nakata[2], Hiroki Sakai[1], Osamu Yamato[3], Md Shafiqul Islam[3], Sadatoshi Maeda[1, 2] and Hiroaki Kamishina[1, 2]*

[1]Joint Graduate School of Veterinary Sciences, Gifu University, Gifu 501-1193, Japan

[2]The Animal Medical Center of Gifu University, Faculty of Applied Biological Sciences, Gifu University, Gifu 501-1112, Japan

[3]Joint Faculty of Veterinary Medicine Kagoshima University, Kagoshima 890-8580, Japan

*** Correspondence:**

Corresponding author: Hiroaki Kamishina

E-mail: kamicna@gifu-u.ac.jp

Running head: DTI-BASED ANALYSIS IN DOGS WITH DM

ABSTRACT

Canine degenerative myelopathy (DM) is a progressive neurodegenerative disease of the spinal cord. The diagnosis is based on the observation of clinical signs, genetic testing, and exclusion of other spinal cord diseases, and a definitive diagnosis of DM can only be confirmed by postmortem histopathological findings. The aim of this study was to investigate the diagnostic ability of diffusion tensor imaging (DTI) for DM. Eight DM-affected Pembroke Welsh Corgis, thirteen dogs with thoracolumbar intervertebral disk herniation (IVDH), and six healthy control dogs were included. All dogs were scanned using a 3.0-T MRI system. Apparent diffusion coefficient (ADC) and fractional anisotropy (FA) values were calculated for each intervertebral disk level slice between T8-T9 and L2-L3 intervertebral disk levels, and the entire area of the thoracolumbar spinal cord between T8-T9 and L2-L3 intervertebral disk levels (T8-L3 region). The ADC and FA values of the T8-L3 region were significantly lower in the DM group than in the IVDH group. The ADC values for the T8-L3 region had a moderate negative correlation with clinical duration (r_s = -0.723, P = 0.043); however, the FA values of other intervertebral disk levels and T8-L3 region had no correlation with clinical durations. The measurement of DTI indices can be used to quantitatively assess neurodegeneration and may have diagnostic value for DM. In particular, the ADC value of the T8-L3 region may aid in making a non-invasive premortem diagnosis of DM.

Key words: degenerative myelopathy, diffusion tensor imaging, dog, MRI, thoracolumbar spinal cord

INTRODUCTION

Canine degenerative myelopathy (DM) is a fatal neurodegenerative spinal cord disorder that develops in several breeds, including German Shepard dogs, Boxers, and Pembroke Welsh Corgis (PWC) [2, 10]. Mutations in the Cu/Zn-superoxide dismutase 1 (SOD1) gene have been identified in DM dogs [3, 39]. Age at the onset of clinical signs is 8 years or older in most cases [39]. The initial clinical signs of DM are upper motor neuron spastic paresis of the pelvic limbs, which gradually progresses to flaccid tetraplegia. Eventually, affected dogs usually die from respiratory impairment 3 years after disease onset if euthanasia is not selected during the course of disease progression [10, 29].

Currently, a definitive diagnosis of DM can only be confirmed by postmortem histopathological findings [2, 16, 23]. The clinical diagnosis of DM is based on the following criteria: confirmation of the progression of clinical signs, identification of reported SOD1 mutations, and exclusion of other progressive spinal cord disorders that clinically mimic DM [8, 39]. However, acquired compressive spinal cord disorders can co-exist with DM, confounding the clinical diagnosis. Therefore, the clinical diagnosis of DM with acquired compressive spinal cord disorders is difficult at the time of MRI examination and can only be distinguished based on the observation of subsequent long-term clinical signs. For an earlier and more accurate premortem diagnosis, novel diagnostic tools that can discriminate DM from acquired

compressive spinal cord disorders are needed.

The pathological changes in the DM spinal cord are characterized by axonal degeneration, axonal loss, and demyelination of the white matter in the cervical, thoracic, and lumbar spinal cord in the presence of proliferated fibrous and gemistocytic astrocytes [3, 9, 23, 25]. Although these marked histopathological changes occur at every part of the spinal cord [10], conventional magnetic resonance imaging (MRI) techniques fail to depict DM lesions [28]. Diffusion tensor imaging (DTI), which enables *in vivo* quantification of water movement, provides quantitative information on axonal organization in the spinal cord [35]. Measurement of the apparent diffusion coefficient (ADC) and fractional anisotropy (FA) values, which are calculated from diffusion-weighted imaging data, has been utilized for the assessment of many neurodegenerative diseases in humans [24]. In a study of amyotrophic lateral sclerosis (ALS), a known human neurodegenerative disorder, FA measurement in the spinal cord was reported as a promising diagnostic technique [30]. In addition, DTI parameters may have predictive value for the survival time and progression rate of respiratory dysfunction in ALS patients [14, 32]. In dogs, spinal cord injury and spinal cord tumors have been investigated by a DTI sequence [20]. A recent study reported that the FA values of the spinal cord in DM was significantly lower than that in healthy control dogs [15]; however, there is no report of DTI-based quantitative analysis of the spinal cord in DM compared with acquired compressive spinal cord disorders.

The aim of the current study was to investigate the diagnostic ability of DTI for DM. We acquired DTI with a 32-direction motion probing gradient using a 3.0-Tesla MRI system, and measured FA and ADC values for the thoracolumbar spinal cord (TLSC) in DM, intervertebral disk herniation (IVDH), and healthy control dogs. Dogs with IVDH was included in this study because IVDH is the most common cause of hindlimb paralysis that needs to be differentiated from DM. We hypothesized that the FA values in DM dogs are lower than those in SCI and healthy control dogs because of the anisotropic reduction in the DM spinal cord due to axonal loss and demyelination. We also hypothesized that the ADC values in DM dogs are lower than those in SCI and healthy control dogs because of restricted movement of water molecules in the DM spinal cord, which is associated with the high cellularity of proliferated fibrous and gemistocytic astrocytes.

MATERIALS AND METHODS

Animals

This study was conducted as a retrospective cross-sectional study. In order to compare the DTI profile of dogs among DM, IVDH, and healthy control groups, this study included dogs that underwent an MRI sequence at the Animal Medical Center of Gifu University between August 2019 and January 2021. All owners signed an informed consent form (approved by the Animal Medical Center of Gifu University and Use Committee, protocol

2019-113). In the DM group, dogs were diagnosed with DM according to the following criteria: clinical signs consistent with DM (adult onset, slowly progressive, and non-painful paraparesis progressing to tetraplegia) [9, 10], unremarkable findings on spinal cord imaging with conventional MRI sequences, and genetic testing confirming homozygosity for the *SOD1* c.118G > A missense mutation (A/A) [8]. Dogs with IVDH, which had clinical signs consistent with DM and *SOD1* gene mutation at the time of MRI, were included in the DM group if these dogs had progressive clinical signs consistent with DM for more than a year at the time of data analysis. We also included postmortem imaging data in the DM group if the dogs underwent the DTI sequence within 24 hr after death and necropsy. The owners of the dogs were instructed to store the dogs in a cool condition and place refrigerants over the entire spine in order to minimize postmortem changes until they bring the dogs to us. The disease stage of DM was classified into four clinical stages as previously described [9, 10]. Briefly, clinical stages were characterized as follows: Stage 1, general proprioceptive ataxia and upper motor neuron paraparesis; Stage 2, non-ambulatory paraparesis to paraplegia; Stage 3, lower motor neuron paraplegia to thoracic limb weakness; and Stage 4, lower motor neuron tetraplegia and brain stem signs. All dogs in the IVDH group had thoracolumbar spinal cord compression by herniated intervertebral disks, which were confirmed by MRI (Achieva dStream, Philips, Amsterdam, Netherland). Thoracolumbar IVDH cases were graded into five grades as

112 previously described [1, 33]. Briefly, the clinical grading of thoracolumbar IVDH was as
113 follows: Grade 1, thoracolumbar pain only; Grade 2, ambulatory paraparesis; Grade 3, non-
114 ambulatory paraparesis; Grade 4, paraplegia with positive deep pain sensation; and Grade 5,
115 paraplegia with a loss of deep pain sensation. Clinically normal adult dogs with no abnormal
116 findings on spinal cord imaging with conventional MRI sequences were recruited for the control
117 group. Dogs were diagnosed with IVDH according to the following criteria: identification of
118 interruption of the CSF flow at dorsal and ventral site and/or deformity of the cross-sectional
119 area of the spinal cord, which were caused by spinal cord compression. All dogs in the control
120 group had normal neurological examination findings and no history of neurological disorder.
121 Exclusion criteria of this study for the DM or IVDH group were as follows: dogs with an
122 incomplete diagnosis, intracranial disorders, vertebral/spinal cord tumors, and no intramedullary
123 or intradural extramedullary structural lesions. All dogs of these MRI studies were included in a
124 previous study [27].

125 *MRI sequences*

126 All MRI sequences were acquired using a 3.0-Tesla MRI system (Achieva dStream,
127 Philips, Amsterdam, Netherland) with an 8-channel coil as an RF coil. For MRI procedures,
128 general anesthesia was induced with intravenous propofol (PROPOFOL injection, Fuji Pharma
129 Co., Ltd., Toyama, Japan). All dogs were intubated and maintained with a mixture of isoflurane

(Isoflurane, Pfizer Inc., New York, U.S.A: NY) in oxygen and room air under controlled respiration using a ventilator. All imaging examinations were performed in a supine position. The protocol consisted of a sagittal and transverse T1-weighted sequence (repetition time [TR]/echo time [TE] 570/13.8 msec; slice thickness 1.5 mm), T2-weighted sequence (TR/TE 3113/90 msec; slice thickness 1.5 mm), and contrast enhanced T1-weighted sequence after the intravenous injection of 0.1 mmol/kg of gadodiamide hydrate (OMNISCAN, Daiichi-Sankyo, Tokyo, Japan). Diffusion tensor imaging sequences were acquired from the T8-T9 intervertebral disk level to the L2-L3 intervertebral disk level. The protocol consisted of transverse DTI sequences (TR/TE 5571/70 msec; slice thickness 2 mm; diffusion gradient encoding in 32 directions; b value 1,000 sec/mm^2; field of view 250 x 250 mm; scan time 5 min).

Image analysis

Conventional MRI sequences were used to identify relevant anatomy. All measurements were performed by E.N. who was a practicing veterinarian who received training in veterinary radiology and neurology for seven years. FA and ADC maps were created using the package built into the MRI system, and the post-processed DTI images were overlaid with the T2-weighted images to correctly detect the spinal cord. In order to measure the FA and ADC values, eight regions of interest (ROIs) were placed manually at transverse images on each intervertebral disk level slice from T8-T9 through L2-L3 (Figure 1). All ROIs were set to

include more than 18 voxels with special care not to include cerebrospinal fluid as much as possible. All DTI data were analyzed using the workstation built into the MRI system to obtain FA and ADC values. DTI data of the TLSC region (T8-L3 region) were acquired from the nerve fiber bundles of the spinal cord passing through T8-L3, and the ADC and FA values of the entire visualized fibers were averaged and calculated.

Statistical analysis

Statistical analyses were performed using Easy R software [17]. The ADC and FA values were compared among DM, IVDH, and healthy control groups using the Kruskal-Wallis test. Post hoc comparisons employed the Mann-Whitney *U* test with Bonferroni correction. The correlation coefficient (r_s) was calculated by evaluating the correlation between the DTI parameters and clinical duration of DM by Spearman's rank correlation coefficient. We defined clinical duration as the time from the date of clinical onset first noted by the owner to the date of MRI. In all analyses, a P value of <0.05 was considered significant. The correlation coefficients of >0.8 were defined as a strong correlation and 0.6–0.8 were defined as a moderate correlation [7].

RESULTS

Sample characteristics

The characteristics of all dogs are shown in Table 1. We included eight DM-affected

166 PWCs in the DM group. Clinical stages of DM were stage 1 in 4 dogs and stage 4 in 4 dogs.
167 Four PWCs, which were categorized as stage 4, underwent MRI within 24 hr of death (Dog #1,
168 2, 3, 4). These dogs were diagnosed with DM based on histopathological examination of the
169 spinal cord. There was one intact female and three castrated males. The other four PWCs were
170 presumptively diagnosed with DM according to the inclusion criteria. Although four dogs had
171 IVDH lesions, all four dogs had progressive clinical signs at least a year, which were
172 inconsistent with IVDH. Therefore, all four dogs were diagnosed as DM. There were two
173 castrated males and two spayed females. The median age and body weight of dogs in the DM
174 group was 14.1 years (range; 11.0-15.9 years) and 12.1 kg (range; 10.1-14.6 kg), respectively. In
175 the DM group, the locations of IVDHs were T13-L1 (n=4), T12-T13 (n=2), L1-L2, and L2-L3
176 (n=1). In the IVDH group, we included thirteen dogs diagnosed with thoracolumbar
177 intervertebral disk herniation. Neurological grades were as follows: grade 1 (n=2), grade 2
178 (n=2), grade 3 (n=3), grade 4 (n=4), and grade 5 (n=2). The locations of IVDHs were T13-L1,
179 L2-L3 (n=6), T12-T13 (n=4), T11-T12, L1-L2 (n=2), and L3-L4, L4-L5, L5-L6, L6-L7 (n=1,
180 each). The number of disk herniation sites in the IVDH group was one (n=8), two (n=2), three
181 (n=1), four (n=1), and five (n=1) (Table 1). There were two intact females, two spayed females,
182 five intact males, and four castrated males. The median age and body weight of the dogs in the
183 IVDH group was 10.1 years (range; 3.5-11.9 years) and 5.6 kg (range; 3.4-10.7 kg) ,

184 respectively. Included breeds were Miniature Dachshund (n=8), crossbreeds (n=2), Toy Poodle
185 (n=1), Pug (n=1), and Miniature Pinscher (n=1). Surgical treatment was performed in 10 dogs,
186 and non-surgical treatment was selected in 3 dogs. All dogs improved their clinical signs. In the
187 healthy control group, we included six dogs. Four dogs were laboratory animals at Gifu
188 University, and two dogs were client-owned dogs. Three laboratory dogs in control group had
189 no structural lesions in the central nervous system. One laboratory dog was diagnosed with
190 idiopathic epilepsy. Two client-owned dogs in the control group had transient limb ataxia but no
191 structural lesions in the central nervous system. There were three spayed female and three
192 castrated males. The median age and body weight of the dogs in the healthy control group was 4
193 years (range; 4-10 years) and 12.9 kg (range; 10.6-16.8 kg), respectively. Included breeds were
194 Beagle (n=4), PWC (n=1), and crossbred (n=1).

195 *ADC values in DM, IVDH, and control groups*

196 The absolute measurement of DTI parameters and results of statistical analyses were
197 presented in Table 2, Figure 2, and Figure 3. Among the three groups, there were significant
198 differences in ADC values at T10-T11, T12-T13, L1-L2, and L2-L3 intervertebral disk levels
199 (P=0.024, 0.007, 0.027, 0.017, and 0.007, respectively). The ADC values at T10-T11, T12-T13,
200 T13-L1, L1-L2, and L2-L3 intervertebral disk levels were significantly lower in the DM group
201 than in the control group (P=0.038, 0.004, 0.041, 0.038, and 0.024, respectively). The ADC

values at L1-L2 intervertebral disk level was significantly lower in the DM group than in the IVDH group (P=0.038). The ADC values for the T8-L3 region were also significantly different among the three groups (P<0.001). The ADC values for the T8-L3 region were significantly lower in the DM group than in the control and IVDH groups (P=0.002 and P<0.001).

FA values in DM, IVDH, and control groups

Among the three groups, there were no significant differences in the FA values among the three groups in each slice between T8-T9 and L2-L3 intervertebral disk levels. The FA value of the T8-L3 region was significantly different among the three groups (P=0.004). The FA value of the T8-L3 region were significantly lower in the DM group than in the control and IVDH group (P=0.024 and 0.006).

DTI parameters in DM dogs with different clinical duration

The ADC and FA values of DM stage 1 and stage 4 are shown in Table 3. The ADC values at T8-T9, T9-T10, T11-T12, T13-L1, L1-L2, and L2-L3 intervertebral disk levels were found to have strong or moderate negative correlations with clinical durations, especially the ADC value at T13-L1 was found to have the strongest negative correlation (r_s = -0.873, P = 0.011). The ADC values for the T8-L3 region had a moderate negative correlation with clinical duration (r_s = -0.723, P = 0.043). The FA value at T8-T9 intervertebral disk level had a strong negative correlation (r_s = -0.819, P = 0.013), but the FA values of other intervertebral disk levels

220 and T8-L3 region had no correlation with clinical durations.

221 *DTI parameters in IVDH dogs with different clinical grades*

222 In all intervertebral disk levels and T8-L3 region, the ADC values had no significant
223 correlation with clinical grades of IVDH. Similarly, The FA values of all intervertebral disk
224 levels and T8-L3 segment had no significant correlation with clinical grades of IVDH.

225 **DISCUSSION**

226 The present study revealed that ADC and FA values of the T8-L3 region were
227 significantly decreased in DM group compared with those in control and IVDH groups.
228 Especially, ADC value of T8-L3 region may be a potential biomarker for distinguishing DM
229 from IVDH. Moreover, ADC values were negatively correlated with clinical grades in DM. As
230 neurodegeneration of the spinal cord in dogs with DM is not visualized by conventional MRI
231 sequences, DTI parameter has a potential to be used as a non-invasive diagnostic test for DM.

232 In this study, the ADC value of the T8-L3 region in the DM group was significantly
233 lower than that in the IVDH group. The ADC value is a parameter obtained based on restriction
234 of the movement of extracellular water molecules. In humans, it is used for diagnosis, treatment
235 monitoring, and assessing the prognosis of spinal cord diseases such as ALS [14, 30, 32],
236 cervical spondylotic myelopathy [5, 11], compressive myelopathy [21, 38], multiple sclerosis
237 [4, 19], and spinal cord injury [34]. In spinal cord diseases in dogs, ADC values in the lesions of

238 the thoracolumbar disk herniation and meningioma are lower than those in the healthy areas
239 [20]. Thus, it is generally considered that the decrease in ADC value is due to the influence of
240 the change in water content caused by cytotoxic edema and the change in lipid content due to
241 demyelination, thereby reducing the degree of diffusion of water molecules [12]. Furthermore,
242 histiocytic sarcoma, which is clinically more malignant than brain meningiomas in dogs, was
243 reported to have a lower ADC level than meningioma [37]. As a tumor with high malignancy
244 has a high cell density, a higher cell density results in a lower ADC value. In DM-affected PWC,
245 demyelination in the thoracolumbar spinal cord, proliferation of fibrous tissue, microgliosis, and
246 diffuse proliferation of astrocytes are observed [3, 9, 23, 25]. Also, the space caused by axonal
247 loss and demyelination were replaced by homogeneous eosinophilic matrix associated with
248 astrocytosis [23]. These pathological features suggest that the demyelination and increased cell
249 density in the thoracolumbar spinal cord of DM-affected dogs restrict the movement of water
250 molecules and reduce ADC levels. It is necessary to evaluate the relationship between ADC
251 values and histopathological findings in future studies.
252 ADC values of L1-L2 intervertebral disk levels in the DM group were significantly
253 lower than those in the IVDH group, while there were no significant differences between the
254 two groups in ADC values at other intervertebral disk levels. In contrast, a previous report
255 demonstrated that IVDH lesions had lower ADC values than normal regions of the spinal cord

256 [20]. In general, ADC values increase in the spinal cord with edema and/or demyelination
257 secondary to IVDH whereas significant increase of ADC values is not seen in the spinal cord
258 without edema/demyelination [12]. Therefore, it is difficult to quantify the degree of spinal cord
259 degeneration under the influence of compressive lesions, and it is necessary to evaluate multiple
260 spinal cord segments including a spinal cord region not unaffected by IVDH.

261 In this study, the FA value of the T8-L3 region in DM group was significantly lower
262 than that in the IVDH group. The FA value is a quantification of the degree of anisotropy and
263 the decrease in diffusion anisotropy reflects the incompleteness of nerve fiber bundles in the
264 spinal cord [31]. In spinal cord diseases in dogs, the FA value is lower in chronic spinal cord
265 injury lesions than in the healthy area [37]. In chronic spinal cord injury, axonal degeneration
266 and demyelination are considered to impair the integrity of nerve fiber bundles and reduce FA
267 levels. In PWC with DM, marked axonal degeneration and demyelination are found in the white
268 matter of the thoracolumbar spinal cord [3, 9, 23, 25]. This suggested that degenerative changes
269 in the spinal cord white matter in DM-affected dogs caused the impaired nerve fiber bundles
270 and reduced FA levels. Currently, the association between FA levels and histological changes in
271 the spinal cord of dogs with DM is unknown. Therefore, it is necessary to evaluate the
272 association between FA values and histopathological findings in future studies.

273 In chronic spinal cord injury in dogs, the FA value in the lesioned area decreases and

274 is further correlated with the clinical score [22]. As the IVDH group in this study contained dogs
275 with varying grades and herniated sites, there was no significant difference among the three
276 groups in FA values at each intervertebral level. A previous report revealed that the DM group
277 showed significantly lower FA values than the healthy group when assessing FA values using
278 the cranial lumbar region of the spinal cord [15]. Although, there was no significant difference
279 when assessing FA levels at the disk level in the present study, there was a significant difference
280 in the broader spinal cord assessment. Since widespread white matter degeneration is seen in the
281 spinal cord of DM, a wide measurement range may be required to detect changes of the
282 degenerative lesions.

283 When comparing the ADC and FA values at T8-L3 region in the DM-suspected
284 group and DM-confirmed group, ADC value was negatively correlated with clinical duration;
285 however, there was no significant difference in FA value. In general, the ADC value decreases
286 due to restriction of the movement of water molecules in proportion to the degree of cytotoxic
287 edema and increased cell density [12]. In the thoracolumbar spinal cord of dogs with DM, the
288 degree of extracellular matrix and cell density is considered to increase due to glial cells
289 depending on the stage of disease [3, 9, 23, 25]. Therefore, water molecule movement may be
290 gradually restricted. On the other hand, axonal degeneration and demyelination of the white
291 matter in the thoracolumbar spinal cord have been observed since early stage of DM [10, 23].

292 This histopathological finding supports the isotropic diffusion of water molecules in the
293 thoracolumbar spinal cord from the early stages of DM. However, the recent DTI study reported
294 that FA values were significantly correlated with histopathological grade of the DM spinal cord
295 [15]. This different result is considered to be caused by the difference in the measurement site.
296 Further studies are needed on the relationship among the clinical stage, histopathological
297 findings, measurement site, and MRI parameters.

298 The results of the present study showed that the ADC and FA values of the T8-L3
299 region were superior to those of cross-sectional spinal cord to assess spinal cord degeneration in
300 DM. In ALS studies, using a 9.4-Tesla MRI system, the axial diffusion and radial diffusion
301 values of the gray matter of the spinal cord were reduced in ALS model mouse group compared
302 to healthy control group [13]. In another study, FA values obtained from the corticospinal tract
303 were reduced in ALS patient group compared to healthy control group [6]. In dogs of which the
304 size of the spinal cord is much smaller than humans, it is difficult to set an ROI to target only a
305 specific region of the spinal cord, using a clinical MRI system. On the other hand, radial
306 diffusion and FA values obtained not only from a single spinal cord segment but multiple spinal
307 cord segments were reduced in ALS group compared to healthy controls [26, 30]. Therefore,
308 evaluation of DTI parameters using multiple spinal cord segments (T8-L3 region) was
309 considered to be suitable for capturing spinal cord degeneration in dogs. In the future, it is

310 necessary to investigate the region of spinal cord segments with the highest diagnostic ability
311 for detecting DM lesions.
312 There are several limitations in this study. Measurements of ADC and FA values
313 were performed and analyzed by a single observer. Further study is needed to evaluate intra- and
314 inter-observer errors. In the DM group, MRI data for four dogs were obtained postmortem in
315 order to compare the difference of DTI parameters between the early stage and late stage. This
316 comparison was only possible by using postmortem MRI as dogs with DM in the late stage
317 suffer from respiratory disfunction that hinders diagnostics requiring general anesthesia. DTI
318 data for 4 cases in the DM group were obtained postmortem. A previous study using mice
319 reported that DTI data obtained 10 hr after death were comparable with those obtained
320 premortem [18]. Postmortem MRI was performed within 24 hr of death in an attempt to
321 minimize any postmortem changes. Postmortem changes need to be investigated in terms of
322 their effects on histopathological changes and DTI data. Further, the degree of spinal cord
323 degeneration was not quantified by histopathological examination and the correlation between
324 histopathological changes and DTI parameters were not investigated. Four dogs were tentatively
325 diagnosed with DM based on our diagnostic criteria without histopathological confirmation.
326 These four dogs were still alive at the time of manuscript preparation; therefore, this study could
327 not compare the histopathological findings of DM with MRI. The sample size was small, and

the age, weight, and breed in each group were not consistent. Specific diagnostic parameters such as the cut-off value, sensitivity, and specificity need to be determined upon increasing the numbers of dogs in each group. The movement of water molecules may be affected by breathing, heartbeat, cerebrospinal fluid pulsation, and anesthesia [36]. CSF and surrounding tissue may also be included due to the limited ROI resolution. Using the average ADC value and FA value of the target areas visualized by fiber tractography may reduce these artifacts.

In conclusion, quantitative data using DTI may be the potential biomarker for distinguishing DM from IVDH. In particular, the ADC value of the T8-L3 region may aid in the premortem diagnosis of DM.

CONFLICT OF INTEREST

None of the authors have a financial or personal relationship with other persons of organizations who can inappropriately influence or bias the content of the paper.

ACKNOWLEDGMENT

We wish to thank Mr. Tochimoto for his technical assistance in the acquisition and analysis of DTI data.

REFERENCES

1. Aikawa, T., Fujita, H., Kanazono, S., Shibata, M., and Yoshigae, Y. 2012. Long-term neurologic outcome of hemilaminectomy and disk fenestration for treatment of dogs with thoracolumbar intervertebral disk herniation: 831 cases (2000-2007). *J. Am. Vet. Med. Assoc.* **241**: 1617-1626.

2. Averill, D. R. 1973. Degenerative myelopathy in the aging German Shepherd dog: clinical and pathologic findings. *J. Am. Vet. Med. Assoc*. **162**:1045-1051.

3. Awano, T., Johnson, G. S., Wade, C. M., Katz, M. L., Johnson, G. C., Taylor, J. F., Perloski, M., Biagi, T., Baranowska, I., Long, S., March, P. A., Olby, N. J., Shelton, G. D., Khan, S., O'Brien, D. P., Lindblad-Toh, K., and Coates, J. R. 2009. Genome-wide association analysis reveals a SOD1 mutation in canine degenerative myelopathy that resembles amyotrophic lateral sclerosis. *Proc. Natl. Acad. Sci. U. S. A*. **106**: 2794-2799.

4. Banaszek, A., Bladowska, J., Pokryszko-Dragan, A., Podemski, R., and Sąsiadek, M. J. 2015. Evaluation of the Degradation of the Selected Projectile, Commissural and Association White Matter Tracts Within Normal Appearing White Matter in Patients with Multiple Sclerosis Using Diffusion Tensor MR Imaging - a Preliminary Study. *Pol. J. Radiol*. **80**: 457-463.

5. Banaszek, A., Bladowska, J., Szewczyk, P., Podgórski, P., and Sąsiadek, M. 2014. Usefulness of diffusion tensor MR imaging in the assessment of intramedullary changes of the

364 cervical spinal cord in different stages of degenerative spine disease. *Eur Spine J*. **23**: 1523-
365 1530.
366 6. Budrewicz, S., Szewczyk, P., Bladowska, J., Podemski, R., Koziorowska-Gawron,
367 E., Ejma, M., Słotwiński, K. and Koszewicz, M. 2016. The possible meaning of fractional
368 anisotropy measurement of the cervical spinal cord in correct diagnosis of amyotrophic lateral
369 sclerosis. *Neurological sciences*. **37**: 417–421.
370 7. Chan, Y. H. 2003. Biostatistics 104: correlational analysis. *Singapore Med. J.* **44**:
371 614-619.
372 8. Chang, H. S., Kamishina, H., Mizukami, K., Momoi, Y., Katayama, M., Rahman,
373 M. M., Uddin, M. M., Yabuki, A., Kohyama, M., and Yamato, O. 2013. Genotyping assays for
374 the canine degenerative myelopathy-associated c.118G>A (p.E40K) mutation of the SOD1 gene
375 using conventional and real-time PCR methods: a high prevalence in the Pembroke Welsh Corgi
376 breed in Japan. *J. Vet. Med. Sci*. **75**: 795-798.
377 9. Coates, J. R., March, P. A., Oglesbee, M., Ruaux, C. G., Olby, N. J., Berghaus, R.
378 D., O'Brien, D. P., Keating, J. H., Johnson, G. S., and Williams, D. A. 2007. Clinical
379 characterization of a familial degenerative myelopathy in Pembroke Welsh Corgi dogs. *J. Vet.*
380 *Intern. Med*. **21**: 1323-1331.
381 10. Coates, J. R., and Wininger, F. A. 2010. Canine degenerative myelopathy. *Vet.*

Clin. North. Am. Small Anim. Pract. **40**:929-950.

11. Ellingson, B. M., Salamon, N., Grinstead J. W., and Holly, L. T. 2014. Diffusion tensor imaging predicts functional impairment in mild-to-moderate cervical spondylotic myelopathy. *Spine J*. **14**: 2589-2597.

12. Ellingson, B. M., Salamon, N., and Holly, L. T. 2015. Advances in MR imaging for cervical spondylotic myelopathy. *Eur. Spine J*. **24**:197-208.

13. Gatto, R. G., W. Li, and R. L. Magin. 2017. Diffusion tensor imaging identifies presymptomatic axonal degeneration in the spinal cord of ALS mice. *Brain Res.* **1679**: 45-52.

14. Grolez, G., Kyheng, M., Lopes, R., Moreau, C., Timmerman, K., Auger, F., Kuchcinski, G., Duhamel, A., Jissendi-Tchofo, P., Besson, P., Laloux, C., Petrault, M., Devedjian, J. C., Pérez, T., Pradat, P. F., Defebvre, L., Bordet, R., Danel-Brunaud, V., and Devos, D. 2018. MRI of the cervical spinal cord predicts respiratory dysfunction in ALS. *Sci. Rep*. **8**: 1828.

15. Johnson, P. J., Miller, A. D., Cheetham, J., Demeter, E. A., Luh, W. M., Loftus, J. P., Stephan, S. L., Dewey, C. W., and Barry, E. F. 2021. In Vivo Detection of Microstructural Spinal Cord Lesions in Dogs with Degenerative Myelopathy Using Diffusion Tensor Imaging. *J. Vet. Intern. Med.* **35**: 352-362.

16. Johnston, P. E., Barrie, J. A., McCulloch, M. C., Anderson, T. J., Griffiths, I. R.

400 2000. Central nervous system pathology in 25 dogs with chronic degenerative
401 radiculomyelopathy. *Vet. Rec*. **146**: 629-633.
402 17. Kanda, Y. 2013. Investigation of the freely available easy-to-use software 'EZR'
403 for medical statistics. *Bone Marrow Transplant*. **48**: 452-458.
404 18. Kim, J. H., Trinkaus, K., Ozcan, A., Budde, M. D., Song, S. K. 2007. Postmortem
405 delay does not change regional diffusion anisotropy characteristics in mouse spinal cord white
406 matter. *NMR Biomed*. **20**: 352-359.
407 19. Kolasa, M., Hakulinen, U., Brander, A., Hagman, S., Dastidar, P., Elovaara, I.,
408 and Sumelahti, M. L. 2019. Diffusion tensor imaging and disability progression in multiple
409 sclerosis: A 4-year follow-up study. *Brain Behav*. **9**: e01194.
410 20. Konishi, Y., Satoh, H., Kuroiwa, Y., Kusaka, M., Yamashita, A., Asada, Y. and
411 Asanuma, T. 2017. Application of fiber tractography and diffusion tensor imaging to evaluate
412 spinal cord diseases in dogs. *J. Vet. Med. Sci*. **79**: 418-424.
413 21. Lee, J. W., Kim, J. H., Park, J. B., Park, K. W., Yeom, J. S., Lee, G. Y., and Kang,
414 H. 2011. S.Diffusion tensor imaging and fiber tractography in cervical compressive myelopathy:
415 preliminary results. *Skeletal Radiol*. **40**: 1543-1551.
416 22. Lewis, M. J., Yap, P. T., McCullough, S., and Olby, N.J. 2018. The Relationship
417 between Lesion Severity Characterized by Diffusion Tensor Imaging and Motor Function in

Chronic Canine Spinal Cord Injury. *J. Neurotrauma*. **35**: 500-507.

23. March, P. A., Coates, J. R., Abyad, R. J., Williams, D. A., O'Brien, D. P., Olby, N. J., Keating, J. H., and Oglesbee, M. 2009. Degenerative myelopathy in 18 Pembroke Welsh Corgi dogs. *Vet. Pathol*. **46**: 241-250.

24. Martin, A. R., Aleksanderek, I., Cohen-Adad, J., Tarmohamed, Z., Tetreault, L., Smith, N., Cadotte, D. W., Crawley, A., Ginsberg, H., Mikulis, D. J., and Fehlings, M. G. 2016. Translating state-of-the-art spinal cord MRI techniques to clinical use: A systematic review of clinical studies utilizing DTI, MT, MWF, MRS, and fMRI. *Neuroimage Clin*. **10**: 192-238.

25. Miller, A. D., Barber, R., Porter, B. F., Peters, R. M., Kent, M., Platt, S. R., and Schatzberg, S. J. 2009. Degenerative myelopathy in two Boxer dogs. *Vet. Pathol*. **46**: 684-687.

26. Nair, G., Carew, J. D., Ushe,r S., Lu, D., Hu, X. P., and Benatar, M. 2010. Diffusion tensor imaging reveals regional differences in the cervical spinal cord in amyotrophic lateral sclerosis. *NeuroImage*. **53**: 576–583.

27. Naito, E., Nakata, K., Nakano, Y., Nozue, Y., Kimura, S., Sakai, H., Yamato, O., Islam, M. S., Maeda, S., and Kamishina, H. 2021. Changes of dorsal root ganglion volume in dogs with clinical signs of degenerative myelopathy detected by water-excitation magnetic resonance imaging. *Animals (Basel)*. **11**: 1702.

28. Okada, M., Kitagawa, M., Kanayama, K., Yamamura, H., and Sakai, T. 2009.

Negative MRI findings in a case of degenerative myelopathy in a dog. *J. S. Afr. Vet. Assoc*. **80**: 254-256.

29. Oyake, K., Kobatake, Y., Shibata, S., Sakai, H., Saito, M., Yamato, O., Kushida, K., Maeda, S., and Kamishina, H. 2016. Changes in respiratory function in Pembroke Welsh Corgi dogs with degenerative myelopathy. *J Vet Med Sci*. **78**: 1323-1327.

30. Patzig, M., Bochmann, K., Lutz, J., Stahl, R., Küpper, C., Liebig, T., Reilich, P., and Dieterich, M. 2019. Measurement of structural integrity of the spinal cord in patients with amyotrophic lateral sclerosis using diffusion tensor magnetic resonance imaging. *PLoS One*. **14**: e0224078.

31. Pierpaoli, C., Basser, P. J. 1996. Toward a quantitative assessment of diffusion anisotropy. *Magn. Reson. Med*. **36**: 893-906.

32. Querin, G., El Mendili, M. M., Lenglet, T., Delphine, S., Marchand-Pauvert, V., Benali, H., and Pradat, P. F. 2017. Spinal cord multi-parametric magnetic resonance imaging for survival prediction in amyotrophic lateral sclerosis. *Eur. J. Neurol*. **24**: 1040-1046.

33. Scott, H. W., and McKee, W. M. 1999. Laminectomy for 34 dogs with thoracolumbar intervertebral disc disease and loss of deep pain perception. *J. Small Anim. Pract.* **40**: 417-422.

34. Shanmuganathan, K., Gullapalli, R. P., Zhuo, J., and Mirvis, S. E. 2008.

454 Diffusion tensor MR imaging in cervical spine trauma. *AJNR Am. J. Neuroradiol*. **29**: 655-659.

455 35. Underwood, C. K., Kurniawan, N. D., Butler, T. J., Cowin, G. J., and Wallace, R.
456 H. 2011. Non-invasive diffusion tensor imaging detects white matter degeneration in the spinal
457 cord of a mouse model of amyotrophic lateral sclerosis. *Neuroimage*. **55**: 455-461.

458 36. Urger, E., Debellis, M. D., Hooper, S. R., Woolley, D. P., Chen, S., and
459 Provenzale, J. M. 2013. Influence of analysis technique on measurement of diffusion tensor
460 imaging parameters. *AJR Am. J. Roentgenol*. **200**: 510-517.

461 37. Wada, M., Hasegawa, D., Hamamoto, Y., Yu, Y., Fujiwara-Igarashi, A., and
462 Fujita, M. 2017. Comparisons among MRI signs, apparent diffusion coefficient, and fractional
463 anisotropy in dogs with a solitary intracranial meningioma or histiocytic sarcoma. *Vet. Radiol.*
464 *Ultrasound*. **58**: 422-432.

465 38. Wang, W., Qin, W., Hao, N., Wang, Y., and Zong, G. 2012. Diffusion tensor
466 imaging in spinal cord compression. *Acta. Radiol*. **53**: 921-928.

467 39. Wininger, F. A., Zeng, R., Johnson, G. S., Katz, M. L., Johnson, G. C., Bush, W.
468 W., Jarboe, J. M., and Coates, J. R. 2011. Degenerative myelopathy in a Bernese Mountain Dog
469 with a novel SOD1 missense mutation. *J. Vet. Intern. Med*. **25**: 1166-1170.

FIGURE LEGENDS

Figure 1. Fiber tractography and placement of regions of interest (ROI) in the thoracolumbar spinal cord. (Dog #5)

(a) Eight ROIs were placed manually on transverse T2-weighted images on each intervertebral disk level slice from T8-T9 through L2-L3. (b) The axonal bundles of the spinal cord are string-like and appear mainly in blue due to the craniocaudal direction of water diffusion. Axonal bundles were tracked from T8-T9 through to the L2-L3 intervertebral level. (c) The T12-T13 intervertebral level slice is shown on a transverse FA map. (d) The region of interest is placed on T12-T13 spinal cord area.

Figure 2. Comparison of apparent diffusion coefficient (ADC) values among degenerative myelopathy (DM), intervertebral disk herniation (IVDH), and healthy control groups

The ADC values at T10-T11, T12-T13, T13, L1, L1-L2, L2-L3 intervertebral disk levels, and T8-L3 region were significantly lower in the DM group than in the control group (P=0.038, 0.004, 0.041, 0.038, 0.024, and 0.002, respectively). The ADC values at L1-L2 intervertebral disk level and T8-L3 region were significantly lower in the DM group than in the IVDH group (P=0.038 and P<0.001). Horizontal bars indicate medians within groups. Statistical analyses were performed using the Kruskal-Wallis test. Post hoc comparisons used Mann-Whitney U test with Bonferroni correction. *P<0.05.

Figure 3. Comparison of fractional anisotropy (FA) values among degenerative myelopathy (DM), intervertebral disk herniation (IVDH), and healthy control groups

The FA value of the T8-L3 region were significantly lower in the DM group than in the control and IVDH group (P=0.024 and 0.006). Horizontal bars indicate medians within groups. Statistical analyses were performed using the Kruskal-Wallis test. Post hoc comparisons used Mann-Whitney U test with Bonferroni correction. *P<0.05.

Table 1. Characteristics of dogs

Dog number	Diagnosis	Breed	Age (year)	Body weight (kg)	Gender	Location(s) of IVDH	Clinical duration
1	DM-confirmed	PWC	13.0	10.2	CM	T12-T13, T13-L1, L2-L3	3.0 years
2	DM-confirmed	PWC	15.2	10.1	CM	L1-L2	3.5 years
3	DM-confirmed	PWC	14.1	14.6	IF	None	3.3 years
4	DM-confirmed	PWC	15.9	14.6	CM	T13-L1	3.0 years
5	DM-suspected	PWC	14.1	11.8	CM	T13-L1	2 months
6	DM-suspected	PWC	12.7	13.6	CM	T12-T13, T13,-L1	3 months
7	DM-suspected	PWC	11.0	12.3	SF	None	7 months
8	DM-suspected	PWC	10.8	16.8	SF	None	2 months
9	IVDH	CB	11.7	3.4	CM	T12-T13	5 days
10	IVDH	Pug	11.6	6.3	SF	T11-T12, T12-T13, L5-L6, L6-L7	3 months
11	IVDH	MD	3.5	5.2	IF	T13-L1	3 days
12	IVDH	MD	5.0	4.2	CM	T13-L1	7 days
13	IVDH	MD	10.8	4.5	SF	T13-L1, L2-L3	4 days
14	IVDH	MD	10.9	5.8	IF	L2-L3, L3-L4	1 month
15	IVDH	TP	5.1	6.7	IM	L1-L2	11 days
16	IVDH	MD	10.7	8.0	IM	L2-L3	10 days
17	IVDH	CB	11.9	5.6	IM	T13-L1	1 month
18	IVDH	MD	9.8	10.7	IM	T13-L1	5 days
19	IVDH	MP	4.7	4.8	CM	T11-T12, T12-T13, L2-L3	5 days
20	IVDH	MD	8.9	5.3	IM	L2-L3	3 days
21	IVDH	MD	10.1	7.1	CM	T12-T13, T13-L1, L1-L2, L2-L3, L4-L5	1 month
22	Hearthy	Beagle	4.0	13.5	SF	None	
23	Hearthy	Beagle	4.0	18.4	CM	None	
24	Hearthy	Beagle	5.0	14.0	CM	None	
25	Hearthy	Beagle	5.5	12.3	SF	None	
26	Hearthy	PWC	10.7	10.7	SF	None	
27	Hearthy	Crossbreed	2.8	10.6	CM	None	

DM, Degenerative myelopathy; IVDH, intervertebral disc herniation; PWC, Pembroke Welsh Corgi; CB, Cross-bred; MD, Miniature Dachshund; TP, Toy Poodle; MP, Miniature Pinscher; CM, Castrated male; IM, Intact male; SF, Spayed female; IF, Intact female.

Table 2. Comparison of apparent diffusion coefficient (ADC) and fractional anisotropy (FA) values among degenerative myelopathy (DM), intervertebral disc herniation (IVDH), and healthy control groups

	Intervertebral level	Control		DM		IVDH		*P* value			
		Median	Range	Median	Range	Median	Range	3 groups	Control vs DM	Control vs IVDH	DM vs IVDH
ADC ($\times 10^{-3}$ mm^2/s)	T8–T9	1.096	0.239–1.567	0.575	0.198–2.287	1.065	0.732–2.457	0.123	1.000	1.000	0.091
	T9–T10	1.338	0.617–1.578	0.536	0.194–1.958	1.162	0.615–1.952	0.134	0.540	1.000	0.230
	T10–T11	1.360	0.913–1.787	0.780	0.107–1.348	1.324	0.605–2.023	0.024*	0.038*	1.000	0.060
	T11–T12	1.339	0.982–2.059	0.836	0.579–1.422	1.263	0.542–1.902	0.062	0.060	1.000	0.360
	T12–T13	1.445	1.243–1.763	0.857	0.519–1.280	1.183	0.746–1.946	0.007*	0.004*	0.537	0.091
	T13–L1	1.285	0.984–1.428	0.748	0.393–1.437	1.305	0.682–1.733	0.027*	0.041*	1.000	0.060
	L1–L2	1.325	0.896–1.473	0.915	0.261–1.171	1.317	0.408–1.603	0.017*	0.038*	1.000	0.038*
	L2–L3	1.360	1.252–1.728	0.892	0.246–1.431	1.116	0.544–2.188	0.007*	0.024*	0.109	0.110
	T8–L3	1.408	1.048–1.627	0.713	0.440–0.840	1.279	0.767–1.767	<0.001*	0.002*	0.969	<0.001*
FA	T8–T9	0.574	0.443–0.614	0.547	0.323–0.673	0.548	0.419–0.813	0.901	1.000	1.000	1.000
	T9–T10	0.557	0.427–0.646	0.475	0.352–0.726	0.554	0.388–0.827	0.385	0.820	1.000	0.710
	T10–T11	0.520	0.489–0.612	0.446	0.310–0.750	0.489	0.394–0.843	0.139	0.088	1.000	0.804
	T11–T12	0.520	0.417–0.562	0.460	0.332–0.860	0.552	0.366–0.700	0.145	0.730	1.000	0.230
	T12–T13	0.522	0.460–0.602	0.452	0.341–0.686	0.525	0.361–0.677	0.236	0.430	1.000	0.480
	T13–L1	0.587	0.481–0.626	0.457	0.364–0.669	0.471	0.360–0.633	0.109	1.000	0.053	1.000
	L1–L2	0.603	0.476–0.666	0.506	0.340–0.751	0.468	0.421–0.810	0.195	1.000	0.086	1.000
	L2–L3	0.486	0.275–0.593	0.459	0.356–0.783	0.525	0.359–0.769	0.350	1.000	0.550	1.000
	T8–L3	0.544	0.489–0.576	0.449	0.417–0.550	0.575	0.418–0.701	0.004*	0.024*	1.000	0.006*

*P<0.05.

Table 3. Diffusion tensor imaging (DTI) parameters in degenerative myelopathy (DM) stage 1 and DM stage 4

		DM stage 1		DM stage 4		Correlation between the clinical duration of DM and DTI parameters	
	Intervertebral level	Median	Range	Median	Range	r_s	*P* value
ADC	T8–T9	1.018	0.426–2.287	0.417	0.198–0.792	−0.711	0.048*
	T9–T10	1.076	0.482–1.958	0.448	0.194–0.832	−0.711	0.048*
	T10–T11	0.916	0.627–1.348	0.611	0.107–1.047	−0.470	0.240
	T11–T12	1.097	0.649–1.422	0.696	0.579–0.867	−0.711	0.048*
	T12–T13	0.930	0.662–1.280	0.727	0.519–1.046	−0.313	0.450
	T13–L1	0.916	0.808–1.437	0.594	0.393–0.688	−0.873	0.011*
	L1–L2	1.016	0.917–1.171	0.683	0.261–0.913	−0.783	0.022*
	L2–L3	1.016	0.889–1.431	0.818	0.246–0.894	−0.747	0.033*
	T8–L3	0.781	0.754–0.840	0.541	0.440–0.672	−0.723	0.043*
FA	T8–T9	0.488	0.323–0.555	0.618	0.476–0.673	−0.819	0.013*
	T9–T10	0.522	0.424–0.726	0.464	0.352–0.540	−0.325	0.432
	T10–T11	0.485	0.398–0.750	0.412	0.310–0.451	−0.518	0.188
	T11–T12	0.486	0.380–0.860	0.409	0.332–0.496	−0.446	0.268
	T12–T13	0.452	0.433–0.686	0.422	0.341–0.516	−0.036	0.932
	T13–L1	0.457	0.404–0.669	0.459	0.364–0.645	0.084	0.843
	L1–L2	0.512	0.386–0.751	0.480	0.340–0.739	−0.133	0.754
	L2–L3	0.448	0.356–0.572	0.459	0.444–0.783	0.253	0.545
	T8–L3	0.456	0.420–0.550	0.426	0.417–0.454	−0.446	0.268

*P<0.05; ADC apparent diffusion coefficient; FA, fractional anisotropy.

Figure 1

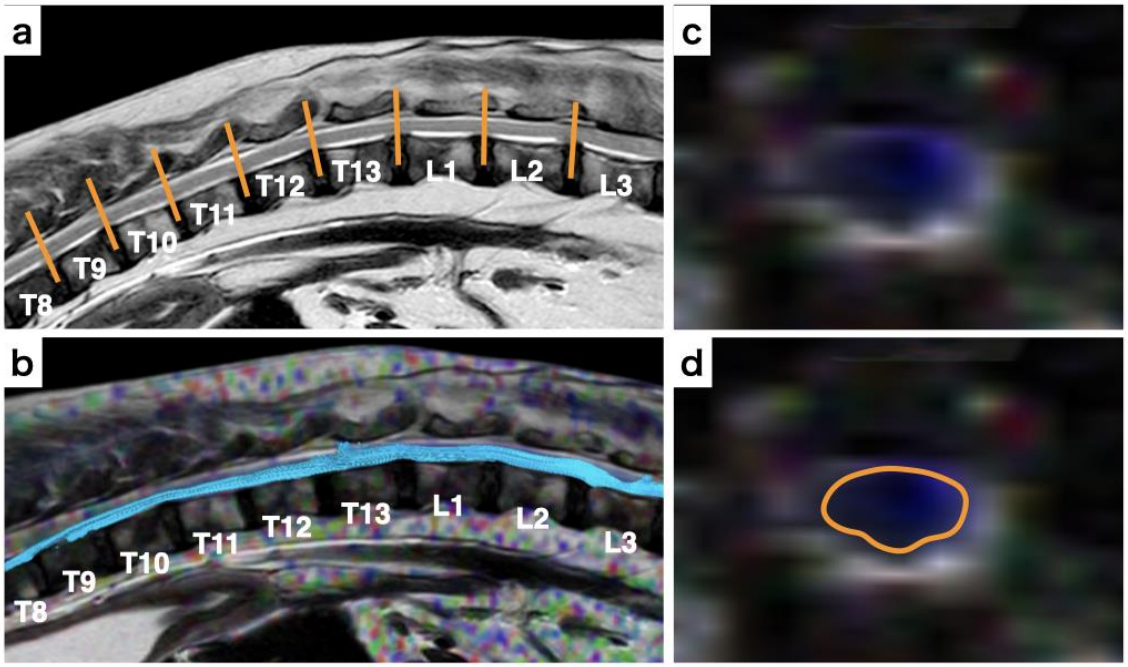

501 **Figure 2**

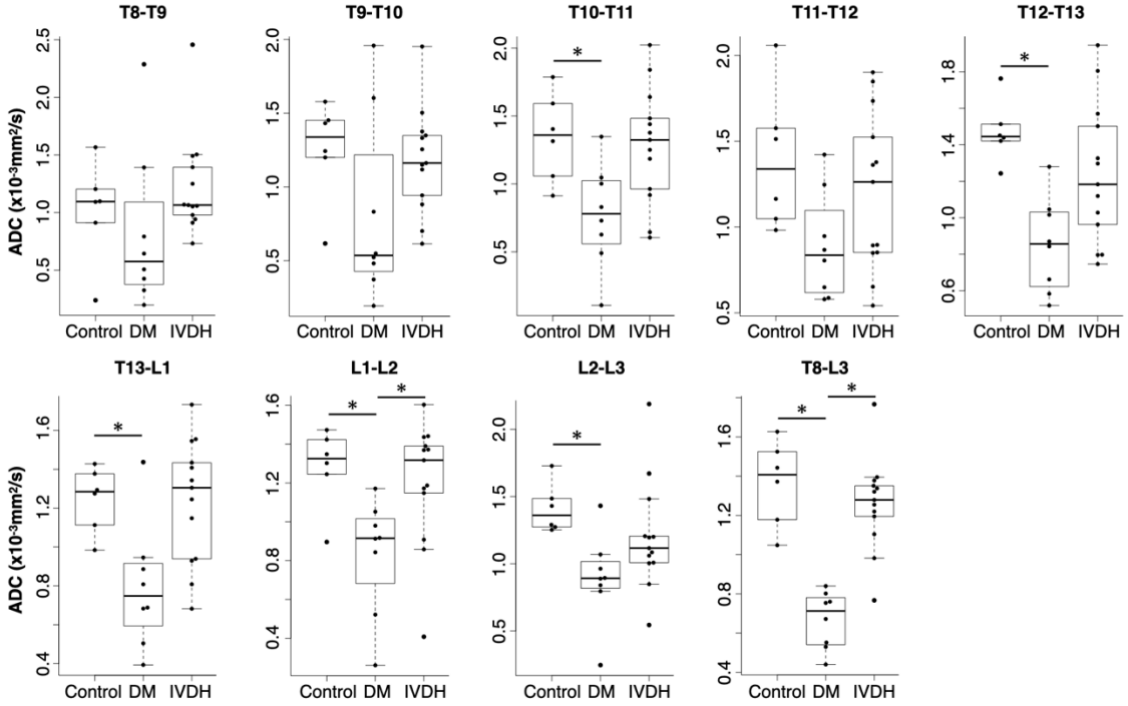

502

Figure 3

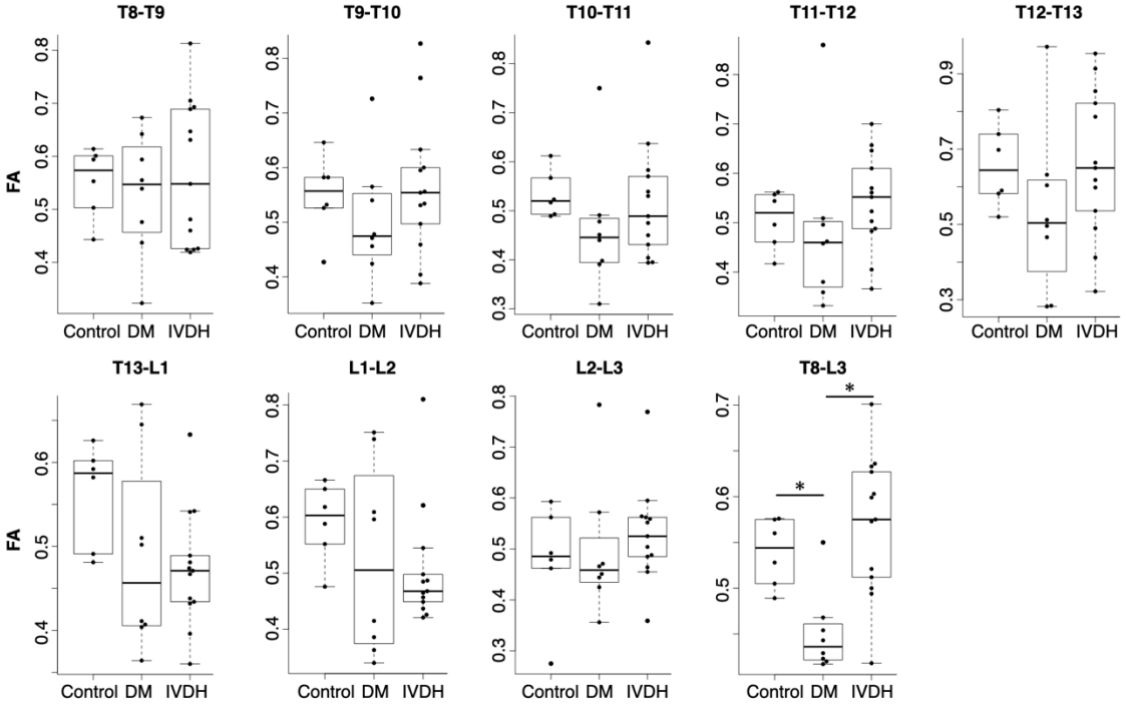
T8-T9
T9-T10
T10-T11
T11-T12
T12-T13
T13-L1
L1-L2
L2-L3
T8-L3
FA
Control DM IVDH
*
*