CASE REPORT

Two Cases of Pathological Complete Response to Neoadjuvant Chemoradiation Therapy in Pancreatic Cancer

Yoko Fujii-Nishimura,[1,*] Ryo Nishiyama,[2,*] Minoru Kitago,[2] Yohei Masugi,[1] Akihisa Ueno,[3] Koichi Aiura,[4] Shigeyuki Kawachi,[5] Miho Kawaida,[1] Yuta Abe,[2] Masahiro Shinoda,[2] Osamu Itano,[2] Akihiro Tanimoto,[3] Michiie Sakamoto[1] and Yuko Kitagawa[2]

[1]*Department of Pathology, Keio University School of Medicine, Tokyo, Japan*
[2]*Department of Surgery, Keio University School of Medicine, Tokyo, Japan*
[3]*Department of Diagnostic Radiology, Keio University School of Medicine, Tokyo, Japan*
[4]*Department of Surgery, Kawasaki Municipal Hospital, Kanagawa, Japan*
[5]*Department of Surgery, Hachioji Medical Center, Tokyo Medical University, Tokyo, Japan*

(Received for publication on October 14, 2014)
(Revised for publication on March 7, 2015)
(Accepted for publication on March 20, 2015)

Neoadjuvant chemoradiation therapy (NACRT) is increasingly used in patients with a potentially or borderline resectable pancreatic ductal adenocarcinoma (PDA) and it has been shown to improve survival and reduce locoregional metastatic disease. It is rare for patients with PDA to have a pathological complete response (pCR) to NACRT, but such patients reportedly have a good prognosis. We report the clinicopathological findings of two cases of pCR to NACRT in PDA. Both patients underwent pancreatectomy after NACRT (5-fluorouracil, mitomycin C, cisplatin, and radiation). Neither had residual invasive carcinoma and both showed extensive fibrotic regions with several ducts regarded as having pancreatic intraepithelial neoplasia 3/carcinoma *in situ* in their post-therapy specimens. It is noteworthy that both patients had a history of a second primary cancer. They both had comparatively good outcomes: one lived for 9 years after the initial pancreatectomy and the other is still alive without recurrence after 2 years. (doi: 10.2302/kjm.2014-0014-CR; Keio J Med 64 (2) : 26–31, June 2015)

***Keywords*: neoadjuvant chemoradiation therapy, pancreatic ductal adenocarcinoma, pathological complete response**

Introduction

Pancreatic ductal adenocarcinoma (PDA) is the fourth leading cause of cancer-related death in Europe, the United States, and Japan.[1,2] Fewer than 20% of patients with PDA at presentation have resectable tumors because of the existence of locally advanced disease or distant metastasis.[3] The 5-year survival rate after potentially curative resection is only approximately 20%,[3,4] with a median survival of approximately 12 months.[5,6] After resection, most patients develop local recurrence or distant metastasis. Neoadjuvant chemoradiation therapy (NACRT) for resectable PDA is not standard treatment; however, it has been considered an acceptable alternative to upfront resection following clinical staging of PDA as borderline resectable.[7] Borderline resectable tumors are those in which it is difficult to achieve margin-free resection without combined excision of major vessels such as the portal vein, superior mesenteric vein (SMV), or superior mesenteric artery. NACRT has been used to reduce tumor volume, to treat micrometastases, and to increase margin-negative resection rates, especially in borderline

This research was performed with the approval of the Ethics Committee of Keio University School of Medicine.
* These authors contributed equally to this work.
Reprint requests to: Yohei Masugi, MD, PhD, Department of Pathology, Keio University School of Medicine, 35 Shinanomachi, Shinjuku, Tokyo 160-8582, Japan, E-mail: masugi@z6.keio.jp
Copyright © 2015 by The Keio Journal of Medicine

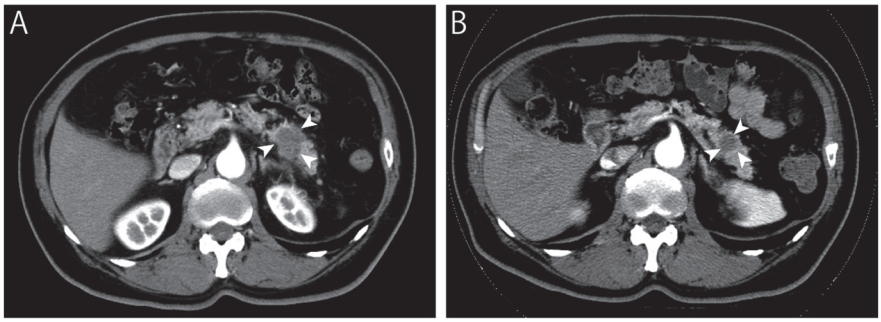

Fig. 1 Case 1: Contrast-enhanced computed tomography (CT) findings.
(A) Pre-NACRT contrast-enhanced CT scan. A tumor was detected as an invasive hypovascular mass (arrowheads) 30 × 20 mm in diameter in the pancreatic tail. (B) In a post-NACRT contrast-enhanced CT scan, the tumor had decreased in size to 20 × 18 mm in diameter.

resectable cases.[8,9] For several different types of carcinoma, in some organs, pathological complete response (pCR) to neoadjuvant therapy is correlated with a lower frequency of local recurrence and better survival.[10–15] However, very few studies have analyzed the clinicopathological significance of pCR in patients with PDA who received neoadjuvant therapy.[9,16,17] Here we report two cases of pCR to NACRT in PDA, including detailed pathological findings of resected tissues.

Case Reports

Case 1

A 66-year-old man was admitted to our hospital because his serum tumor marker carbohydrate antigen 19–9 (CA19-9) levels were elevated to 627 U/ml (normal limit: 37 U/ml). Computed tomography (CT) revealed an invasive hypovascular mass 30 × 20 mm in diameter in the pancreatic tail (**Fig. 1A**). Endoscopic retrograde cholangiopancreatography (ERCP) revealed interruption of the main pancreatic duct, and cytological analysis of pancreatic juice revealed the presence of adenocarcinoma. Endoscopic ultrasound demonstrated tumor encasement around the splenic vein and splenic artery. We diagnosed pancreatic cancer [International Union Against Cancer (UICC), T3N0M0, stage IIA] and performed NACRT consisting of 40 Gy radiation (2.0 Gy/day, days 1–5/w ×4 total: 40 Gy), 5-fluorouracil (5-FU, 300 mg/day, days 1–5/w ×4, civ.), mitomycin C (MMC, 4 mg/body/day, days 1, 8, 15, 22, bolus iv.), cisplatin (CDDP, 10 mg/body/day, days 2, 9, 16, 23, bolus iv.), and heparin (6000 IU/body/day, days 1–7/w ×4, civ.). After NACRT, tumor markers decreased to within the normal range (the CA19-9 level was 23 U/ml). CT scanning revealed that the tumor had shrunk to 20 × 18 mm in diameter after NACRT (**Fig. 1B**). This was considered a partial response (PR) to NACRT according to Response Evaluation Criteria in Solid Tumors (RECIST) guidelines (ver. 1.1). Distal pancreatectomy was performed 4 weeks after NACRT. We performed portal infusion with 5-FU (250 mg/day) for 4 weeks following surgery. No perioperative complications occurred. The resected specimen was fixed in 10% formalin and cut stepwise at 4- to 6-mm intervals. The cut sections revealed a 20-mm white mass lesion in the tail of pancreas. All sections containing pancreatic tissue were embedded in paraffin, cut into 3-µm-thick sections, and stained with hematoxylin and eosin. Microscopically, the mass lesion was mostly dense fibrous tissue (**Fig. 2A**). No residual invasive adenocarcinoma was seen, but a small number of dysplastic epithelia, considered as pancreatic intraepithelial neoplasia (PanIN) 3/carcinoma in situ (CIS), were present in the main pancreatic duct and in several branches in the fibrotic area (**Fig. 2B**). Some of these PanIN3/CIS showed highly degenerative features (**Fig. 2C**). Neither acellular mucin pools nor nodular foci of foamy macrophages were seen in the lesion. The surgical margin of the pancreas was negative microscopically. These findings were compatible with those of other reported cases of PDA post-CRT.[15] The patient underwent postsurgical chemotherapy with gemcitabine. Six years after the initial operation, the patient developed a new PDA in the head of the pancreas and pancreatoduodenectomy was performed. Histopathological examination revealed that the tumor was PDA with an extensive intraductal component. Since this tumor occurred distant from the initial cancer and had a lot of noninvasive tumor components, including PanIN2, we considered that the new lesion was likely to be a second primary cancer rather than a metastatic cancer. The patient died of lung metastases of PDA 9 years after the first operation.

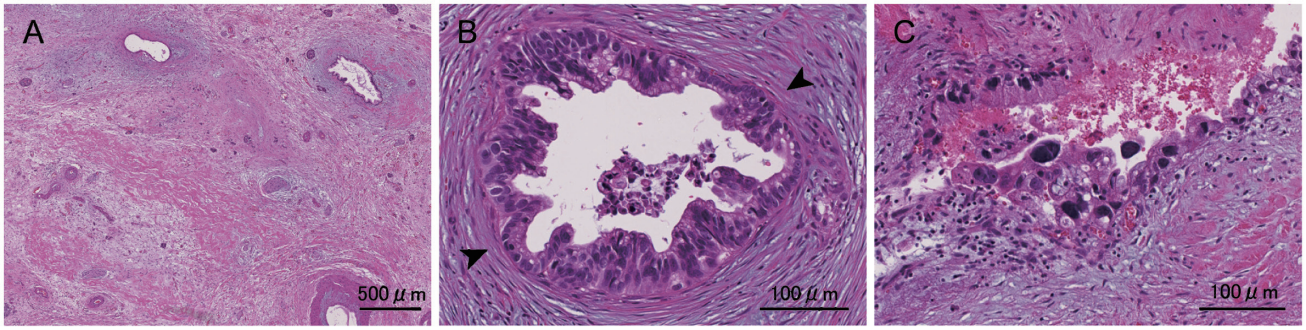

Fig. 2 Case 1: Histopathological examination of the resected specimen.
(A) An area of fibrosis was identified. No residual invasive adenocarcinoma was seen. (B) PanIN3/CIS was present in branches of the pancreatic duct (arrowheads). (C) Some PanIN3/CIS showed highly degenerative features. All specimens were stained with hematoxylin and eosin (H&E).

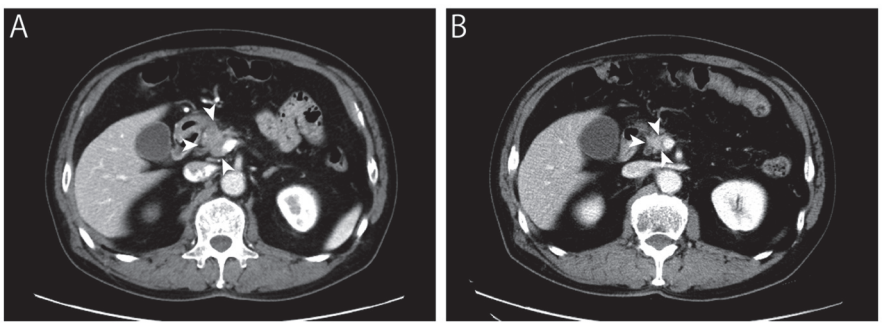

Fig. 3 Case 2: Contrast-enhanced CT findings.
(A) Pre-NACRT contrast-enhanced CT scan. A tumor was detected as an invasive hypovascular mass (arrowheads) 27 × 18 mm in diameter in the pancreatic head. Encasement around the SMV was seen. (B) In a post-NACRT contrast-enhanced CT scan, the tumor had decreased in size to 15 × 12 mm in diameter.

Case 2

A 74-year-old man was admitted to our hospital because his serum tumor marker CA19-9 was elevated to 135 U/ml. He had a history of lung cancers. CT revealed an invasive hypovascular mass 27 × 18 mm in diameter in the pancreatic head along with marked dilatation of the distal main pancreatic duct and encasement around the SMV (**Fig. 3A**). ERCP revealed irregularity and severe stenosis of the main pancreatic duct. Endoscopic ultrasound demonstrated tumor invasion of the SMV. Although cytological analysis of pancreatic juice did not reveal definitive evidence of malignancy, these findings strongly suggested the presence of invasive pancreatic cancer. We finally diagnosed pancreatic cancer (UICC, T3N0M0, stage IIA) and performed NACRT. After NACRT, CA19-9 decreased to within the normal range and CT revealed that the tumor had shrunk to 15 × 12 mm in diameter (**Fig. 3B**). This was considered a PR to NACRT according to the RECIST guidelines. Pylorus-preserving pancreatoduodenectomy with portal vein resection was performed 6 weeks after NACRT. We performed portal infusion with 5-FU (250 mg/day) for 4 weeks following surgery. No perioperative complications occurred. On gross examination of the resected tissue, a scar was noted in the head of the pancreas. Resected specimens were processed in the same way as those in case 1. Histopathologically, an area of fibrosis with aggregation of foamy macrophages (**Fig. 4A**) and multifocal acellular mucin pools was identified. Acellular mucin pools were also seen in the wall of the SMV (**Fig. 4B, C**), perineural spaces (**Fig. 4D**), and lymph nodes (**Fig. 4E**), indicating that there had been invasion by tumor cells to those areas. In the fibrous area, PanIN3/CIS was present in a small number of pancreatic ducts (**Fig. 4F**). However, no residual invasive adenocarcinoma was identified. These findings strongly suggest that there had been invasive PDA before the NACRT. The patient has remained healthy

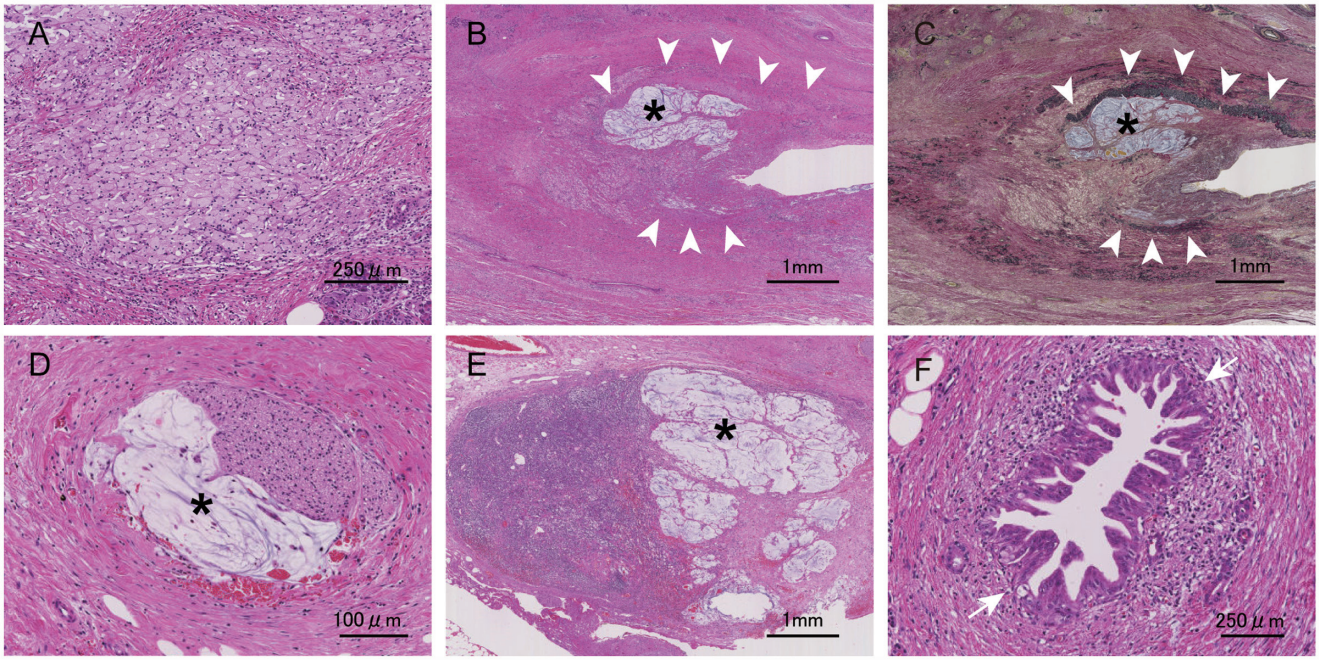

Fig. 4 Case 2: Histopathological examination of the resected specimen.
(A) Aggregation of foamy macrophages was seen in the fibrous area. (B) Acellular mucin pools (asterisk) were seen in the wall of the SMV (arrowheads). (C) Elastica van Gieson staining of B. Acellular mucin pools were also seen in perineural locations (D) and lymph nodes (E). (F) PanIN3/CIS was present in branches of the pancreatic ducts (arrows). A, B, D–F: H&E.

with no recurrence for 2 years after the operation.

Discussion

Here we report pathological findings of pCR in two PDA cases. Because both cases had no residual invasive cancer after NACRT, we considered them to have had pCR despite the presence of PanIN3/CIS. Very few reports have given a strict definition of pCR to NACRT in PDA.[18,19] However, Zhao et al. have recently defined pCR in PDA as the presence of an area of scarring in pancreatic parenchyma and/or peripancreatic soft tissue with chronic inflammation with no residual viable invasive adenocarcinoma cells, regardless of the presence of intraductal neoplasms such as PanIN/CIS in pancreatectomy specimens, and found that patients with pCR based on these criteria had a better prognosis than other patients.[16] Zhao et al. performed detailed pathological examinations after NACRT and revealed that PanIN3/CIS was present in 5/11 (45%) of pCR cases;[16] PanIN3/CIS was present in both our pCR cases. For breast cancer, it is standard to define pCR as the absence of invasive cancer, even if persistent ductal carcinoma *in situ* is seen after NACRT.[14] Thus, it is possible that intraductal neoplasia, such as PanIN or CIS, tends to remain after CRT. Further studies are needed to clarify the prognostic significance of residual intraductal components post-CRT in PDA cases. Meanwhile, the resected specimens in our two cases displayed differences in pathology: one showed hyaline fibrosis and cellular degeneration in some PanIN3/CIS, while the other showed nodular aggregation of macrophages and multifocal acellular mucin pools. These differences may be attributed to the different characteristics or developmental pathways of the original cancers.

There are some grading systems for the extent of residual tumor in PDA after CRT,[6,9,17–19] but systems for assessing histological therapeutic effect have not yet been standardized. For example, Evans et al. proposed criteria based on the amount of destruction of tumor cells, paying attention to acellular mucin pools,[18] whereas Le Scodan et al. proposed classification based on the proportions of degenerative tumor cells present.[19] These criteria seem insufficient on their own because the pathological features of pCR in PDA are more various. More standardized and practical evaluation systems will be required to assess the diverse histological findings seen after NACRT in PDA.

Patients with pCR in breast, esophageal, or rectal specimens after neoadjuvant therapy had better disease-free survival and overall survival than did patients with residual disease.[10–13,15,20,21] In general, the margin-free resection rate or 6-month progression-free survival is used as an effective surrogate marker of NACRT efficacy in PDA. The pathological response rate is also gaining recognition

as an important surrogate. Zhao et al. demonstrated that patients with pCR had better survival than did those with residual invasive tumor after NACRT in PDA.[16] Chatterjee et al. showed that PDA patients with pCR or minimal residual tumor had better survival than those with moderate or poor pathological response.[22] These reports suggest that the pathological response rate to NACRT is a prognostic factor in PDA patients. Furthermore, it has also been shown that patients with pCR have remarkably good prognosis. In our two cases, one patient lived for 9 years after the first operation, and the other is still alive without recurrence after 2 years. Considering that patients with PDA who undergo surgical resection have a median survival of around 12 months,[5] we can say that our patients had comparatively good outcomes.

Although clinical research on NACRT for pancreatic cancer has been ongoing for more than 20 years, standardized protocols have not yet been established.[23] In 1992, Evans et al. reported that they administered preoperative chemoradiation with fluorouracil 300 mg/m^2 per day and 50.4 Gy to 28 patients with the intent of proceeding to resection, and 17 of these patients were able to undergo resection. All resected specimens showed histological evidence of tumor cell injury, with clear margins in 82% of specimens.[18] Many other institutions, including our facility, have also used fluorouracil-based NACRT.[23–25] Continuous intravenous infusion of fluorouracil has become standard, and, to get better results, some institutions have reported co-use of MMC and CDDP to be effective.[25,26] pCR to NACRT is rare in pancreatic cancer, which is thought to be chemoradio-resistant relative to other gastrointestinal malignancies.[8] In our institution, 25 patients with locally invasive PDA without distant metastasis underwent fluorouracil-based NACRT (5-FU+MMC+CDDP+radiation 40 Gy) between 2003 and 2011. Among these 25 patients, 17 (68%) underwent pancreatectomy and 2 (8%) were identified as having pCR. Chua and Saxena reviewed seventeen studies of preoperative chemoradiation for resectable pancreatic cancer from 2000 to 2010, including eight phase II studies and nine observational studies comprising 977 patients, and concluded that pCR was uncommon, with the rate ranging from 5% to 15%.[23] Various NACRT protocols have been reported, and the rates of pCR seem to be similar.

It is interesting to note that both of our patients had a history of a second primary cancer: one had a second primary pancreatic cancer and the other had a history of lung cancer. Zhao, et al. identified 11 patients with pCR (2.5%) from 442 patients with PDA who underwent NACRT and pancreatectomy, and 4 of these 11 patients (36% of pCR cases) had either synchronous or historical extrapancreatic cancer.[16] Some hereditary disorders with a high incidence of cancer development are associated with hypersensitivity to CRT for cancer therapy. For example, patients with ataxia telangiectasia (AT), a rare autosomal recessive disease in which afflicted individuals present with progressive cerebellar ataxia, are immune deficient and are known to have a high incidence of cancer.[27] They are also known to exhibit hypersensitivity to ionizing radiation. Mutation in the *ATM* gene, which regulates the cell cycle, is responsible for the AT phenotype.[27] It is known that the DNA damage response in mammalian cells is made up of multiprotein complexes that sense, signal, and respond to DNA strand breaks.[27] Disruption of the function of these multiprotein complexes by mutation of a single gene leads to cancer-prone syndromes that are characterized by hypersensitivity to DNA damage and genomic instability.[27] It is possible that our two pCR patients have some genetic mutation that induces genomic instability, resulting in both a high incidence of cancer and hypersensitivity to radiation.

Here we report two illuminating cases of pCR in patients with PDA. Although many issues remain to be resolved with respect to NACRT for PDA (e.g., clarifying clinical significance, making patient selection, standardizing evaluating systems of therapeutic effects, and establishment of the most effective protocols), NACRT will likely become an indispensable therapeutic option in the fight against this highly aggressive cancer.

Conflict of Interest

Yuko Kitagawa received honoraria from Yakult and research funding from Kyowa Hakko Kirin Co., Ltd and Yakult. No other author has a conflict of interest to report.

References

1. Jemal A, Siegel R, Ward E, Murray T, Xu J, Smigal C, Thun MJ: Cancer statistics, 2006. CA Cancer J Clin 2006; **56**: 106–130. [Medline] [CrossRef]
2. Matsuda A, Matsuda T, Shibata A, Katanoda K, Sobue T, Nishimoto H, Japan Cancer Surveillance Research Group: Cancer incidence and incidence rates in Japan in 2008: a study of 25 population-based cancer registries for the Monitoring of Cancer Incidence in Japan (MCIJ) project. Jpn J Clin Oncol 2014; **44**: 388–396. [Medline] [CrossRef]
3. Geer RJ, Brennan MF: Prognostic indicators for survival after resection of pancreatic adenocarcinoma. Am J Surg 1993; **165**: 68–72, discussion 72–73. [Medline] [CrossRef]
4. Sohn TA, Yeo CJ, Cameron JL, Koniaris L, Kaushal S, Abrams RA, Sauter PK, Coleman J, Hruban RH, Lillemoe KD: Resected adenocarcinoma of the pancreas – 616 patients: results, outcomes, and prognostic indicators. J Gastrointest Surg 2000; **4**: 567–579. [Medline] [CrossRef]
5. Bilimoria KY, Bentrem DJ, Ko CY, Ritchey J, Stewart AK, Winchester DP, Talamonti MS: Validation of the 6th edition AJCC pancreatic cancer staging system: Report from the National Cancer Database. Cancer 2007; 110: 738–744.
6. Breslin TM, Hess KR, Harbison DB, Jean ME, Cleary KR, Dackiw AP, Wolff RA, Abbruzzese JL, Janjan NA, Crane CH, Vauthey JN, Lee JE, Pisters PW, Evans DB: Neoadjuvant chemoradiotherapy for adenocarcinoma of the pancreas: treatment variables and survival duration. Ann Surg Oncol 2001; **8**: 123–132. [Medline] [CrossRef]

7. Tempero MA, Malafa MP, Behrman SW, Benson AB, Casper ES, Chiorean EG, Chung V, Cohen SJ, Czito B, Engebretson A, Feng M, Hawkins WG, Herman J, Hoffman JP, Ko A, Komanduri S, Koong A, Lowy AM, Ma WW, Merchant NB, Mulvihill SJ, Muscarella P, Nakakura EK, Obando J, Pitman MB, Reddy S, Sasson AR, Thayer SP, Weekes CD, Wolff RA, Wolpin BM, Burns JL, Freedman-Cass DA: Pancreatic adenocarcinoma, version 2.2014: featured updates to the NCCN guidelines. J Natl Compr Canc Netw 2014; **12**: 1083–1093. [Medline]
8. Varadhachary GR, Wolff RA, Crane CH, Sun CC, Lee JE, Pisters PW, Vauthey JN, Abdalla E, Wang H, Staerkel GA, Lee JH, Ross WA, Tamm EP, Bhosale PR, Krishnan S, Das P, Ho L, Xiong H, Abbruzzese JL, Evans DB: Preoperative gemcitabine and cisplatin followed by gemcitabine-based chemoradiation for resectable adenocarcinoma of the pancreatic head. J Clin Oncol 2008; **26**: 3487–3495. [Medline] [CrossRef]
9. Chun YS, Cooper HS, Cohen SJ, Konski A, Burtness B, Denlinger CS, Astsaturov I, Hall MJ, Hoffman JP: Significance of pathologic response to preoperative therapy in pancreatic cancer. Ann Surg Oncol 2011; **18**: 3601–3607. [Medline] [CrossRef]
10. Aschele C, Cionini L, Lonardi S, Pinto C, Cordio S, Rosati G, Artale S, Tagliagambe A, Ambrosini G, Rosetti P, Bonetti A, Negru ME, Tronconi MC, Luppi G, Silvano G, Corsi DC, Bochicchio AM, Chiaulon G, Gallo M, Boni L: Primary tumor response to preoperative chemoradiation with or without oxaliplatin in locally advanced rectal cancer: pathologic results of the STAR-01 randomized phase III trial. J Clin Oncol 2011; **29**: 2773–2780. [Medline] [CrossRef]
11. García-Aguilar J, Hernandez de Anda E, Sirivongs P, Lee SH, Madoff RD, Rothenberger DA: A pathologic complete response to preoperative chemoradiation is associated with lower local recurrence and improved survival in rectal cancer patients treated by mesorectal excision. Dis Colon Rectum 2003; **46**: 298–304. [Medline] [CrossRef]
12. Martin ST, Heneghan HM, Winter DC: Systematic review and meta-analysis of outcomes following pathological complete response to neoadjuvant chemoradiotherapy for rectal cancer. Br J Surg 2012; **99**: 918–928. [Medline] [CrossRef]
13. Meredith KL, Weber JM, Turaga KK, Siegel EM, McLoughlin J, Hoffe S, Marcovalerio M, Shah N, Kelley S, Karl R: Pathologic response after neoadjuvant therapy is the major determinant of survival in patients with esophageal cancer. Ann Surg Oncol 2010; **17**: 1159–1167. [Medline] [CrossRef]
14. Ogston KN, Miller ID, Payne S, Hutcheon AW, Sarkar TK, Smith I, Schofield A, Heys SD: A new histological grading system to assess response of breast cancers to primary chemotherapy: prognostic significance and survival. Breast 2003; **12**: 320–327. [Medline] [CrossRef]
15. Symmans WF, Peintinger F, Hatzis C, Rajan R, Kuerer H, Valero V, Assad L, Poniecka A, Hennessy B, Green M, Buzdar AU, Singletary SE, Hortobagyi GN, Pusztai L: Measurement of residual breast cancer burden to predict survival after neoadjuvant chemotherapy. J Clin Oncol 2007; **25**: 4414–4422. [Medline] [CrossRef]
16. Zhao Q, Rashid A, Gong Y, Katz MH, Lee JE, Wolf R, Balachandran A, Varadhachary GR, Pisters PW, Wang H, Gomez HF, Abbruzzese JL, Fleming JB, Wang H: Pathologic complete response to neoadjuvant therapy in patients with pancreatic ductal adenocarcinoma is associated with a better prognosis. Ann Diagn Pathol 2012; **16**: 29–37. [Medline] [CrossRef]
17. Moutardier V, Magnin V, Turrini O, Viret F, Hennekinne-Mucci S, Gonçalves A, Pesenti C, Guiramand J, Lelong B, Giovannini M, Monges G, Houvenaeghel G, Delpero JR: Assessment of pathologic response after preoperative chemoradiotherapy and surgery in pancreatic adenocarcinoma. Int J Radiat Oncol Biol Phys 2004; **60**: 437–443. [Medline] [CrossRef]
18. Evans DB, Rich TA, Byrd DR, Cleary KR, Connelly JH, Levin B, Charnsangavej C, Fenoglio CJ, Ames FC: Preoperative chemoradiation and pancreaticoduodenectomy for adenocarcinoma of the pancreas. Arch Surg 1992; **127**: 1335–1339. [Medline] [CrossRef]
19. Le Scodan R, Mornex F, Partensky C, Mercier C, Valette PJ, Ychou M, Roy P, Scoazec JY: Histopathological response to preoperative chemoradiation for resectable pancreatic adenocarcinoma: the French Phase II FFCD 9704-SFRO Trial. Am J Clin Oncol 2008; **31**: 545–552. [Medline] [CrossRef]
20. Adams S, Chakravarthy AB, Donach M, Spicer D, Lymberis S, Singh B, Bauer JA, Hochman T, Goldberg JD, Muggia F, Schneider RJ, Pietenpol JA, Formenti SC: Preoperative concurrent paclitaxel–radiation in locally advanced breast cancer: pathologic response correlates with five-year overall survival. Breast Cancer Res Treat 2010; **124**: 723–732. [Medline] [CrossRef]
21. Pasini F, de Manzoni G, Zanoni A, Grandinetti A, Capirci C, Pavarana M, Tomezzoli A, Rubello D, Cordiano C: Neoadjuvant therapy with weekly docetaxel and cisplatin, 5-fluorouracil continuous infusion, and concurrent radiotherapy in patients with locally advanced esophageal cancer produced a high percentage of long-lasting pathological complete response: a phase 2 study. Cancer 2013; **119**: 939–945. [Medline] [CrossRef]
22. Chatterjee D, Katz MH, Rashid A, Varadhachary GR, Wolff RA, Wang H, Lee JE, Pisters PW, Vauthey JN, Crane C, Gomez HF, Abbruzzese JL, Fleming JB, Wang H: Histologic grading of the extent of residual carcinoma following neoadjuvant chemoradiation in pancreatic ductal adenocarcinoma: a predictor for patient outcome. Cancer 2012; **118**: 3182–3190. [Medline] [CrossRef]
23. Chua TC, Saxena A: Preoperative chemoradiation followed by surgical resection for resectable pancreatic cancer: a review of current results. Surg Oncol 2011; **20**: e161–e168. [Medline] [CrossRef]
24. Takahashi S, Aiura K, Saitoh J, Hayatsu S, Kitajima M, Ogata Y: Treatment strategy for pancreatic head cancer: pylorus-preserving pancreatoduodenectomy, intraoperative radiotherapy and portal catheterization. Digestion 1999; **60**(Suppl 1): 130–134. [Medline] [CrossRef]
25. Aiura K, Takahashi S, Matsui J, Ueda M, Kitagawa Y: Beneficial effects of 5-fluorouracil and heparin-based portal infusion chemotherapy combined with mitomycin C and cisplatin after curative resection of pancreatic cancer. Pancreatology 2010; **10**: 250–258. [Medline] [CrossRef]
26. Golcher H, Brunner T, Grabenbauer G, Merkel S, Papadopoulos T, Hohenberger W, Meyer T: Preoperative chemoradiation in adenocarcinoma of the pancreas. A single centre experience advocating a new treatment strategy. Eur J Surg Oncol 2008; **34**: 756–764. [Medline] [CrossRef]
27. Hall EJ, Giaccia AJ: Cancer biology. In: Radiobiology for the Radiologist 7th ed, Hall EJ, Giaccia AJ (eds) Philadelphia, PA, Wolters Kluwer Health: Lippincott Williams & Wilkins, 2011; 294–296.