

BRIEF COMMUNICATION

Imaging of Cystic Lung Lesions in Infants Using Pointwise Encoding Time Reduction with Radial Acquisition (PETRA)

Kumiko Nozawa¹, Tetsu Niwa^{1,2*}, and Noriko Aida¹

Keywords: *computed tomography, congenital cystic lung disease, magnetic resonance imaging, pointwise encoding time reduction with radial acquisition, ultrashort echo time imaging*

Cystic lung disease encompasses various pathologic conditions such as air, fluid, or a combination of both. Among them, congenital cystic lesions comprise congenital pulmonary airway malformation, bronchogenic cyst, pulmonary sequestration, bronchial atresia and congenital lobar emphysema. These lesions should be precisely evaluated for size, location, and the relationship with the surrounding structures; however, this is sometimes difficult, particularly in infants. Such lesions are typically assessed using CT, which provides fast and high spatial resolution imaging. However, CT has a certain amount of radiation exposure. Although there is no radiation exposure with MRI, its use in the lung has been restricted due to the extremely short T_2 , low proton density, susceptibility artifact, and the heart and respiratory motion. Therefore, MRI is mainly used for assessing lesions in the mediastinum, pleura, and chest wall. Assessment of lung lesions such as nodules and those with ground glass opacity on MRI are still controversial. Moreover, air-containing cystic lung lesions have less proton density and their imaging is challenging, particularly in infants whose thorax is very small, making it difficult to obtain high spatial resolution imaging on MRI.

However, recent application of ultrashort echo time (UTE) imaging allows visualization of the lung and airway.^{1–3} One UTE technique, pointwise encoding time reduction with radial acquisition (PETRA), acquires data in central k space in pointwise encoding and outer k space in radial projection.⁴

In addition, PETRA uses very limited gradient changes in the MRI unit. As a result, this sequence provides a relatively good UTE image as well as a silent scan.⁵ We present two infants diagnosed with congenital cystic lung disease on fetal sonography and MRI, who underwent both CT and PETRA at 6 months of age for assessing the detailed pathologic condition and resectability. After obtaining Institutional Review Board approval, informed consent was obtained from the parents.

MRI was performed on a 3T unit (Magnetom Verio, Siemens AG, Erlangen, Germany) using a body matrix coil. Infants were wrapped in a vacuum immobilization bag and intravenously sedated. PETRA was obtained using 3D radial sampling based on the UTE technique; the parameters included TR/TE = 5000/0.07 ms, flip angle = 6°, FOV = 284 × 284 × 284 mm, matrix = 352 × 352 × 352, echo space = 3.75 ms, slice thickness = 0.8 mm, radial spoke = 55000, and section orientation, sagittal plane (resolution = 0.81 × 0.81 × 0.8 mm). Acquisition time was 4 min 40 s, and no respiratory or cardiac gating was used. The recognizability and area of the cystic lung lesions were comparative or slightly lower on PETRA than on CT (Figs. 1 and 2).

Although detailed visibility of the anatomical structures was superior on CT than on PETRA, a use of PETRA such as in an initial imaging examination or follow-up study for lung lesions will eliminate the use of CT scans in infants, particularly who need repeated CT scans, thus reducing radiation exposure. Imaging quality of UTE for the lung may be improved by a use of respiratory gating or another sampling method such as stack-of-spirals acquisition.

PETRA may provide a relatively good image quality of cystic lung lesions in infants.

Conflicts of Interest

The authors declare that they have no conflicts of interest.

¹Department of Radiology, Kanagawa Children's Medical Center, Kanagawa, Japan
²Department of Diagnostic Radiology, Tokai University School of Medicine, 143 Shimokasuya, Isehara, Kanagawa 259-1193, Japan

*Corresponding author, Phone: +81-463-93-1121, Fax: +81-463-93-6827, E-mail: niwat@tokai-u.jp

©2018 Japanese Society for Magnetic Resonance in Medicine

This work is licensed under a Creative Commons Attribution-NonCommercial-NoDerivatives International License.

Received: July 7, 2018 | Accepted: October 24, 2018

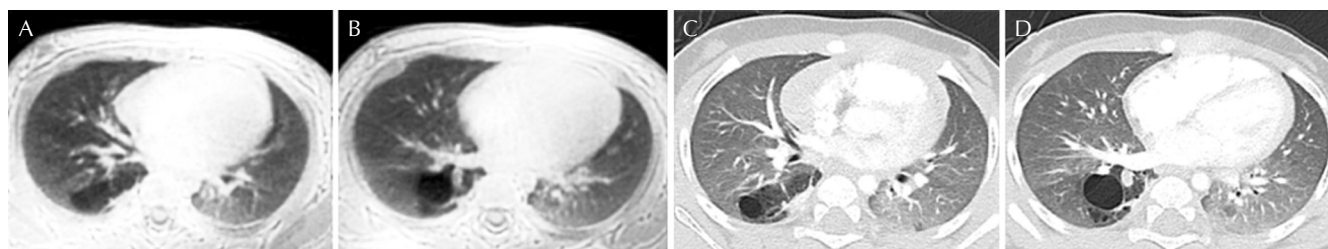


Fig. 1 Multiple cystic lesions in a 6-month-old girl in the right lower lung, which was resected and pathologically diagnosed as bronchial atresia after resection. Pointwise encoding time reduction with radial acquisition (PETRA) (**A** and **B**) well demonstrates cystic lesions in the right lower lung compared with CT (**C** and **D**). The area of the cystic lesions is comparable between PETRA and CT. Small cystic lesions were better visualized on CT than on PETRA.

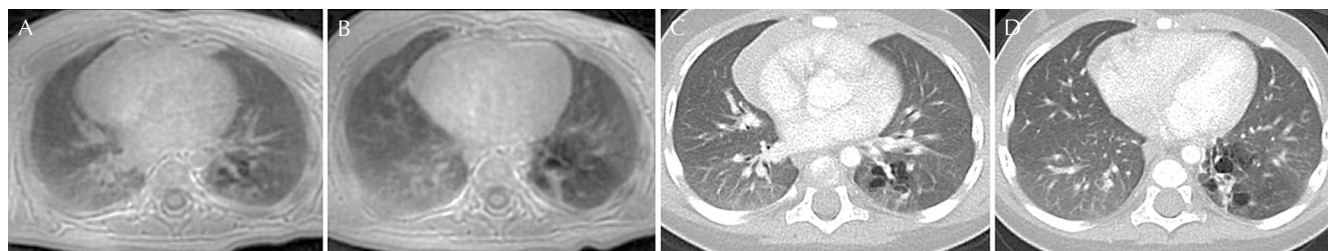


Fig. 2 Multiple cystic lesions in the left lower lung in a 6-month-old girl. Compared with CT, pointwise encoding time reduction with radial acquisition (PETRA) (**A** and **B**) demonstrates multiple cystic lesions relatively well, except for small cystic lesions (**C** and **D**). The area of the cystic lesions is comparable between PETRA and CT.

References

1. Ohno Y, Koyama H, Yoshikawa T, et al. Pulmonary high-resolution ultrashort TE MR imaging: comparison with thin-section standard- and low-dose computed tomography for the assessment of pulmonary parenchyma diseases. *J Magn Reson Imaging* 2016; 43:512–532.
2. Niwa T, Nozawa K, Aida N. Visualization of the airway in infants with MRI using pointwise encoding time reduction with radial acquisition (PETRA). *J Magn Reson Imaging* 2017; 45:839–844.
3. Higano NS, Fleck RJ, Spielberg DR, et al. Quantification of neonatal lung parenchymal density via ultrashort echo time MRI with comparison to CT. *J Magn Reson Imaging* 2017; 46:992–1000.
4. Grodzki DM, Jakob PM, Heismann B. Ultrashort echo time imaging using pointwise encoding time reduction with radial acquisition (PETRA). *Magn Reson Med* 2012; 67:510–518.
5. Aida N, Niwa T, Fujii Y, et al. Quiet T_1 -weighted pointwise encoding time reduction with radial acquisition for assessing myelination in the pediatric brain. *AJNR Am J Neuroradiol* 2016; 37:1528–1534.