

An Infected Aneurysm of the Vertebral Artery Treated with a Stent-graft: A Case Report

Kenji HASHIMOTO,^{1,3} Fumiaki ISAKA,^{2,3} and Kohsuke YAMASHITA³

¹Department of Neurosurgery, Kishiwada City Hospital, Kishiwada, Osaka;

²Department of Neurosurgery, Hikone Municipal Hospital, Hikone, Shiga;

³Department of Neurosurgery, Osaka Red Cross Hospital, Osaka, Osaka

Abstract

In a 75-year-old man, a growing vertebral artery aneurysm at the C3/4 intervertebral level was found at postoperative evaluation of cervical abscess, which was diagnosed as a complication of sepsis subsequent to cholangitis. Even after a successful antibiotic treatment and a surgical drainage, the aneurysm grew enough to cause compression of esophagus and trachea. The aneurysm was judged to be infection-related, based on the clinical course and the anatomical vicinity to the abscess. Following a dual antiplatelet treatment (clopidogrel 75 mg and aspirin 100 mg per day) for a week, the patient underwent endovascular treatment of the aneurysm with a stent-graft. Postoperative angiography showed complete obliteration of the aneurysm with preserving patency of the vertebral artery. A dual antiplatelet treatment was continued for 6 months and was changed to a single antiplatelet treatment (clopidogrel 75 mg per day) thereafter. Neither recurrence of the aneurysm nor stent-graft infection was observed for 4 years of follow-up. This case illustrates the potential use of a stent-graft in the treatment of an infected aneurysm.

Key words: aneurysm, stent-graft, vertebral

Introduction

Extracranial vertebral aneurysms are rare vascular lesions and result from a variety of causes, such as bacterial infection, rheumatoid arthritis, injuries, neurofibromatosis type 1, fibromuscular dysplasia, and osteomyelitis. The location of the aneurysm has been reported as the first segment in 17.5%, the second in 70%, and the third in 12.5%.¹⁾ Remain untreated, they could encompass adverse outcomes including hemorrhage, enlargement, vessel occlusion, and distal embolism.²⁾ The traditional treatment option was surgical correction for accessible lesions, and anticoagulation or antiplatelet therapy for inaccessible lesions.^{3–5)} These options were frequently invasive or unsatisfactory, respectively. Endovascular treatment with stent placement and coil occlusion has become a common first-line treatment of pseudoaneurysm with the goal of parent artery preservation.^{6–8)} Several case reports recently described endovascular procedures of treatment using a stent-graft for pseudoaneurysm or arteriovenous fistula of extracranial carotid or vertebral artery.^{9,10)} It would be still controversial to place a stent-graft in the treatment of an infection-related aneurysm. In this article we present our experience using a coronary

stent-graft to treat a presumed pseudoaneurysm of the extracranial vertebral artery, which arose following local infection.

Case Report

A 75-year-old man was hospitalized due to high fever and severe epigastric pain and was found to suffer from acute cholangitis, which progressed to sepsis and systemic multiple abscesses. One of the abscesses which compressed the trachea was surgically drained and tracheostomy was performed by otolaryngologists. The responsible bacteria of sepsis and the cervical abscess was methicillin-sensitive *Staphylococcus aureus*. Approximately 1 month after the drainage, a vertebral aneurysm was detected ventral to the spinal column at the C3/4 intervertebral level (Fig. 1). The aneurysm continued growing enough to compress the trachea, though sepsis attained remission due to intensive antibiotic therapy (Fig. 2). The aneurysm enlarged from 20 mm to 28 mm in height in a week.

Balloon test occlusion and aneurysm evaluation were performed. The diameters of the vertebral arteries are nearly equal. No neurological symptoms were observed while the right vertebral artery was occluded with a balloon catheter for 15 minutes. The neck width along the

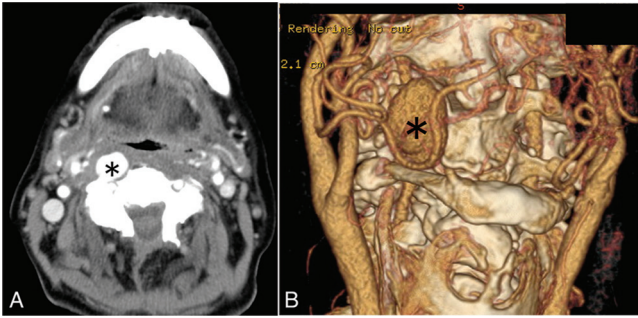


Fig. 1 Contrast-enhanced computed tomography (CT) and CT angiography show a large aneurysm (*asterisk*) of the right extracranial vertebral artery. A: Axial view of enhanced CT. B: Frontal view of CT angiography.

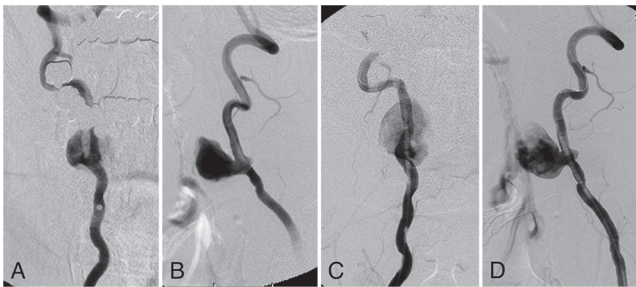


Fig. 2 Digital subtraction angiography of the right vertebral artery shows an aneurysm located between transverse foramina of third and fourth cervical vertebrae. A, B: First examination; anteroposterior view and lateral, retrospectively. C, D: Second examination 7 days after the first. Anteroposterior view and lateral, retrospectively. The aneurysm grew from 20 mm to 28 mm in height.

vertebral artery was 6.1 mm from the three-dimensional digital subtraction angiography. Endovascular treatment was indicated to prevent future bleeding and compressive airway obstruction. Aneurysm exclusion with a stent-graft was the procedure of choice to preserve the parent artery. Informed written consent for using stent-graft in the treatment of an extracranial vertebral aneurysm was obtained from the patient and his family, and an off-label use of the coronary stent-graft was approved by the Institutional Review Board of the Osaka Red Cross Hospital. Following a dual antiplatelet treatment with clopidogrel 75 mg and aspirin 100 mg per day for a week, the patient underwent endovascular treatment under local anesthesia. Heparin (5,000 IU) was intravenously administered immediately after a 6 Fr 25 cm introducer sheath (Terumo Corporation, Tokyo) was placed through the femoral artery, and appropriate dose of heparin was added as needed to maintain an activated clotting time (ACT) between 300 s and 330 s during the procedure. A 6F Launcher guiding catheter (Medtronic, Tokyo) was navigated to the right vertebral artery proximal to

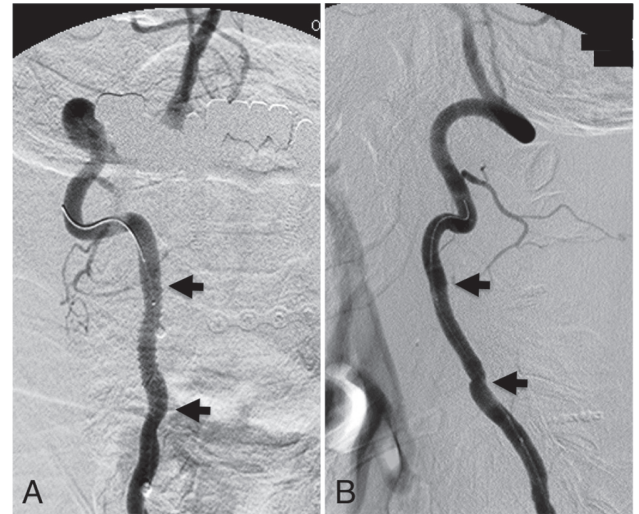

Fig. 3 At the end of the treatment, the digital subtraction angiogram shows total exclusion of the aneurysm with preservation of a normal vertebral lumen. A: Anteroposterior view, B: lateral view. Arrows indicate both ends of the stent-graft.

the aneurysm through the introducer sheath. Intravascular ultrasonography showed that the diameter of the proximal vertebral artery was media-media 4.2×4.2 mm and that of the distal vertebral artery was media-media 4.1×4.2 mm. Guardwire® (Medtronic, Tokyo) was advanced up to the right vertebral artery distal to the aneurysm. The balloon of Guardwire was inflated in the right vertebral artery just below the level of cervical atlas. We adopted this protection to prevent embolism which could be caused by endoleak. Jostent GraftMaster Coronary Stent Graft (Abbott Japan Co. Ltd., Tokyo) 4×19 mm was advanced over Guardwire, deployed across the aneurysm neck, and then dilated with 4×20 mm Submarine balloon (St. Jude Medical, Tokyo) to be fixed in the vessel. Inflation of the balloon to its nominal pressure 8 atmospheres failed to make the stent fit to the vessel wall and endoleak was followed. Additional inflation up to 14 atmospheres (4.33 mm in diameter) was necessary. Its rated burst pressure is 17 atmospheres. The balloon of Guardwire was deflated after blood was evacuated in the obstructed lumen in the right vertebral artery. Postoperative angiography showed that Jostent GraftMaster was deployed successfully with aneurysm exclusion and patency of the parent artery (Fig. 3). The patient remained asymptomatic without neurological deficits or local pain. No distal embolism was detected with magnetic resonance image (MRI) 3 days after the procedure.

A dual antiplatelet treatment with clopidogrel 75 mg and aspirin 100 mg per day was continued for 6 months and was shifted to a single antiplatelet treatment with clopidogrel 75 mg per day thereafter. Cefazolin, piperacillin, and tazobactam were intravenously administered for a month after the procedure. Oral sulfamethoxazole-trimethoprim

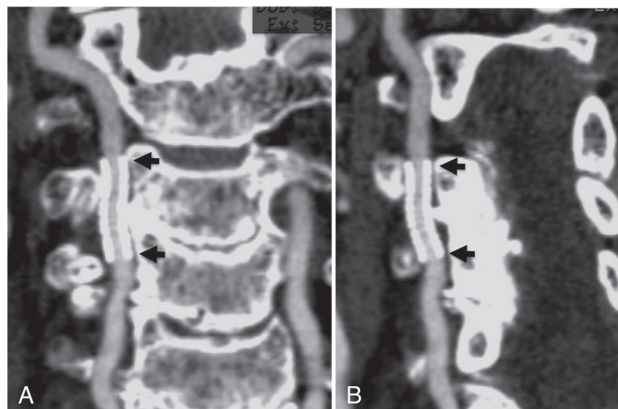


Fig. 4 Computed tomography (CT) angiography with multiplanar reconstruction 4 years after the procedure shows the stent-graft fully patent without deformation. Complete exclusion of the aneurysm was observed during the follow-up period. A: Anteroposterior view, B: oblique view.

was supposed to be administered ever since. Follow-up computed tomography (CT) angiography after 4 years demonstrated that aneurysm exclusion and full patency of the stent-graft without deformation is preserved. Infectious symptoms have not been observed since the stent was placed (Fig. 4).

Discussion

We report the case of a 75-year-old man with an extracranial vertebral aneurysm which appeared associated with local or systemic infection treated with a stent-graft. Possible treatment options for this aneurysm would be surgical ligation of the parent artery, internal trapping of the vertebral artery, endovascular occlusion of the aneurysm, placement of a bare stent/stent-graft or combination of these procedures, etc.

The treatment of aneurysms in the cervical region as well as in other regions is also going through a transition, i.e., surgical treatment is replaced by endovascular treatment in many cases and stent-graft placement is gradually being prevailed. In 1991, the first aortic aneurysm treatment using a stent-graft was reported.¹¹⁾ This rapidly evolving technique is being widely adapted to the treatment of aneurysms and direct injuries of large vessels such as the aorta and the iliofemoral arteries etc.^{12,13)} In 2000, Simionato et al. reported the effectiveness of stent-graft therapy for a common carotid artery pseudoaneurysm.¹⁴⁾ They described in their report that a stent-graft with a delivery system of sufficient length to reach the upper cervical region from a femoral artery access was not commercially available. Therefore, they needed to crimp a stent-graft manually on an angioplasty balloon catheter and advanced a guiding sheath as large as 9 Fr into a parent artery to deliver them. This has

made it difficult to apply a stent-graft to the treatment of vertebral lesion as a first line option.

Stent-grafts available in our country are mainly designed for the application to the bile ducts or the peripheral vessels, of which delivery systems would be large in diameter and short in length for application to the vertebral artery. A stent-graft designed for the coronary artery appears suitable for the vertebral artery in diameter and also in length. In this report, we used Jostent GraftMaster Coronary Stent Graft to exclude the aneurysm and to preserve patency of the parent artery. It consists of two stainless steel flexible stents with an expandable polytetrafluoroethylene (PTFE) graft material wrapped between the two stents. The stent-graft varies 3.0–5.0 mm in diameter and 9–26 mm in length. Usable length of delivery system is 140–145 cm (a stent-graft 3.0–4.0 mm in diameter) or 150–155 cm (4.5–5.0 mm). The Food and Drug Administration (FDA) has approved GraftMaster for commercial use in selected patients under a Humanitarian Device Exemption (HDE) for use in the treatment of free perforations in native vessels or saphenous vein bypass grafts greater than or equal to 2.75 mm in diameter. These product features have advantage in application for the treatment of cervical or intracranial vessel lesions though GraftMaster is indeed designed only for coronary use. Several cases of the endovascular treatment in which GraftMaster was used for pseudoaneurysms of cervical or intracranial arteries have been reported.^{8,15)}

The vessel lesion in this case was presumed to be pseudoaneurysm which arose due to systemic or local infection. Facing the treatment, we first thought that preservation of the affected vertebral artery was preferred though balloon test occlusion resulted in tolerable, because we were afraid that another pseudoaneurysm might actually arise on the ipsilateral carotid artery or the contralateral vertebral artery after our treatment even though infection had completely subsided. At this stage, we ruled out surgical ligation or internal trapping of the parent artery from the choices. Second, we anticipated that it might be less fraught with infection risk to place a stent-graft in the vessel lumen than to deploy a number of coils in the large aneurysm which extended into the space where an abscess usually exists. We were also afraid that large coil mass might compress trachea and later damage its wall. It would be still controversial to place a stent-graft as a foreign substance at an infection site. Some reports describe the cases with good results of the treatment with PTFE graft for mycotic aneurysm, others with bad results.^{16–18)} It would be proper at least to avoid to place a stent-graft in the vicinity of infection site in the active stage. Since sepsis and the cervical abscess were completely abated in the present case, we finally chose stent-graft placement among treatment options understanding its potential risk of infection. In general, it is often difficult for a stent-graft to pass through a tortuous part of the artery and is

usually unsuited to be deployed to a curved site. In our clinical experience, stubborn endoleak in the treatment with a stent-graft tends to occur more frequently at a lesion of the carotid artery than at that of the vertebral artery. This seems because the vertebral artery is supported by the transverse foramina of the vertebrae. The present case fortunately had favorable conditions for the treatment with a stent-graft except infection risk.

It also remains unclear how long the patient should be given antibiotics after stent-graft placement for an infection-related aneurysm. The present case had suffered from chronic rheumatoid arthritis for more than 20 years and was necessary to continue steroid and immunosuppressant. Therefore, oral sulfamethoxazole-trimethoprim was supposed to be administered for the rest of his life.

Regarding distal protection device, it is not obvious if the process is necessary. Though thrombi in an aneurysm are not likely to go through the stent mesh to the vessel lumen, it is not absolutely safe due to endoleak which may carry potential thrombi out of the aneurysm and cause embolism.

Conclusion

The aneurysm of the extracranial vertebral artery was effectively excluded with a stent-graft. Jostent GraftMaster Coronary Stent Graft appears suitable device for the treatment of an aneurysm in the cervical region. It would be, however, still controversial to place a stent-graft in the treatment of an infection-related aneurysm.

Conflicts of Interest Disclosure

Dr. Hashimoto and all the co-authors declare no disclosures and no conflicts of interest. All the authors have made substantial contributions to the intellectual content of the paper, have approved the final manuscript, and agree with submission to this journal.

References

- 1) Lasjaunias P, Berenstein A, Brugge KG: Extradural vertebral aneurysms, in *Surgical Neuroangiography*, vol 2. Berlin, Springer-Verlag, 1987, pp 269–270
- 2) Prêtre R, Kürsteiner K, Reverdin A, Faidutti B: Blunt carotid artery injury: devastating consequences of undetected pseudoaneurysm. *J Trauma* 39: 1012–1014, 1995
- 3) Charbel FT, Gonzales-Portillo G, Hoffman W, Cochran E: Distal internal carotid artery pseudoaneurysms: technique and pitfalls of surgical management: two technical case reports. *Neurosurgery* 45: 643–648; discussion 648–649, 1999
- 4) Lueg EA, Awerbuck D, Forte V: Ligation of the common carotid artery for the management of a mycotic pseudoaneurysm of an extracranial internal carotid artery. A case report and review of the literature. *Int J Pediatr Otorhinolaryngol* 33: 67–74, 1995

- 5) Fabian TC, Patton JH, Croce MA, Minard G, Kudsk KA, Pritchard FE: Blunt carotid injury. Importance of early diagnosis and anticoagulant therapy. *Ann Surg* 223: 513–522; discussion 522–525, 1996
- 6) Matsuura JH, Rosenthal D, Jerius H, Clark MD, Owens DS: Traumatic carotid artery dissection and pseudoaneurysm treated with endovascular coils and stent. *J Endovasc Surg* 4: 339–343, 1997
- 7) Mericle RA, Lanzino G, Wakhloo AK, Guterman LR, Hopkins LN: Stenting and secondary coiling of intracranial internal carotid artery aneurysm: technical case report. *Neurosurgery* 43: 1229–1234, 1998
- 8) Phatouros CC, Sasaki TY, Higashida RT, Malek AM, Meyers PM, Dowd CF, Halbach VV: Stent-supported coil embolization: the treatment of fusiform and wide-neck aneurysms and pseudoaneurysms. *Neurosurgery* 47: 107–113; discussion 113–115, 2000
- 9) Yi AC, Palmer E, Luh GY, Jacobson JP, Smith DC: Endovascular treatment of carotid and vertebral pseudoaneurysms with covered stents. *AJNR Am J Neuroradiol* 29: 983–987, 2008
- 10) Sadato A, Satow T, Ishii A, Takayama M, Hashimoto N: Large vertebral arteriovenous fistula treated with stent-grafts—case report. *Neurol Med Chir (Tokyo)* 43: 250–254, 2003
- 11) Parodi JC, Palmaz JC, Barone HD: Transfemoral intraluminal graft implantation for abdominal aortic aneurysms. *Ann Vasc Surg* 5: 491–499, 1991
- 12) Murphy KD, Richter GM, Henry M, Encarnacion CE, Le VA, Palmaz JC: Aortoiliac aneurysms: management with endovascular stent-graft placement. *Radiology* 198: 473–480, 1996
- 13) Marston WA, Criado E, Mauro MA, Keagy BA: Transbrachial endovascular exclusion of an axillary artery pseudoaneurysm with PTFE-covered stents. *J Endovasc Surg* 2: 172–176, 1995
- 14) Simionato F, Righi C, Melissano G, Rolli A, Chiesa R, Scotti G: Stent-graft treatment of a common carotid artery pseudoaneurysm. *J Endovasc Ther* 7: 136–140, 2000
- 15) Wang C, Xie X, You C, Zhang C, Cheng M, He M, Sun H, Mao B: Placement of covered stents for the treatment of direct carotid cavernous fistulas. *AJNR Am J Neuroradiol* 30: 1342–1346, 2009
- 16) Baril DT, Ellozy SH, Carroccio A, Patel AB, Lookstein RA, Marin ML: Endovascular repair of an infected carotid artery pseudoaneurysm. *J Vasc Surg* 40: 1024–1027, 2004
- 17) Gupta V, Jain V, Mathuria SN, Khandelwal N: Endovascular treatment of a mycotic intracavernous carotid artery aneurysm using a stent graft. *Interv Neuroradiol* 19: 313–319, 2013
- 18) Ishida M, Kato N, Hirano T, Shimono T, Yasuda F, Tanaka K, Yada I, Takeda K: Limitations of endovascular treatment with stent-grafts for active mycotic thoracic aortic aneurysm. *Cardiovasc Intervent Radiol* 25: 216–218, 2002

Address reprint requests to: Kenji Hashimoto, MD, PhD, Department of Neurosurgery, Kishiwada City Hospital, Kishiwada, Osaka 596-8501, Japan.
e-mail: hashi-ken@umin.org