

Infiltration of CD8⁺ T cells in Non-Small Cell Lung Cancer is Associated with Dedifferentiation of Cancer Cells, but not with Prognosis

MASUKO MORI, HARUO OHTANI,¹ YOSHITAKA NAITO,¹
MOTOYASU SAGAWA,² MASAMI SATO,² SHIGEFUMI
FUJIMURA² and HIROSHI NAGURA¹

*Department of Pathology, ²Department of Thoracic Surgery,
Institute of Development, Aging and Cancer, Tohoku
University, Sendai 980–8575, ¹Department of Pathology,
Tohoku University School of Medicine, Sendai 980–8574*

MORI, M., OHTANI, H., NAITO, Y., SAGAWA, M., SATO, M., FUJIMURA, S. and NAGURA, H. *Infiltration of CD8⁺ T cells in Non-Small Cell Lung Cancer is Associated with dedifferentiation of Cancer Cells, but not with Prognosis.* Tohoku J. Exp. Med., 2000, **191** (2), 113–118 — CD8⁺ T cells infiltrating within cancer cell nests in human colorectal cancer were associated with a favorable patients' survival, suggesting the presence of anti-tumor immunity. The present study was designed to examine this concept in non-small cell lung cancer (NSCLC) by a retrospective analysis of 128 surgically resected cases. Immunohistochemical analysis showed that the number of CD8⁺ T cells within cancer cell nests in NSCLC was related to the histological subtype (large cell carcinoma or squamous cell carcinoma > adenocarcinoma) and the degree of dedifferentiation (undifferentiated type > differentiated type). In contrast to colorectal cancer, the number of CD8⁺ T cells in NSCLC had no statistically significant impact on the patients' survival. The present study demonstrated that the degree of infiltration of CD8⁺ T cells within cancer cell nests is dependent on the dedifferentiation of cancer cells in NSCLC, which could be one of the important aspects for the study of tumor immunity. ——— tumor-infiltrating lymphocytes; non-small cell lung cancer; CD8; immunohistochemistry © 2000 Tohoku University Medical Press

Tumor-infiltrating lymphocytes (TILs) (House and Watt 1979), found in a variety of cancer tissues, have been considered to be a manifestation of host immune reactions against cancer cells (Rosenberg 1996), whereas the pathophysiological roles of TILs remain controversial. TILs contained significantly higher populations of CD3⁺ T cells and CD8⁺ T cells than the corresponding peripheral blood lymphocytes (Kuo et al. 1998). We have previously shown that

Received February 23, 2000; revision accepted for publication May 22, 2000.

Present address for Dr. Masuko Mori, Fukujuji Medical Center, 2–3–1 Nakayama-Yoshinari, Sendai 989–3203, Japan.

For reprints request, contact M. Mori at the present address.

Epstein-Barr virus-associated gastric cancer is associated with massive infiltration of activated CD8⁺ T cells possessing higher levels of proliferation activity and perforin granules (Saiki et al. 1996). In addition, we found that the infiltration of CD8⁺ T cells in colorectal cancer tissues could be a novel prognostic factor (Naito et al. 1998). Thus, CD8⁺ T cells may play an important role in various types of immune reactions in cancer tissues. In lung cancer, cases with massive infiltration of TILs have been reported (Chen et al. 1998). However, there have been few reports concerning CD8⁺ T cells in human non-small cell lung cancer (NSCLC). We expanded our previous study to NSCLC and revealed that CD8⁺ T cells in NSCLC are closely related to the dedifferentiation of cancer cells.

MATERIALS AND METHODS

The present study is a retrospective study based on 128 cases of surgically resected NSCLC, which were selected from the files of Sendai Kosei Hospital and Department of Thoracic Surgery, Institute of Development, Aging and Cancer, Tohoku University operated during 1988 to 1991. All cases were clinicopathologically judged to be a complete resection of cancer, which were followed up for more than 5 years. No cases received radiation or chemotherapy before operation. They consisted of 45 cases of adenocarcinoma, 54 of squamous cell carcinoma and 29 of large cell carcinoma according to the WHO's classification (Travis et al. 1999). We classified the degree of differentiation into well, moderately and poorly differentiated for adenocarcinoma and squamous cell carcinoma. The stage was I in 65 patients, II in 24, IIIa in 35 and IIIb in 4.

Formalin-fixed, paraffin-embedded sections containing representative areas were used for the immunohistochemical analysis for CD8. The method of immunohistochemistry was described elsewhere (Naito et al. 1998). Briefly, a biotin-streptavidin-peroxidase method (Nichirei, Tokyo) was applied after autoclave heating (120 °C, 5 minutes). The primary antibody for CD8 was clone C8/144B (DAKO, Glostrup, Denmark) diluted at 1:50. The chromogen was 3, 3'-diaminobenzidine tetrahydrochloride (Dojin, Kumamoto).

CD8⁺ T cells were classified into a) those infiltrating within cancer cell nests, b) those distributing along the invasive margin of cancer and c) those infiltrating in cancer stroma. For CD8⁺ T cells within cancer cell nests, we counted the number of immunoreactive cells at a microscopic field of $\times 200$ (0.933 mm²). Three areas with most abundant distribution were selected and the average numbers of CD8⁺ T cells were calculated.

Statistical analyses were performed with Kruskal-Wallis rank sum test and Mann-Whitney U-test. The survival rates were estimated by Kaplan-Meier method (Stata Co., College Station, TX, USA).

RESULTS

CD8⁺ T cells within cancer cell nests and those in the stroma were found in

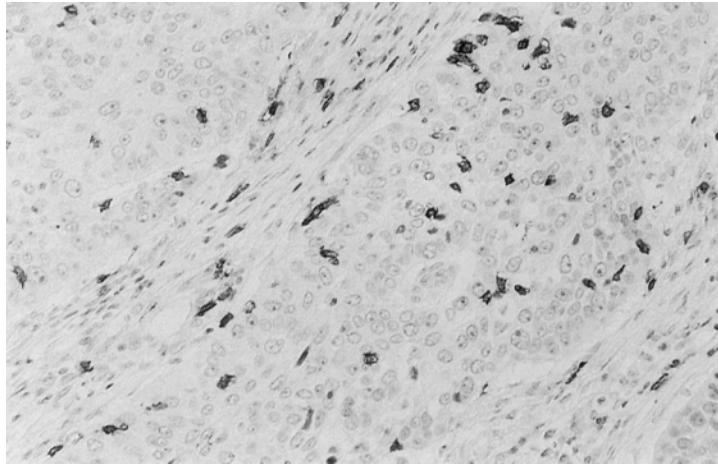


Fig. 1. Immunohistochemistry for CD8⁺ T cells in a case of squamous cell carcinoma, poorly differentiated type. CD8⁺ T cell infiltration is observed both within cancer cell nests and in the stroma. Hematoxylin counterstaining, $\times 200$.

all histological subtypes of NSCLC and in all degrees of differentiation with a significant variation (Fig. 1). A statistically significant difference was observed in the number of CD8⁺ T cells within cancer cell nests among three histological types of NSCLC: higher in squamous cell carcinoma or large cell carcinoma than in adenocarcinoma (Fig. 2A; $p < 0.0001$). Similar association was observed in the number of CD8⁺ T cells along the invasive margin ($p = 0.001$) and reversed association was demonstrated in CD8⁺ T cells in the stroma ($p < 0.05$) (data not shown). To check the relationship between the number of CD8⁺ T cells and the cancer cell differentiation, we re-classified all cases into well (27 cases), moderately (42 cases) and poorly (59 cases) differentiated types. Adenocarcinoma and squamous cell carcinoma were classified according to their differentiation and all cases of large cell carcinoma were re-classified into poorly differentiated type. As shown in Fig. 2B, the number of CD8⁺ T cells within cancer cell nests were highest in poorly differentiated type (including large cell carcinoma and poorly differentiated type squamous cell carcinoma and adenocarcinoma) and lowest in well differentiated type ($p < 0.05$).

The similar results were obtained when cases of large cell carcinoma were excluded in this analysis (data not shown). In contrast, CD8⁺ T cells along the invasive margin or those in the stroma were not correlated with the differentiation of cancer cells (data not shown). Kaplan-Meier method revealed that CD8⁺ T cells in all localization in NSCLC had no significant impact on the survival of the patients (data not shown).

DISCUSSION

The present study showed that CD8⁺ T cells infiltrated within cancer cell nests, previously demonstrated to be an independent prognostic factor in colorectal cancer, had no impacts on patients' survival in NSCLC, nor CD8⁺ T cells in

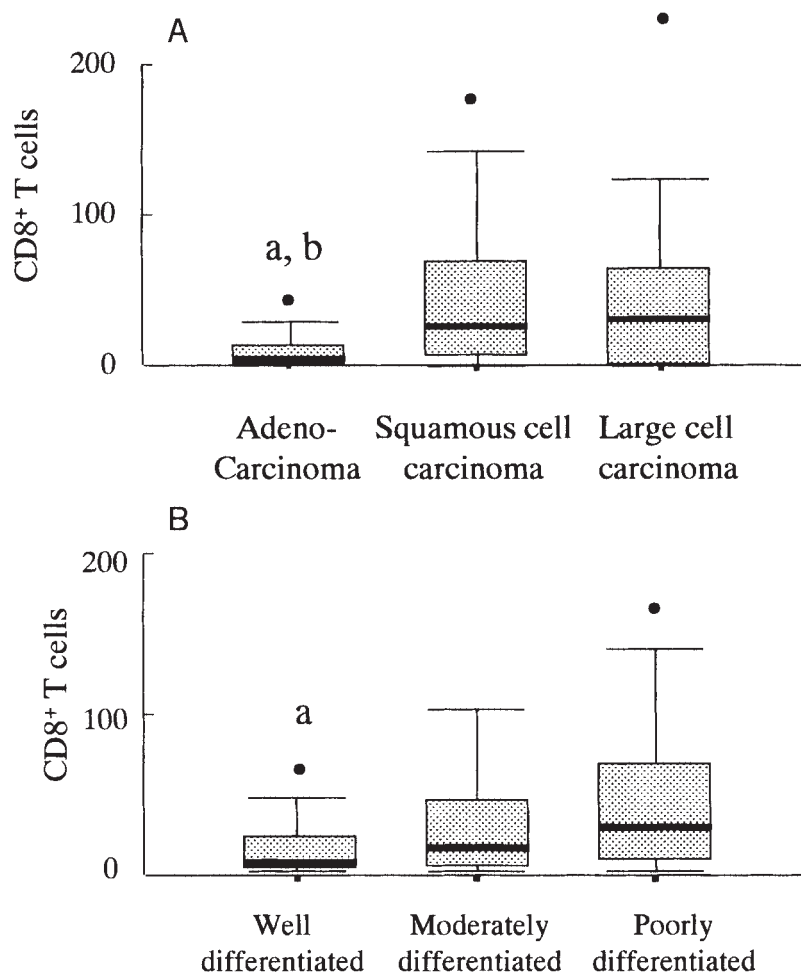


Fig. 2 Box-whisker plots of the number of CD8⁺ T cells within cancer cell nests in NSCLC by histological subtype (A) and by the degree of differentiation (B). The vertical axis indicates the number of CD8⁺ T cells within cancer cell nests. The thick bar within box represents the median value. The box indicates 75 and 25 percentiles. The upper and lower bars represent 90 and 10 percentiles, respectively.

A: a, $p < 0.0001$ vs. squamous cell carcinoma.

b, $p < 0.01$ vs. large cell carcinoma.

B: a, $p < 0.01$ vs. poorly differentiated carcinoma.

other localization. However, we found for the first time that the degree of infiltration of CD8⁺ T cells within cancer cell nests was dependent on the histologic subtypes and the dedifferentiation of cancer cells in NSCLC: larger in undifferentiated type than in differentiated type.

This close association of CD8⁺ T cells and dedifferentiation of cancer in NSCLC is consistent with our recent observation in other cancers. In colorectal cancer, poorly differentiated adenocarcinoma had more abundant CD8⁺ T cells within cancer cell nests than usual well or moderately differentiated adenocarcinoma (Naito et al. 1999). In renal cell carcinoma, cases with the poorer differentiation of cancer cells were infiltrated with larger number of CD8⁺ T cells in cancer tissue (Nakano et al. 1999). Based on these observation, we speculate that infiltration of CD8⁺ T cells into cancer cell nests may be related to the

dedifferentiation of cancer cells: that is, loss of normal histological and cytological characteristics and probable acquisition of cancer-associated antigens, such as MAGE and other cancer-testis antigens (Weynants et al. 1994). These findings should be taken into consideration for future study on tumor immunity.

In contrast to previous study (Naito et al. 1998), the present study showed that the number of CD8⁺ T cells have no impacts on the survival of patients with NSCLC. This discrepancy may be attributed to the difference in the histological characteristics between the two; most of colorectal cancer is monotonous in histologic type (well differentiated type adenocarcinoma), while NSCLC is composed of various histological subtypes and various degrees of differentiation. This histological heterogeneity of NSCLC itself can affect the prognosis of NSCLC (Gail et al. 1984) and could make the analysis of patients' survival in NSCLC more complicated.

Besides histological characteristics, there are additional factors that can influence the tumor immunity against NSCLC. Tumor bearing patients are under immunosuppressive state. Cell lines derived from human NSCLC produce type 2 cytokines both in situ and in vitro (Huang et al. 1995). The function of TILs in lung cancer can be impaired by unavailability of IL-2 and/or by lung cancer cell-derived factors (Yoshino et al. 1992). Such an immunosuppressive factor is detected in a squamous cell carcinoma cell line of the lung (Yoshino et al. 1993). In addition, increased expression of Fas ligand was reported in human lung cancer cell lines (Niehans et al. 1997), which may induce local deletion of tumor-reactive T cell clones, allowing an escape from anticancer immunity. In addition to TILs, macrophages are important, since the cytostatic activity of tumor-associated macrophages is correlated with favorable prognosis in lung cancer (Takeo et al. 1986).

In conclusion, the present study confirmed for the first time that the degree of infiltration of CD8⁺ T cells in NSCLC depends on the dedifferentiation of cancer cells in NSCLC. The net effects of anti-tumor immunity in lung cancer should be analyzed comprehensively considering the aggressiveness of cancer cells, immunosuppressive factors by cancer cells and other host reactions to cancer cells.

References

- 1) Chen, F.F., Yan, J.J., Lai, W.W., Jin, Y.T. & Su, I.J. (1998) Epstein-Barr Virus-Associated nonsmall cell lung carcinoma; Undifferentiated Lymphoepithelioma-like carcinoma as a distinct entity with better prognosis. *Cancer*, **82**, 2334-2342.
- 2) Gail, M.H., Eagan, R.T., Feld, R., Ginsberg, R., Goodell, B., Hill, L., Holmes, E.C., Lukeman, J.M., Mountain, C.F., Oldham, R.K., Pearson, F.G., Wright, P.W., Lake, W.H., Jr. & The Lung Cancer Study Group (1984) Prognostic factors in patients with resected Stage I non-small cell lung cancer: A report from the Lung Cancer Study Group. *Cancer*, **54**, 1802-1813.
- 3) House, A.K. & Watt, A.G. (1979) Survival and the immune response in patients with carcinoma of the colorectum. *Gut*, **20**, 868-874.
- 4) Huang, M., Wang, J., Lee, P., Sharma, S., Mao, J.T., Meissner, H., Uyemura, K.,

- Modlin, R., Wollman, J. & Dubinett, S.M. (1995) Human non-small cell lung cancer cells express a type 2 cytokine pattern. *Cancer Res.*, **55**, 3847-3853.
- 5) Kuo, S.-H., Chang, D.-B., Lee, Y.-C., Lee, Y.-T. & Luh, K.-T. (1998) Tumor-infiltrating lymphocytes in non-small cell lung cancer are activated T lymphocytes. *Respirology*, **3**, 55-59.
- 6) Naito, Y., Saito, K., Shiiba, K., Ohuchi, A., Saigenji, K., Nagura, H. & Ohtani, H. (1998) CD8⁺ T cells infiltrated within cancer cell nests as a prognostic factor in human colorectal cancer. *Cancer Res.*, **58**, 3491-3494.
- 7) Naito, Y., Ohtani, H., Wakatsuki, S., Horii, A., Kato, Y. & Nagura, H. (1999) Close association between immune reactions and microsatellite instability in poorly differentiated adenocarcinoma of colorectum. *Jpn. J. Cancer Res.*, Suppl., **90**, 641. (Abstract)
- 8) Nakano, O., Satou, M., Suzuki, K., Orikasa, S., Naito, Y., Ohtani, H. & Nagura, H. (1999) Clinicopathologic significance of tumor-infiltrating CD8⁺ lymphocytes in human renal cell carcinoma. *Jpn. J. Cancer Res.*, Suppl., **90**, 640. (Abstract)
- 9) Niehans, G.A., Brunner, T., Frizelle, S.P., Liston, J.C., Salerno, C.T., Knapp, D.J., Green, D.R. & Kratzke, R.A. (1997) Human lung carcinomas express Fas ligand. *Cancer Res.*, **57**, 1007-1012.
- 10) Rosenberg, S.A. (1996) The immunotherapy of solid cancers based on cloning the genes encoding tumor-rejection antigens. *Annu. Rev. Med.*, **47**, 481-491.
- 11) Saiki, Y., Ohtani, H., Naito, Y., Miyazawa, M. & Nagura, H. (1996) Immunophenotypic characterization of Epstein-Barr virus-associated gastric carcinoma: Massive infiltration by proliferating CD8⁺ T-lymphocytes. *Lab. Invest.*, **75**, 67-76.
- 12) Takeo, S., Yasumoto, K., Nagashima, A., Nakahashi, H., Sugimachi, K. & Nomoto, K. (1986) Role of tumor associated macrophages in lung cancer. *Cancer Res.*, **46**, 3179-3182.
- 13) Travis, W.D., Colby, T.V., Corrin, B., Shimosato, Y. & Brambilla, E. (1999) *Histological Typing of Lung and Pleural Tumors (WHO)*. 3rd ed., Springer, Berlin.
- 14) Weynants, P., Lethe, B., Brasseur, F., Marchand, M. & Boon, T. (1994) Expression of mage genes by non-small-cell-lung carcinomas. *Int. J. Cancer*, **56**, 826-829.
- 15) Yoshino, I., Yano, T., Murata, M., Ishida, T., Sugimachi, K., Kimura, G. & Nomoto, K. (1992) Tumor-reactive T cells accumulate in lung cancer tissues but fail to respond due to tumor cell-derived factor. *Cancer Res.*, **52**, 775-781.
- 16) Yoshino, I., Yano, T., Miyamoto, M., Yamada, K., Kajii, Y., Onodera, K., Ishida, T., Sugimachi, K., Kimura, G. & Nomoto, K. (1993) Characterization of lung squamous cell carcinoma-derived T cell suppressive factor. *Cancer*, **72**, 2347-2357.
-