J Toxicol Pathol 2001; ***14****: 51–55*

Case Report

Polycystic Disease of the Kidney and Liver in Crj:CD(SD) Rats

Kiyonori Kai[1], Norihiro Sato[1], Atsushi Watanabe[1], Kazumi Shiraiwa[1], Shinichi Ogawa[1], and Youshiro Kobayashi[1]

[1]Laboratory for toxicological research, institute for life science research, Asahi chemical industry Co., Ltd., Shizuoka, 410–2321, Japan

Abstract: Polycystic lesions of kidney and liver were found in Crj:CD(SD) rats of 9 males and 6 females ranging in age from 5 to 57 weeks and were histopathologically or immunohistochemically investigated. Renal cysts were observed in the outer medulla at the beginning and confirmed to be dilatations of the collecting ducts by *Dolichos biflorus* agglutinin lectin histochemistry. At an advanced stage, the cysts expanded toward the cortex owing to dilatation of the collecting ducts and distal tubules, inflammatory cell infiltration, and fibrosis surrounding the cysts were observed additionally. The TUNEL assay revealed apoptotic cell death in the tubular epithelium of the cysts. Electron microscopy represented slightly thickened and laminated basement membranes of the cysts.The liver lesion at the beginning revealed slight dilatation of bile ducts and lymphatic ducts in Glisson's sheath. At the advanced stage, dilatation of bile ducts spread over the liver, proliferation of bile ducts, desquamation of the biliary epithelium, and fibrosis surroundings the bile ducts were observed in addition to the cystic lesions. The histological features of the cystic lesions were similar to those of human autosomal recessive polycystic kidney disease (PKD). None of the rat PKD models presented concurrently the biliary cysts. Therefore, these rats may be a potential model for human PKD and be useful for studying the correlation of the pathogenesis between the renal cysts and the biliary cyst. (J Toxicol Pathol 2001; **14**: 51–55)

Key words: polycystic disease, kidney, liver, rat, Crj:CD(SD)

Laboratory animal models of human polycystic kidney disease (PKD) have been described in mice, rats, and other animal species[1, 2]. Two types of PKD, autosomal dominant polycystic kidney disease (ADPKD) and autosomal recessive polycystic kidney disease (ARPKD), are known in humans[3]. Human ADPKD affects adults, and the renal cysts can be found at any locus of the nephron[3]. Cysts in other organs, including the liver, spleen, and pancreas have been described, but are not a consistent feature of the disease[3]. In contrast, human ARPKD affects children or juveniles, the renal cysts were predominantly localized in the collecting ducts, and biliary cysts are always seen in addition to renal cysts[3]. Though rat PKD models (e.g., Han:SPRD rats, *chin* rats) have been previously reported, biliary cysts were not always observed in these rat models[2]. Recently, a novel PKD model of rat was established in Crj:CD(SD) rats which have both renal and biliary cysts by continuous sibling mating[4]. We found PKD of the rats in drug-safety evaluation studies and describe the histological features of the rats in comparison with other rat PKD model, human ARPKD, and ADPKD.

Sprague-Dawley rats were supplied by Charles River Japan Inc from 1992 till 1995. The animals were kept in a stainless steel cage at 22 ± 3°C room temperature, with 55 ± 15% relative humidity, 12:12 hours light:dark cycle, and an air exchange rate of 15 times per hour. All rats were given a standard CRF-1 diet (Oriental Yeast Co. Ltd., Tokyo, Japan) and chlorinated tap water *ad libitum*. Affected animals were detected in 11 animal lots (A-K) of drug-safety evaluation studies. All the examined animals besides dead ends, were subjected to bleeding death from the abdominal aorta under ethyl ether anesthesia. A complete post-mortem examination was performed on each animal. The kidney, liver, lung, heart, spleen, thymus, mesenteric lymph node, pancreas, salivary glands, adrenals, thyroid, parathyroid, brain, pituitary, spinal cord, bone marrow, lumber vertebrae, testis, epidermis, prostate, seminal vesicle, urinary bladder, ovary, and uterus of these animals were fixed in 10% phosphate-buffered formalin solution, and embedded in paraffin. Tissue sections were routinely stained with hematoxylin and eosin (H-E), and the kidneys were also stained with periodic acid-Schiff (PAS) solution. The

Received: 22 September 2000, Accepted: 18 December 2000
Mailing address: Kiyonori Kai, Drug Safety Research Laboratory, Daiichi pharmaceutical Co., Ltd., Tokyo R&D center 16–13, Kita-kasai 1-chome, Edogawa-ku, Tokyo 134–8630 Japan
TEL: 81-3-5696-8155 FAX: 81-3-5696-8335
E-mail address: kaikitrx@daiichipharm.co.jp

sections of liver and kidney were moreover immunostained with an avidin-biotin-complex immunoperoxidase method (Elite-ABC, Vector Laboratories, CA, USA) using anti-PCNA antibody (Clone PC10, DAKO A/S) or anti *c-fos* antibody (PC05, Oncogene Research Products), and stained with the TUNEL assay using an Apop Tag *in situ* Apoptosis Detection Kit (Oncor Appligene, Basel, Switzerland). In order to confirm the origin of the renal cysts, the kidneys of some animals were stained with a peroxidase-labeled solution of *Dolichos biflorus* agglutinin (DBA) or *Lens culinaris* agglutinin (LCA) for lectin histochemistry (Seikagaku Corporation, Japan) by the method of Faraggiana *et al.*[5]. By lectin histochemistry, the collecting duct and proximal tubule were strongly stained with DBA but only the proximal tubule was strongly stained with LCA[5]. The kidneys of some animals were fixed in 2.5% glutaraldehyde solution, post-fixed in 1% osmium tetroxide solution, and then embedded in epoxy resin. Ultrathin sections were stained with uranyl acetate and lead citrate and examined by a transmission electron microscope JEM-100S (JOEL LTD., Tokyo, Japan).

We detected 9 males and 6 females with polycystic kidney and liver disease in Crj:CD(SD) rats ranging in age from 5 to 57 weeks (Fig. 1). Abnormal clinical signs during the test periods or the cystic lesions in addition to the kidney and liver were not observed. The incidence of the disease in each animal lot was 3.4–0.9%. The histological grade of kidneys was more severe than the livers except for 2 animals of lot G (Fig. 1) .

Necropsy revealed that the kidneys were bilaterally enlarged. The renal surface was smooth, and numerous cysts of various size were observed mainly in the outer medulla of the cut surface. The cysts were filled with a watery, faintly yellow fluid. The livers were enlarged and pale. In other organs, macroscopic abnormalities were not detected.

Histologically, various sized renal cysts appeared in the outer medulla at the beginning. In this stage (initial stage), the tubules were dilated, and the epithelia were strongly

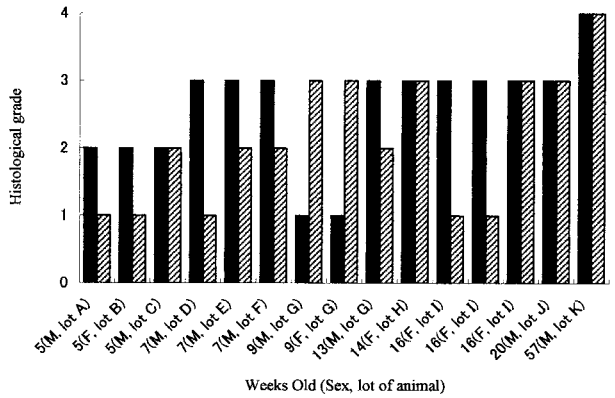

Fig. 1. The grades of renal and biliary lesions, age and sex in 9 male and 6 female Crj:CD(SD) rats.

M: Male, F: Female. Letters in parentheses indicate the sex and lot of each animal.

The grades of renal lesions: ■

Grade 1 (very slight change): The cysts occupy less than 30% of the outer medulla.

Grade 2 (slight change): The cysts occupy more than 30%, and less than 80% of the outer medulla.

Grade 3 (moderate change): The cysts occupy more than 80% of the outer medulla, and cortical cysts are frequently observed.

Grade 4 (severe change): The cysts occupy more than 80% of the outer medulla and cortex. Slight dilatation of the collecting duct in the inner medulla is also observed.

The grades of biliary lesions: ▨

Grade 1 (very slight change): Slight dilatation of the bile ducts and lymphatic ducts is observed.

Grade 2 (slight change): Mild dilatation and proliferation of bile ducts are observed.

Grade 3 (moderate change): Slight fibrosis around the bile ducts is observed in addition to Grade 2 (slight change).

Grade 4 (severe change): Fibrosis around the bile ducts is more severe than Grade 3 (moderate change), and the biliary epithelium also shows degenerative changes and desquamation into the lumen.

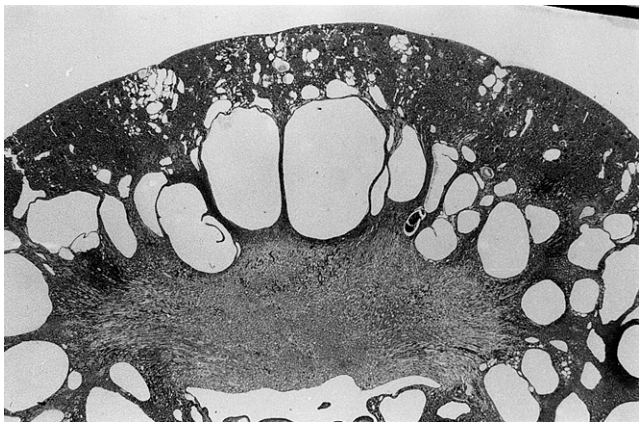

Fig. 2. Renal cysts at an advanced stage. Numerous various-sized cysts occupy the outer medulla and small cysts are also observed in the cortex. Cyst progression is less aggressive in the inner medulla. H-E. × 7.

Fig. 3. Higher magnification of renal cysts. Cysts are lined by rather shrunken cuboidal epithelia with chromatin condensation, compact cytoplasm, and apoptotic debris (arrows). H-E.× 280.

stained by DBA lectin but not by LCA lectin. The cysts at the initial stage therefore originated from the collecting ducts. When the kidney was moderately or severely affected, the cysts of the outer medulla expanded to the cortex, and smaller cysts were also observed in this region (Fig. 2). In the advanced stage, cortical cysts were stained by lectin histochemistry in two ways. One was strong staining by DBA lectin, but not by LCA lectin. The other did not show positive staining with either DBA or LCA lectin. Therefore, cysts in the advanced stage originated from the collecting ducts and distal tubules. In the cortex, there were degeneration and regeneration of tubular epithelium. Fibrosis and inflammatory cells infiltration surrounding the cysts were also observed, and moreover thickening of the basement membrane of cystic tubules was observed with PAS staining. In contrast to the cortex, the progression of cystic changes was less aggressive in the inner medulla. In all stages, apoptotic cell death of the cystic epithelium was observed with H-E staining (Fig. 3) and in the TUNEL assay (Fig. 4), but PCNA-positive epithelium was not frequently seen in renal cysts. The tubular epithelium was stained positively with TUNEL, and the surrounding interstitial cells occasionally showed immunohistochemical positivity for c-*fos*. The electron microscopy represented slightly thickened and laminated basement membrane of the collecting ducts, and irregular basolateral plasma membrane infoldings of principal cells (Fig. 5). The principal cells of the collecting ducts sometimes appeared to be shrunken and had numerous electron-dense bodies (Fig. 5).

The minimally affected liver at the initial stages showed dilatation of bile ducts and lymphatic ducts in Glisson's sheath. When the livers were moderately to severely affected at the advanced stage, proliferation of bile ducts and fibrosis additionally appeared with degeneration and desquamation of biliary epithelia into the lumen followed by fibrous replacement (Figs. 6, 7). Dilatation of lymphatic

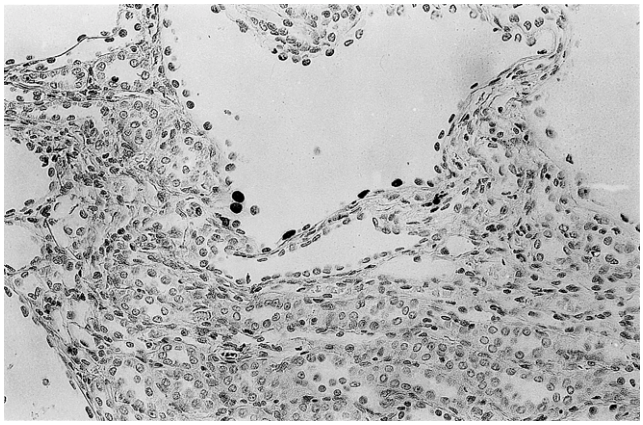

Fig. 4. TUNEL assay of renal cysts. Positive lining-epithelia were frequently seen in renal cysts. TUNEL assay × 90.

Fig. 5. Electron microscopy of renal cysts. The tubular basement membrane of the cysts is slightly thickened and laminated. Regular basolateral plasma membrane of principal cells are irregularly infolded, and the principal cells of the collecting ducts sometimes appear to be shrunken and to have numerous electron-dense bodies. Bar 2 μm .

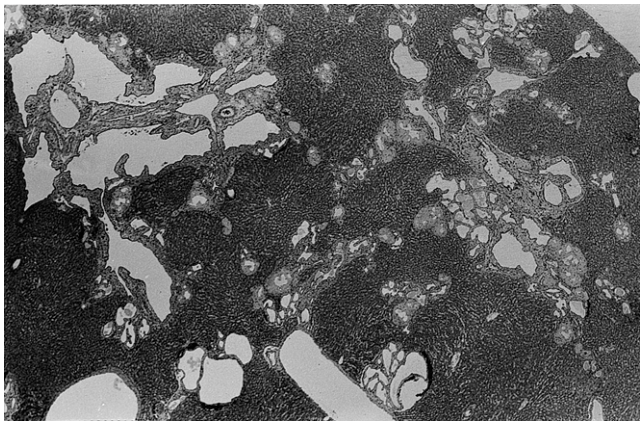

Fig. 6. Biliary cysts at an advanced stage. Dilatation of bile ducts is obvious in Glisson's sheath, and dilated and proliferated bile ducts disperse over the whole area. H-E. × 6.

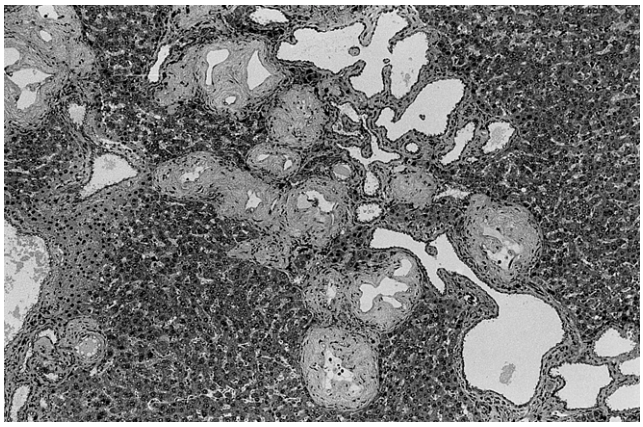

Fig. 7. Higher magnification of biliary cysts at an advanced stage. The biliary epithelium often shows degenerative changes and desquamation into the lumen, followed by replacement with abundant collagen. H-E. × 37.

ducts was not remarkable according to progression of the lesions. The proliferated bile duct epithelia frequently showed immunohistochemical positivity for PCNA, but were not positively stained with TUNEL assay or c-*fos* immunohistochemistry.

We evaluated polycystic disease of the kidneys and liver in Crj:CD(SD) rats ranging in age from 5 to 57 weeks. Since the cystic lesions of the kidneys and the livers were sporadically observed among the treated or control groups, we assumed that the lesions were not related to the administration of the test substances. Continuous sibling mating of Crj:CD(SD) rats since 1996 had led to establishment of a novel PKD model, and mating experiments revealed that PKD is controlled by an autosomal recessive gene[4]. We found PKD in Crj:CD(SD) rats supplied from 1992 till 1995 and assumed that the animal origin was the same as the reported PKD rat. The histological features of the kidneys and livers were extremely similar to the previous report[4], and moreover the low incidence of PKD in this study suggested that the lesions were due to autosomal recessive disease. Although we did not study the disease in respect of genetic element, we assume that the disease in this study was the same as the novel PKD model concerning tentative "rpc" gene[4]. The cystic lesion of kidney and liver generally seemed to become severe with animal age and the renal lesion was more severe than the liver. But there were differences of animal lot, thus distinct correlation in morphogenesis between the kidneys and livers was not recognized. The previous report suggested that the dysfunction of liver appeared prior to the onset of the kidney disease in respect to blood chemistry[4], but no distinct correlation between morphology and physiology has been recognized. Further studies will be required to focus on the interaction between the liver and kidney disease.

Models of human PKD such as *chin* and Han:SPRD rats have been previously described[2]. The *chin* rat is accepted as a model for human ARPKD[2]. The renal cysts derived from the collecting ducts progress very rapidly, and the rats die between the age of 6 and 11 months[2,6,7]. In addition to cystic lesions, *chin* rats suffer from skeletal abnormalities[7,8]. In contrast to *chin* rats, Han:SPRD rats, which have slowly progressive PKD[2], are used as a model of human ADPKD. The renal cysts of human ADPKD as well as Han: SPRD rats are characterized by the development of numerous cysts arising from all enthrone segments[2,9,10]. As for liver lesions in human PKD, all cases of human ARPKD develop varying degrees of periportal fibrosis, bile ductual hyperplasia, and biliary dysgenesis[3,11]. Considering the rat PKD models, biliary cysts were not always observed in the *chin* and Han:SPRD rats[2,7,10,12], but renal and biliary cysts always occurred concurrently in Crj:CD(SD) rats. The PKD of Crj:CD(SD) rats were due to dilatation of collecting ducts and always had the biliary cysts, thus the histological features of the kidneys and livers mostly resembled those of human ARPKD.

The pathogenesis of renal cysts in human and animal PKD is considered to involve three major factors which are abnormalities of the cell cycle, tubular basement membrane compliance, and transepithelial fluid transport[13-16]. Deregulation of apoptosis during development is involved in the pathogenesis of PKD, and numerous genetic regulators such as *bcl*-2, c-*fos*, *bax*, and c-*myc* regulate renal apoptosis[16]. Although c-*fos* expression does not always have a causal relationship to apoptosis, it is suggested that the c-*fos* product is a required component of the gene regulation pathway leading to apoptosis in some circumstances[17]. In the present study, apoptosis and the expression of c-*fos*, but not PCNA, were histologically observed in renal cysts in Crj:CD(SD) rats. This evidence could indicate an abnormal cell cycle of the renal epithelium leading to apoptosis. The basement membrane of the renal cysts was thickened, and moreover the basolateral plasma membrane infoldings were rather irregular in the Crj:CD(SD) rats. The principal cells contain Na,K-ATPase with which these cells reabsorb sodium and secrete potassium[18]. Mispolarization of Na,K-ATPase to the apical plasma membranes of the cystic epithelium was thought to cause aberrant ion and fluid secretion into the lumen[13,14,19]. Although the exact pathogenesis of renal cysts in Crj:CD(SD) rats remains unknown, several histological features of renal cysts were very similar to those of human PKD. Comparing with the detailed studies done on kidney lesions, much less attention has been paid for characterizing liver lesions in PKD[11,20-22]. In this study, obvious correlations of histological grades between renal and biliary cysts have not been observed. In contrast to the special staining of kidneys using PCNA immunohistochemistry and the TUNEL assay, biliary epithelia were frequently stained positive for PCNA, but negative for TUNEL. These differences may provide useful information for further research on multiorgan cystgenesis.

Taking these histological features into account, the renal and biliary cysts were similar to those in human ARPKD, and indicators for solving the pathogenesis of biliary cysts may be involved in the polycystic disease of Crj:CD(SD) rats. Therefore, these animals may have potentials as an animal model of human PKD and be useful for studying the pathogenesis of the cystic lesions and correlation between renal and biliary cysts.

References

1. McDonald RA, and Avner ED. Mouse models of polycystic kidney disease. In: Polycystic Kidney Disease, Watson ML and Torres VE(eds), Oxford University Press, 63–87, 1996.
2. Cowly BD Jr, and Gattone VH II. In vivo models of PKD in non-murine species. In: Polycystic Kidney Disease, Watson ML, and Torres VE(eds), Oxford University Press, 88–110, 1996.
3. Cotran RS, Kumar V, and Robbins SL. The kidney. In: Robbins Pathologic Basis of Diseases, 5th ed., Schoen (ed), Philadelphia: WB Saunders, 934–938, 1994.
4. Katsuyama M, Masuyama T, Komura I, Hibino T, and Takahashi H. Characterization of a novel polycystic kidney rat model with accompanying polycystic liver. Exp Anim 2000 ; **49**: 51–55.

5. Faraggiana T, Malchiodi F, and Prado A. Lectin-peroxidase conjugate reactivity in normal human kidney. J Histochem Cytochem 1982; **30**: 451–458.
6. Inage Z, Kikkawa Y, Minato M, Owada M, Kitagawa T, Ohno K, Kondo K, Ueda Y, and Iidaka K. Autosomal recessive polycystic kidney in rats. Nephron 1991; **59**: 637–640.
7. Ohno K, and Kondo K. A mutant rat with congenital skeletal abnormalities and polycystic kidneys. Exp Anim 1989; **38**: 139–146.
8. Minato M, Inage Z, Ohwada M, and Ohno K. A study of an autosomal recessive polycystic kidney disease with facial and skeletal abnormalities in rat. Nippon Jinzo Gakkai Shi 1990; **11**: 1211–1220.
9. Kaspareit-Rittinghausen J, Deerberg F, and Wcislo A. Hereditary polycystic kidney disease. Adult polycystic kidney disease associated with renal hypertension, renal osteodystrophy, and uremic enteritis in SPRD rats. Am J Pathol 1991; **139**: 693–696.
10. Cowley BD Jr, Gudapaty S, Kraybill AL, Barash BD, Harding MA, Calvet JP, and Gattone VH. 2d, Autosomal-dominant polycystic kidney disease in the rat. Kidney Int 1993; **43**: 522–534.
11. D'Agata ID, Jonas MM, Perez-Atayde AR, and Guay-Woodford LM. Combined cystic disease of liver and kidney. Semin Liver Dis 1994; **14**: 215–228.
12. Kranzlin B, Schieren G, and Gretz N. Azotenal and extrarenal manifestation in old female Han: SPRD (*cy*/+) rats. Kidney Int 1997; **51**: 1160–1169.
13. Carone FA, Bacallao R, and Kanwar YS. Biology of polycystic kidney disease. Lab Invest 1994; **70**: 437–448.
14. Gabow PA. Polycystic kidney disease: Clues to pathogenesis. Kidney Int 1991; **40**: 989–996.
15. Cowley BD Jr, Chadwick LJ, Grantham JJ, and Calvet JP. Elevated proto-oncogene expression in polycystic kidneys of the C57BL/6J(cpk) mouse. J Am Soc Nephrol 1991; **1**: 1048–1053.
16. Davis MA, and Ryan DH. Apoptosis in the kidney. Toxicol Pathol 1998; **26**: 810–825.
17. Smeyne RJ, Vendrell M, Hayward M, Baker SJ, Maio GG, Schilling K, Robertson LM, Curran T, and Morgan JI. Continuous c-*fos* expression precedes programmed cell death *in vivo*. Nature 1993; **363**: 166–169.
18. Verlander JW. Normal ultrastructure of the kidney and lower urinary tract. Toxicol Pathol 1998; **26**: 1–17.
19. Wilson PD, Devuyst O, Li X, Gatti L, Falkenstein D, Robinson S, Fambrough D, and Burrow CR. Apical plasma membrane mispolarization of NaK-ATPase in polycystic kidney disease epithelia is associated with aberrant expression of the $\beta 2$ isoform. Am J Pathol 2000; **156**: 253–268.
20. Torres VE. Polycystic liver disease. In: Polycystic Kidney Disease, Watson ML and Torres VE(eds), Oxford University Press, 501–529, 1996.
21. Guay-Woodford LM, Green WJ, Lindsey JR, and Beier DR. Germline and somatic loss of function of the mouse cpk gene causes biliary ductal pathology that is genetically modulated. Hum Mol Genet 2000; **9**: 769–778.
22. Yoder BK, Richards WG, Sommardahl C, Sweeney WE, Michaud EJ, Wilkinson JE, Avner ED, and Woychik RP. Differential rescue of the renal and hepatic disease in an autosomal recessive polycystic kidney disease mouse mutant. A new model to study the liver lesion. Am J Pathol 1997; **150**: 2231–2241.